

# A review of conservative and therapeutic management in the treatment of pterygium



Oliwia Cwalina<sup>1</sup>, Zuzanna Mrugała<sup>1</sup>, Monika Molga<sup>1</sup>,  
Katarzyna Chamera-Cyrek<sup>1</sup>, Liliana Dyląg<sup>1</sup>, Oliwia Sikora<sup>1</sup>,  
Bartłomiej Żaczek<sup>1</sup>, Jan Maciej Baran<sup>1</sup>, Dawid Rowiński<sup>1</sup>,  
Clara Kuźmiński<sup>1</sup>, Aneta Podczerwińska<sup>1</sup>, Ilona Pawlicka<sup>1,2</sup>,  
Anna Maria Roszkowska<sup>1,3</sup>, Maciej Kozak<sup>1,2</sup>

<sup>1</sup> Faculty of Medicine and Health Sciences, Andrzej Frycz Modrzewski Krakow University  
Dean: prof. Janusz Ligeza, PhD

<sup>2</sup> Clinical Department of Ophthalmology, Provincial Ophthalmology Hospital, Krakow  
Head: Maciej Kozak, MD, PhD

<sup>3</sup> Department of Biomedical and Dental Sciences and Morphofunctional Imaging, University of Messina, Italy  
Head: prof. Sergio Baldari

## HIGHLIGHTS

A significant problem in this disease is the significant frequency of recurrence after surgery, so it is very important to choose a treatment that will be effective and well tolerated by the patient.

## ABSTRACT

Pterygium is a degenerative change consisting of an abnormal overgrowth of the degenerative conjunctiva, which grows on the cornea and causes discomfort and progressive vision problems. The initial symptom of pterygium may also be local, chronic and recurrent conjunctivitis. Some of the most common causes of this disease are exposure to UV radiation, the irritating effect of wind and dust, as well as local insufficiency of limbal stem cells. In the following article, we will discuss the available treatment methods and their impact on the prevention of pterygium recurrence, as well as focus on the pharmacotherapy used to support recovery after surgery.

**Key words:** pterygium, treatment of pterygium, corneal degeneration

## INTRODUCTION

Pterygium is a common disorder of the anterior surface of the eye, characterized by fibrovascular degeneration of the conjunctiva. This change is a convex triangular-shaped opacity accompanied by hyperplasia of goblet cells. The tissue accumulates on the cornea usually from the nasal side of the lid fissure from the conjunctival edge towards the cornea. This occurs because the prominence of the nose reduces the light force transmitted to the temporal conjunctival edge. Also, the natural flow of tears, which happens from the temporal to the nasal side, directs dust and particulates towards the conjunctival sac, irritating the nasal conjunctiva, which is an additional predisposing mechanism for pterygium [1]. As the lesion enlarges, characteristic radial vascularity appears, and the head of the pterygium, extending onto the cornea, damages Bowman's membrane and grows into the substantia propria. Consequently, when the head of the pterygium begins to encroach on the central part of the cornea, visual impairment occurs, which is a medical indication for its surgical removal. Depending on the size of the lesion, patients may also develop astigmatism, which is the main cause of decreased visual acuity.

## EPIDEMIOLOGY

A higher incidence of pterygium has been observed in men, mainly between the ages of 20 and 30, as well as in individuals working outdoors. The primary risk factor for the development of pterygium is UV radiation, and consequently, the influence of geographical latitude – the closer to the equator, the greater the exposure. UV rays cause dysfunction of corneal limbal stem cells through mutation in the P53 tumor suppressor gene and activation of tissue growth factors, which further lead to angiogenesis and cell proliferation [2]. Recent studies have shown that an important factor in the pathogenesis of pterygium may also be human papillomavirus (HPV) or herpes simplex virus (HSV), indicating that it is not only a degenerative change but can also arise due to unregulated cell proliferation [3]. The irritating effects of dust and wind cannot be ruled out as well, leading to localized chronic inflammation within the eye globe.

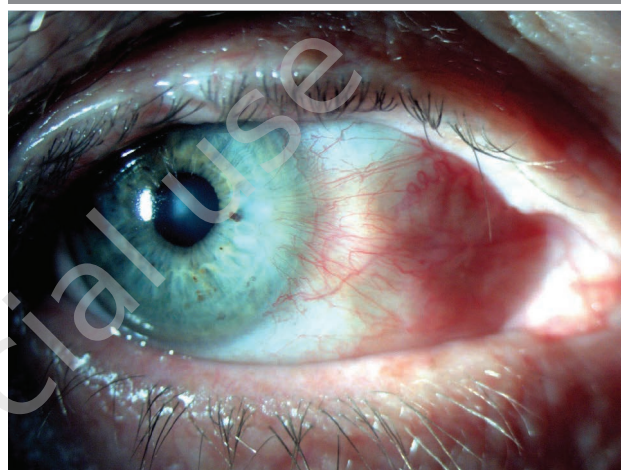## SYMPTOMS AND CLINICAL COURSE

Symptoms of pterygium occur when it begins to encroach on the cornea. Patients report feeling a foreign body sensation under the eyelids, photophobia and tearing. However, visual acuity deterioration associated with the development of astigmatism and pupil occlusion only appears in the advanced stage of pterygium. On examination, a triangular fibrovascular change in the lid fissure can be observed. Moreover, a large pterygium may hinder eye movements,

and corneal invasion results in varying degrees of opacity and often causes a cosmetic defect (fig. 1).

FIGURE 1

Pterygium growing from the nasal side of the eyeball towards the cornea.



## DIAGNOSIS

In the diagnosis of pterygium, a detailed patient history is crucial, including information about the medical history, onset of symptoms, development course, and presence of other eye diseases in the past, which will help determine the etiology and diagnose of pterygium [4]. Clinically, diagnosing pterygium requires a comprehensive ophthalmic examination including visual acuity assessment, anterior and posterior segment evaluation with biomicroscopy, as well as refractive error assessment. Valuable information can also be obtained from corneal topography and photographic documentation to monitor disease progression. Currently, efforts are underway to develop automated diagnostic systems based on artificial intelligence using photographic images of the anterior eye segment for pterygium diagnosis.

In recent studies, diagnoses made by artificial intelligence were compared with those made by medical professionals. The effectiveness of pterygium detection and assessment of its stage were analyzed. Researchers demonstrated significant agreement between diagnoses made by artificial intelligence and those made by medical examination in determining the presence or absence of the lesion. This represents an intriguing direction in the development of diagnostic medicine. However, it should be noted that the artificial intelligence diagnosis regarding the stage of the lesion was less sensitive compared to specialist diagnosis, which still has a limitation in the application of this method [5].

## DIFFERENTIATION

It is important to distinguish pterygium from pseudo-ptyerygium, which is a conjunctival fold resulting from scar changes occurring as a consequence of injuries or chemical burns. Importantly, it does not exhibit signs of growth. Histopathologically, it is very similar to pterygium, but unlike it, pseudo-ptyerygium causes the aforementioned destruction of Bowman's membrane and the increase of the superficial layer of the cornea. [6] In the case of an atypical appearance of the lesion, the risk of neoplastic changes should be ruled out.

## THERAPEUTIC APPROACH IN PTERYGIUM

In the therapeutic approach, several methods can be distinguished: conservative, pharmacological, and surgical treatment. Thin, atrophic pterygium that does not cause symptoms should be under constant observation. The uncertain pathogenesis of pterygium and its numerous risk factors described in the literature may contribute to an increased recurrence rate of this condition. Premature surgical interventions are not indicated in the case of recurrent pterygium, as they are much more difficult to treat due to the intensified inflammatory state of the conjunctiva and significantly more aggressive growth of fibrovascular tissue [4]. In the early stages of the disease, as long as the symptoms are not yet severe or in the case of eye irritation, artificial tear preparations can be used to relieve dryness and the sensation of a foreign body, or temporarily introduce anti-inflammatory drops to reduce inflammation [4]. If patients report additional symptoms such as redness, itching, and swelling of the eyes, vasoconstrictors containing antihistaminic substances can be applied. However, it should be noted that such treatment is mainly symptomatic and temporary. If the disease continues to progress, surgical intervention is the most appropriate choice.

## THE USE OF ADJUVANT THERAPY

Adjuvant therapy is applied as complementary treatment, following a previously performed surgical procedure, to achieve a better therapeutic effect and reduce the risk of local recurrence.

**Mitomycin C (MMC)** is a strong antimetabolite that inhibits RNA and DNA synthesis, reducing the number of mitoses [3]. It inhibits protein synthesis and cell proliferation. Despite its widespread use in surgery, caution must be exercised because it has been documented that high concentrations and prolonged exposure can cause scleral inflammation. MMC is indicated for treating recurrent pterygium and its highly aggressive forms. When used briefly and in low concentrations (0.02% on a sponge), it can reduce the risk of dangerous, potentially serious side effects such as pain, photophobia, cataracts, or even necrosis and perfora-

tion of the cornea or sclera [2]. Its impact on reducing the number of pterygium recurrences occurs through the inhibition of fibroblast proliferation in the subconjunctival area [3]. It can be used as eye drops. However, it is believed that administering MMC directly to the pterygium has a protective effect on the endothelium and corneal epithelium. At present, it has been established that high concentrations significantly reduce the frequency of disease recurrence.

**Cyclosporine A** is an immunosuppressive drug with anti-inflammatory properties. In the treatment of pterygium, it is usually used in the form of eye drops at a concentration of 0.05%, combined with autologous conjunctival transplantation. So far, no complications or side effects of this form of therapeutic intervention have been observed. However, its high efficacy has been demonstrated in reducing the frequency of disease recurrences and in faster recovery of patients treated in this way [3].

**5-fluorouracil** is a pyrimidine analogue that disrupts DNA synthesis and inhibits fibroblast proliferation. Adjuvant therapy with 5-fluorouracil has been shown to be associated with reduced rates of vascular and epithelial toxicity, as well as significantly lower therapy costs compared to the use of MMC [3].

**Loteprednol** is a corticosteroid suspension used to reduce inflammation and control healing processes after surgery. It is important to note that the preparation does not treat the cause of inflammation but only alleviates its symptoms due to its short-term action. Therefore, despite its effective action, there is still a high risk of pterygium recurrence [3].

**Bevacizumab** is a human recombinant monoclonal antibody against vascular endothelial growth factor (anti-VEGF), approved by the FDA (Food and Drug Administration) for the treatment of certain cancers. It has been decided to use it in the treatment of pterygium due to the higher expression of VEGF in this condition, in order to prevent the formation of new pathological vessels and reduce the frequency of recurrences [7].

## SURGICAL METHODS

Currently, the treatment of pterygium in most cases relies on techniques involving conjunctival, limbal, or amniotic membrane transplantation [2]. The main indications for surgical treatment include deterioration of vision, especially in cases of astigmatism, limited eye movement, chronic pain, persistent inflammation, and present cosmetic defect [4]. There are numerous surgical techniques available, each carrying the risk of pterygium recurrence, most commonly between the first and third month post-surgery.

### Simple excision of pterygium

It is believed that the technique of simple removal of pterygium with the exposure of the sclera is the simplest

surgical method, but unfortunately, it is associated with a high recurrence rate (38–88%) in the postoperative period [8]. This is because the residual fibrous tissue tends to proliferate and exacerbate inflammation within the remaining conjunctiva. It is also associated with the risk of severe complications such as scleral necrosis and infection, formation of purulent granulomas, or delayed corneal epithelialization. Over time, this procedure has undergone numerous modifications, resulting in new surgical techniques used by specialists aimed at reducing the frequency of pterygium recurrences. To improve the effectiveness of simple excision technique, adjunctive treatment with MMC, 5-fluorouracil, cyclosporine A, vascular endothelial growth factor inhibitors (anti-VEGF) is applied [9]. Both subconjunctival injections performed 24 h before surgery and intraoperative use of MMC have statistically shown a lower recurrence rate compared to patients who did not receive antimetabolites [8].

### Removal of pterygium with conjunctival autograft

Another surgical technique described for pterygium removal is conjunctival autograft (CAU). It differs from simple excision of pterygium by using the patient's own conjunctiva harvested from another part of the same or opposite eye. A graft of bulbar conjunctiva is typically harvested from under the upper eyelid. The graft is placed in the area where the pterygium was removed and then secured to the sclera using tissue glue (fibrin glue) or sutures. The use of tissue glue significantly shortens the operation time and reduces postoperative pain and discomfort, but there is a risk of infection or graft displacement. It should be emphasized that with this surgical method, potential limitations include extensive pterygium, non-inflammatory conjunctival changes, and patients scheduled for future glaucoma procedures [9].

### Removal of pterygium with limbal-conjunctival autograft

The surgery performed using the limbal-conjunctival autograft (LCAG) method is carried out similarly to the technique described above. The graft material used is a limbal tissue containing stem cells, which are intended to accelerate corneal epithelialization after the procedure. These cells are located between the cornea and the bulbar conjunctiva. This technique involves harvesting limbal cells from the healthy eye to cover the area from which the pterygium was removed. The goal of the graft is to reconstruct the normal corneal epithelium. Intraoperatively, MMC at a concentration of 0.02% and postoperatively, cyclosporine A at a concentration of 0.05% in the form of eye drops can be used to minimize the risk of recurrence [9, 10].

### Removal of pterygium with amniotic membrane transplant

Amniotic membrane transplant (AMT) is a method increasingly used in pterygium surgeries. The amniotic membrane is obtained from the placenta acquired during cesarean section. Due to its analogous structure to the conjunctiva, the amniotic membrane can be used as a dressing graft because it has properties that accelerate the growth and differentiation of epithelial cells. In the procedure, after removing the pterygium (fig. 2), the exposed sclera is covered with the amniotic membrane, which according to this technique is placed epithelium-side up and stroma-side towards the sclera. It is secured, similar to other methods, using tissue glue or sutures (fig. 3). Intraoperative use of MMC did not show a significant difference in recurrence rates. An important advantage of this method is that it may have a beneficial effect on patients with large conjunctival scars or patients

FIGURE 2

Pterygium before surgery.

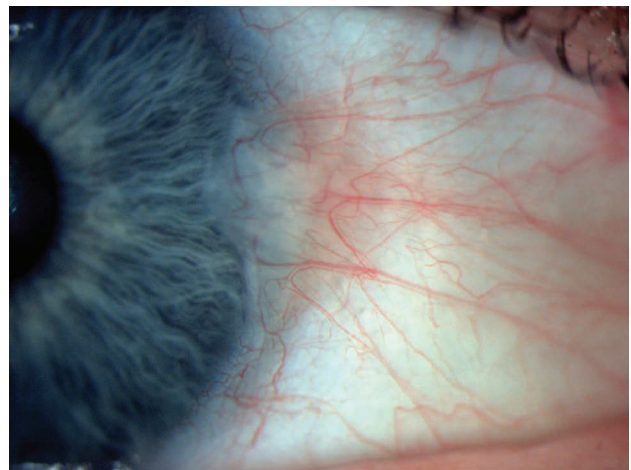
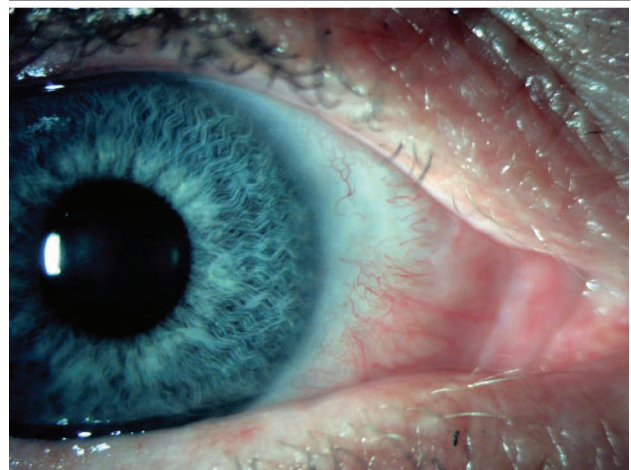


FIGURE 3

Results after surgery using AMT method with fibrin glue.



qualified for surgical treatment of glaucoma. Complications related to the above surgical technique are similar to those with the use of conjunctival autograft and include, among others, the formation of conjunctival granuloma and impaired ocular motility [9, 11].

### The perfect technique

This proprietary technique was developed by Lawrence Hirst and involves extensive dissection and removal of the Tenon's layer, which likely accounts for the low recurrence rate. The extensive conjunctival graft and the fact that the incision lines are hidden under the upper and lower eyelids and under the semilunar fold make the cosmetic outcome achieved by this method of pterygium removal very good. In studies conducted on nearly 200 patients operated on with this technique, only one pterygium recurrence was noted, which may confirm its high effectiveness in treating this condition [12].

### Simple limbal epithelial transplant

The simple limbal epithelial transplant (SLET) surgical technique was first developed in 2012 to treat limbal stem cell deficiency (LSCD) resulting from thermal or chemical injuries and primary pterygium excision. The damaged limbal tissue begins to be gradually replaced by conjunctival epithelium, which is non-transparent, leading to reduced visual acuity. In this technique, limbal stem cells harvested from the healthy eye are used and then transplanted onto the diseased cornea [13]. Autologous or allogeneic cells can be used for transplantation [14].

### Minimal simple limbal epithelial transplant

In recent years, the SLET technique has been modified to perform a mini-SLET procedure, which essentially involves harvesting a smaller amount of epithelium containing limbal stem cells for transplantation. A randomized study was conducted to compare mini-SLET (mini-simple limbal epithelial transplant) with the CLAU technique (conjunctival-limbal autograft) in terms of increased risk of pterygium recurrence. Participants with primary pterygium were divided into two groups. In the case of patients operated on using the CLAU method, the risk of recurrence at 6 and 12 months after surgery was 8.1%. However, in the group of patients operated on using the mini-SLET technique, the recurrence risk was 50% at 6 months and 53.5% at 12 months after the procedure. There were no intraoperative or postoperative complications in either of these techniques. CLAU and CAU methods are considered the gold standard in primary pterygium surgery. Contraindications to these methods include the need for future glaucoma surgeries and the inability to obtain conjunctiva from a donor. In such situations, the mini-SLET technique has an advantage over CLAU and CAU techniques. Despite the higher recurrence

rate, this technique is preferred when less corneal-limbal tissue is harvested [15].

### The use of corneal micro-lens obtained from SMILE surgery as a free graft in the treatment of primary pterygium

The modern refractive procedure SMILE (small incision lenticule extraction) is used in the treatment of myopia with or without astigmatism. The procedure is performed under local anesthesia without creating a corneal flap using a femtosecond laser. The corneal micro-lens obtained from a donor from laser SMILE surgery is transferred to the site where the pterygium tissue was excised from the recipient. It is then sutured to the cornea using 10-0 nylon sutures [16]. In the case report Mutulu et al. describe how they decided to use the aforementioned method in the treatment of primary pterygium [16]. Among the main advantages of this approach mentioned by the authors in their publication is the healthy upper conjunctiva of the graft recipient, which remains untouched, preventing the formation of scars. This is particularly important because the intact conjunctiva can be used in the future for possible glaucoma surgery, including trabeculectomy if the patient requires it. It can also be used as a free graft in case of other corneal disorders in patients such as corneal micro-perforations or corneal ulcers. If necessary, the procedure itself can be repeated, which is more advantageous in terms of time and requires less financial investment. In the report described by the authors, it was shown that the corneal micro-lens obtained during SMILE surgery can be used in the treatment of primary pterygium. This innovative method is considered safe and can bring many benefits to future patients [16].

## POSTOPERATIVE MANAGEMENT

In the postoperative management, it is recommended that the patient use soft therapeutic contact lenses until the next scheduled ophthalmic check-up. The application of bandage lenses aims to expedite corneal epithelialization, alleviate discomfort after the procedure, and stabilize the conjunctival graft [17]. Additionally, the ophthalmologist advises the use of antibiotics for approximately 10 days and short-term topical steroids. If non-absorbable fixation sutures are used, they are removed around one week after the surgery. The patient should be thoroughly informed to use moisturizing eye drops during the recovery period and to wear UV-filtered sunglasses for sun protection.

## CONCLUSION

In our geographical region, pterygium occurs significantly less frequently and present with milder symptoms compared to those in countries within the equatorial zone. One

of the main factors contributing to the development of this condition is considered to be damage to the corneal limbus within the eyelid fissure due to UV radiation. Although in most cases, pterygium does not cause serious health complications and has a favorable prognosis, there is a risk of corneal scarring, which can significantly impair vision. In cases where the patient does not experience any discomfort associated with pterygium, only self-observation of the condition at home and regular ophthalmic check-ups at least once a year are recommended. The doctor should inform the patient about further recommendations such as wear-

ing sunglasses with UV filters to protect against the harmful effects of UV radiation. Research on determining the exact pathogenesis of pterygium is still ongoing. The high recurrence rate of the condition poses a significant problem and therapeutic challenge in terms of treating relapses. Understanding the mechanisms leading to the development of this condition will be particularly helpful in developing more effective treatment strategies aimed at reducing the frequency of recurrences.

*Figures: from the authors' own materials.*

#### CORRESPONDENCE

##### Oliwia Cwalina, MD

Faculty of Medicine and Health Sciences, Andrzej Frycz Modrzewski Krakow University  
30-705 Kraków, ul. Gustawa Herlinga-Grudzińskiego 1  
tel.: (+48) 791-000-348  
e-mail: oliwia.cwalina97@gmail.com

#### ORCID

Oliwia Cwalina – ID – <https://orcid.org/0000-0002-7071-0273>  
Zuzanna Mrugała – ID – <https://orcid.org/0009-0005-3520-1755>  
Monika Molga – ID – <https://orcid.org/0009-0000-4948-9466>  
Katarzyna Chamera-Cyrek – ID – <https://orcid.org/0009-0001-3894-7078>  
Liliana Dyląg – ID – <https://orcid.org/0009-0009-0059-5204>  
Oliwia Sikora – ID – <https://orcid.org/0009-0008-5885-2675>  
Bartłomiej Żaczek – ID – <https://orcid.org/0000-0002-9184-3649>  
Jan Maciej Baran – ID – <https://orcid.org/0009-0008-1798-0857>  
Dawid Rowiński – ID – <https://orcid.org/0009-0006-0824-1548>  
Clara Kuźmiński – ID – <https://orcid.org/0009-0003-2005-1614>  
Aneta Podczerwińska – ID – <https://orcid.org/0009-0000-9625-3640>  
Ilona Pawlicka – ID – <https://orcid.org/0000-0003-1556-7678>  
Anna Maria Roszkowska – ID – <https://orcid.org/0000-0002-8083-3437>  
Maciej Kozak – ID – <https://orcid.org/0000-0001-7993-2588>

#### References

1. Szaflik J, Izdebska J. Choroby aparatu ochronnego oka i rogówki. Basic and Clinical Science of Course. American Academy of Ophthalmology. Wrocław 2019.
2. Zagórski Z, Naumann GOH, Watson P. Choroby rogówki, twardówki i powierzchni oka. Wyd. Czelej, Lublin 2012.
3. Baهران SS, Alany RG, Schwikkard S et al. Pharmacological treatment strategies of pterygium: Drugs, biologics, and novel natural products. Drug Discov Today. 2023; 28(1): 103416. <https://doi.org/10.1016/j.drudis.2022.103416>.
4. Spaeth GL, Danesh-Meyer HV, Goldberg I et al. Chirurgia okulistyczna. Edra Urban & Partner, Wrocław 2016.
5. Xu W, Jin L, Zhu PZ et al. Implementation and Application of an Intelligent Pterygium Diagnosis System Based on Deep Learning. Front Psychol. 2021; 12: 759229. <https://doi.org/10.3389/fpsyg.2021.759229>
6. Niżankowska HM. Okulistyka. Podstawy kliniczne. Wydawnictwo Lekarskie PZWL, Warszawa 2007: 164-165.
7. Liu J, Xu JH, Xu W et al. Bevacizumab as adjuvant therapy in the management of pterygium: a systematic review and Meta-analysis. Int J Ophthalmol. 2017; 10(7): 1126-33. <https://doi.org/10.18240/ijo.2017.07.17>.
8. Palewski M, Budnik A, Konopińska J. Evaluating the Efficacy and Safety of Different Pterygium Surgeries: A Review of the Literature. Int J Environ Res Public Health. 2022; 19: 11357. <https://doi.org/10.3390/ijerph191811357>.
9. Shahraki T, Arabi A, Feizi S. Pterygium: an update on pathophysiology, clinical features, and management. Ther Adv Ophthalmol. 2021; 13: 25158414211020152. <http://doi.org/10.1177/25158414211020152>.

10. Kaufman SC, Jacobs DS, Lee WB et al. Options and Adjuvants in Surgery for Pterygium. *Ophthalmology*. 2013; 120(1): 201-8. <https://doi.org/10.1016/j.ophtha.2012.06.066>.
11. Rosen R. Amniotic Membrane Grafts to Reduce Pterygium Recurrence. *Cornea*. 2018; 37(2): 189-93. <http://doi.org/10.1097/ICO.0000000000001407>.
12. AAO. Treating Pterygium: Innovation from Australia - American Academy of Ophthalmology. <https://www.aao.org/eyenet/article/treating-ptyerygium-innovation-from-australia>
13. Mednick Z, Boutin T, Einan-Lifshitz A et al. Simple limbal epithelial transplantation for recurrent pterygium: A case series. *Am J Ophthalmol Case Rep*. 2018; 12: 5-8. <http://doi.org/10.1016/j.ajoc.2018.07.006>.
14. Cholewa D, Mazur R, Wylęgała E. Leczenie niewydolności rąbkowych komórek macierzystych – aktualny stan wiedzy. *Magazyn Lekarza Okulisty*. 2019; 13(4): 191-202.
15. Oliva-Biénzobas V, Nava-Castañeda A, Jimenez-Corona A et al. Comparison of mini-simple limbal epithelial transplantation and conjunctival-limbal autograft for the treatment of primary pterygium: a randomised controlled trial. *Br J Ophthalmol*. 2023; 107(12): 1776-81. <http://doi.org/10.1136/bjo-2021-320707>.
16. Mutlu SN, Evereklioglu C, Najafi J et al. Transparent intrastromal corneal lenticule obtained from SMILE surgery as a free graft for the treatment of primary pterygium: A pilot study. *Am J Ophthalmol Case Rep*. 2023; 32: 101897. <https://doi.org/10.1016/j.ajoc.2023.101897>.
17. Śliwiak D. Metody leczenia skrzydlika – od postępowania zachowawczego po operacyjne. *Okulistyka po Dyplomie*. 2023; 13: 8-14.

**Authors' contributions:**

All authors have equal contribution to the paper.

**Conflict of interest:**

None.

**Financial support:**

None.

**Ethics:**

The content presented in the article complies with the principles of the Helsinki Declaration, EU directives and harmonized requirements for biomedical journals.