

# Therapeutic approach to ocular coloboma – a case report of a 37-year-old patient with high myopia and choroidal coloboma of the right eye



Klaudia Szala<sup>1</sup>, Sebastian Sirek<sup>2,3</sup>,  
Dorota Wyględowska-Promieńska<sup>2,3</sup>

<sup>1</sup> Students' Scientific Society, Department of Ophthalmology, Faculty of Medical Sciences, Medical University of Silesia in Katowice, Poland  
Head: prof. Dorota Wyględowska-Promieńska, MD, PhD

<sup>2</sup> Department of Ophthalmology, Faculty of Medical Sciences, Medical University of Silesia in Katowice, Poland  
Head: prof. Dorota Wyględowska-Promieńska, MD, PhD

<sup>3</sup> Department of Adult Ophthalmology, Prof. Kornel Gibirski University Clinical Center, Medical University of Silesia in Katowice, Poland  
Head: prof. Dorota Wyględowska-Promieńska, MD, PhD

## HIGHLIGHTS

The presence of a coloboma predisposes to conditions treated with good anatomical results, but functional outcomes reflect the complexity of the disease and associated abnormalities.

## ABSTRACT

**Introduction:** Coloboma is a congenital malformation caused by a defect of optic fissure closure. We report a rare case of choroidal coloboma and management of possible complications.

**Clinical case:** A 37-year-old patient presented for the current evaluation of uveal coloboma located in the inferior-nasal quadrant with the involvement of the optic disc and advanced high myopia.

**Conclusions:** The management of coloboma includes follow-up of visual acuity level, anterior segment and fundus evaluations. Retinal detachment, cataract and choroidal neovascularization may occur secondary to the defect. Pars plana vitrectomy, autologous neurosensory retinal transplantation and laser therapy are considered methods in present case.

**Key words:** coloboma, high myopia, visual evoked potentials, VEP

## INTRODUCTION

Ocular coloboma is a term derived from the Greek word *coloboma*, meaning “mutilated” or “curtailed” [1]. It is a congenital malformation visible as a “defect” in the iris and/or the structures behind it, up to the optic nerve. The underlying cause of the defect is the failure of closure or only partial closure of the optic fissure during embryogenesis. By the 5<sup>th</sup> week of pregnancy, the edges of the optic fissure displace the periocular mesenchyme to merge in the central area. Physiologically, closure of the fissure occurs by the 7<sup>th</sup> week of pregnancy [2]. Coloboma was first described in 1673 (Caspar Bartholin the Younger) and was located in the iris, which is its most commonly observed site. Clinically, coloboma typically appears as an inferior iris fissure, but it can also affect the cornea, lens, choroid, retina, and even the optic nerve, depending on the embryonic stage when the fissure fails to close. The later the ineffective closure occurs during embryogenesis, the higher the likelihood of the defect occurring only within the iris.

Typically, coloboma is observed in the nasal-inferior quadrant of the eye and may also involve the optic disc partially or completely. Choroidal coloboma is a rare anomaly. The prevalence rates identified in an epidemiological study of congenital eye developmental defects in 131,760 consecutive births were 0.7 per 10,000 for coloboma. The frequency of coloboma among blind adults was estimated to be 0.6–1.9%, while among children, it constitutes a higher percentage of the causes of blindness (3.2–11.2%) [3].

## CASE STUDY

A 37-year-old female patient presented to the Preclinical Ophthalmology Clinic for a follow-up and assessment of the current state of a diagnosed coloboma in the choroid of the right eye, classified as type 2 according to Ida Mann classification [4], and advanced high myopia. In the refraction measurements after the application of 1% tropicamide, the following results were obtained: in the right eye -7.00 spherical diopters (Dsph) and -1.75 cylindrical diopters (Dcyl) at an axis of 115°; in the left eye -7.00 Dsph and -1.00 Dcyl at an axis of 14°.

The patient underwent additional examinations: optical coherence tomography (OCT) in 3D projection (fig. 1), revealing thinning of retinal layers and disrupted layered structure at the transition of neurosensory retina into the coloboma. Additionally, B-projection ultrasound examination (B-projection USG) of the right eye (fig. 2) showed an irregular outline of the eye fundus with a deepening in the nasal-inferior quadrant corresponding to the coloboma. Intraocular pressure values were measured, yielding results of 16 mmHg for the right eye and 20 mmHg for the left eye. Visual acuity assessment using a Snellen chart at a distance revealed a level of 0.1 in the right eye and 0.8 in the left eye.

FIGURE 1

OCT of the right eye, 3D projection.

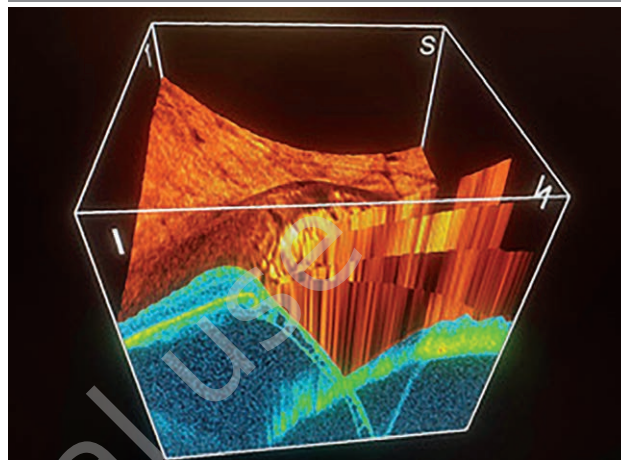
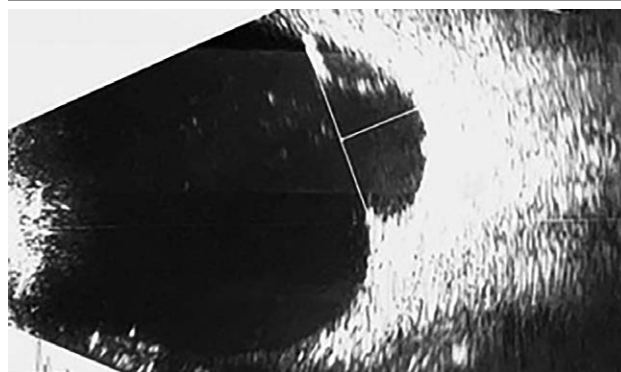


FIGURE 2

An ultrasound examination of the patient's right eye.



The visual field of both eyes was assessed using static perimetry. In the right eye, an absolute scotoma was observed in the nasal-lower quadrant (fig. 3).

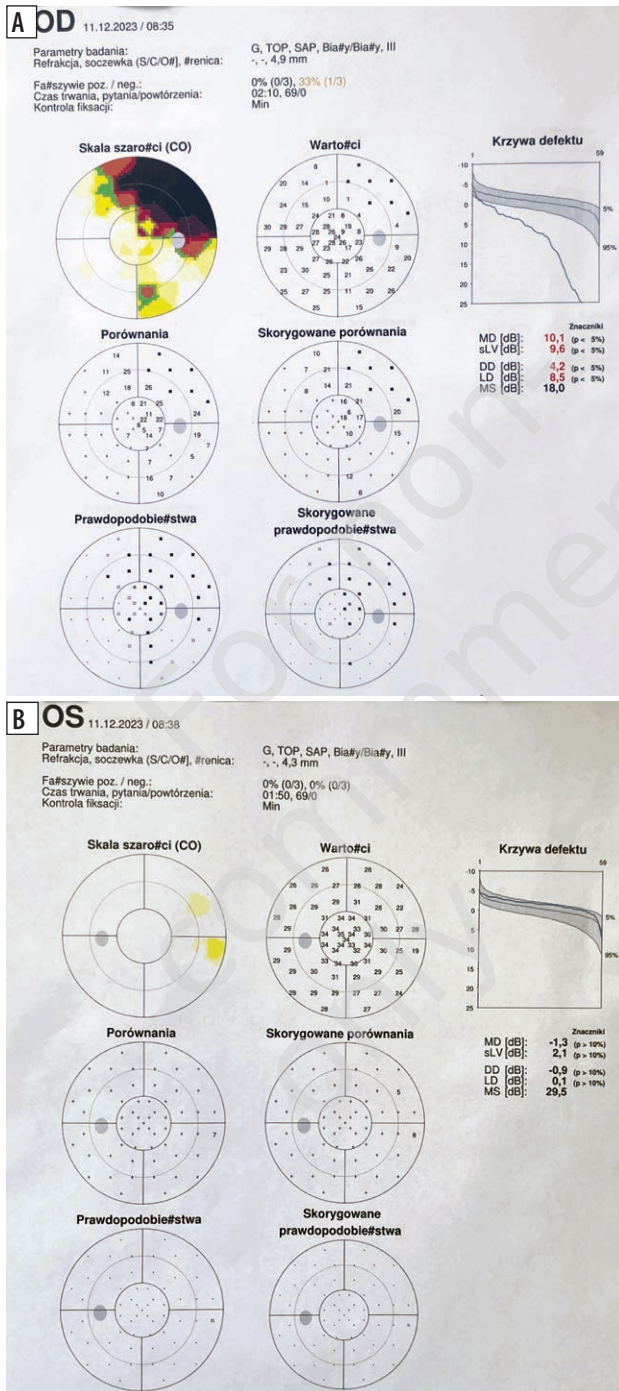
The Visual Evoked Potentials (VEP Pattern) examination (fig. 4) revealed P100 wave latencies following stimulation at 1° (fig. 4A) and 15' (fig. 4B) with normal values in both eyes. The P100 wave amplitudes in the right eye were 40% of the norm, while in the left eye, they were within the normal range. An examination of the fundus of the eye was performed using a slit lamp after the administration of 1% tropicamide eye drops for pharmacological mydriasis. The purpose was to determine the extent of the coloboma in the right eye (fig. 5A) in comparison to the left eye without the presence of coloboma (fig. 5B). The affected area involves the nasal-inferior quadrant with the optic disc and macula.

## DISCUSSION

Congenital choroidal coloboma can present as an isolated condition or coexist as a component of various syndromes,

FIGURE 3

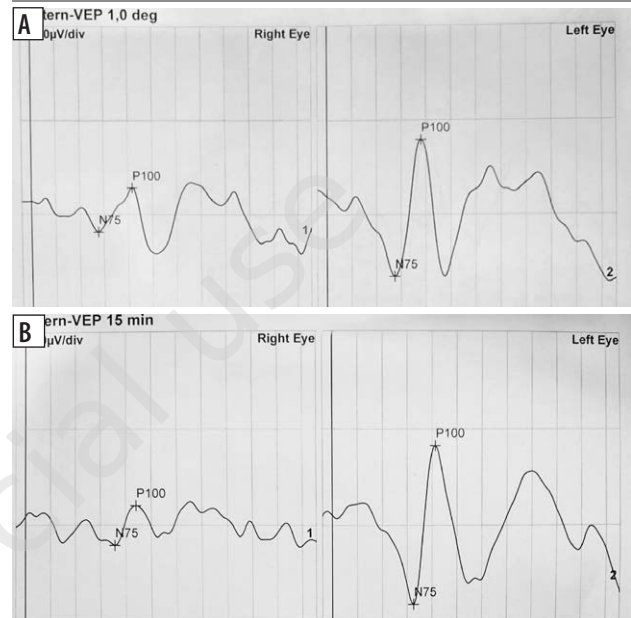
Static perimetry of both patient's eyes, visual field examination in the right eye (A), visual field examination in the left eye (B).



such as CHARGE syndrome, microphthalmia, Patau syndrome, Edwards syndrome, cat eye syndrome, Treacher Collins syndrome, cryptophthalmos, MOTA syndrome, Fraser syndrome, Goldenhar syndrome, MPPC syndrome, ODD syndrome, DiGeorge syndrome [5].

FIGURE 4

Visual Evoked Potentials (VEP Pattern) examination in the patient after stimulation: 1° (A), 15' (B).



Morphogenetic events in the pathomechanism of coloboma formation have been well characterized, but the molecular mechanisms driving these processes are not fully elucidated. Limited access to tissues for research due to the very early time of ocular fissure morphogenesis has hindered a comprehensive understanding. Consequently, much of our current knowledge comes from murine and fish models of the disease phenotype, indicating that gene mutations, possibly influenced by external factors such as vitamin A deficiency or maternal folic acid deficiency during pregnancy, maternal thyroid dysfunction, maternal alcohol consumption, exposure to mycophenolate mofetil, and congenital Zika virus infection, may contribute to coloboma [6].

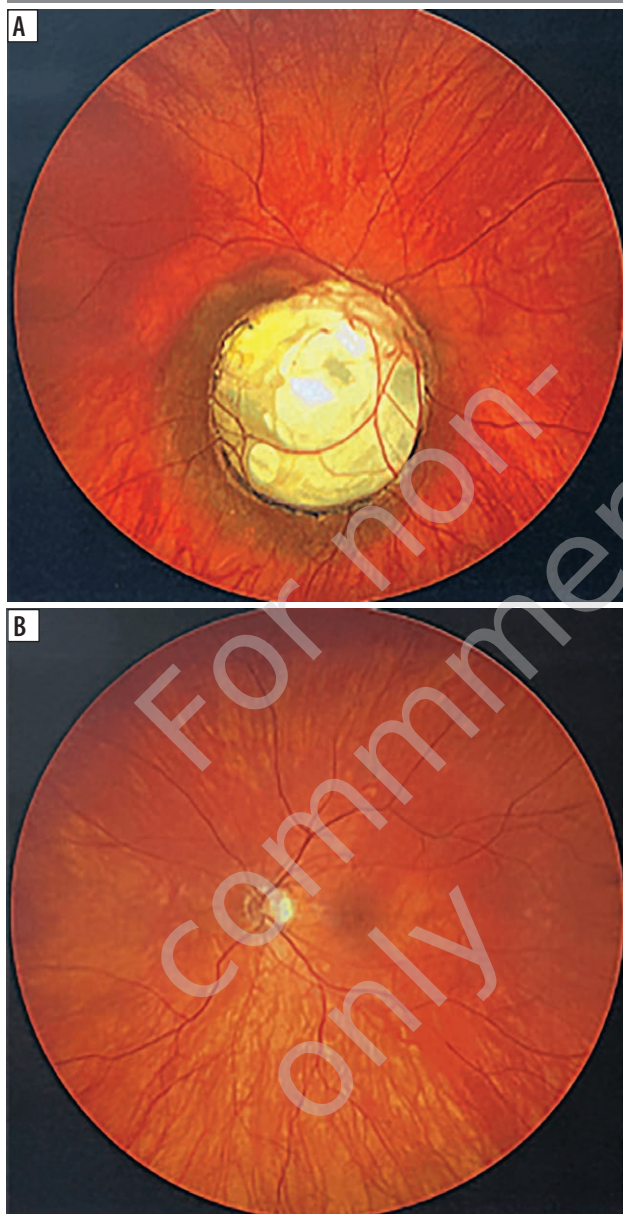
Coloboma can occur symmetrically, where both eyes are equally affected, or asymmetrically, with noticeable differences between the left and right eyes. The impact on visual impairment can range from complete vision loss to asymmetry, depending on the involved structures. Currently, only coloboma of the iris can be treated surgically [7].

In the case of our patient, coloboma is accompanied by high bilateral myopia and astigmatism, without other concurrent systemic anomalies. Coloboma can influence the shape of the eye, thereby disrupting proper refraction and resulting in myopia, hyperopia or astigmatism. The B-projection USG of the patient's eye (fig. 2) visualized irregular outline of the eye fundus with a deepening in the nasal-inferior quadrant corresponding to the coloboma. In such cases, systematic monitoring of the fundus is crucial due to potential complications such as retinal detachment (RD), cataract formation, or choroidal neovascularization (CNV) [8]. In such situa-



FIGURE 5

Funduscopy after the administration of 1% tropicamide. Image of the right eye fundus (A), image of the left eye fundus (B).



tions, regular monitoring of coexisting conditions and the application of precise optical correction or contact lenses are essential for ensuring long-term quality of life, with the possibility of maintaining useful visual acuity.

### Retinal detachment secondary to coloboma

Retinal detachment is the most serious complication posing a threat to vision in coloboma cases. Retinal fractures are similarly often located inside the coloboma as well as outside its area. The literature reports that their mutual ratio is respectively 27% to 33% (in a study conducted on 15 eyes) [5] and 40% to 40% (in a study on 10 eyes) [9].

Treatment methods for this complication include pars plana vitrectomy (PPV) with or without lensectomy, laser ablation around the coloboma and peripheral fractures (if present), followed by tamponade with silicone oil or long-acting gas. These procedures are commonly performed with relatively good results. However, redetachment is a viable complication [9], often associated with proliferative vitreoretinopathy [10].

Specifically, PPV with simultaneous tamponade using silicone oil statistically provides the best anatomical outcomes. However, functional results reflect the complexity of the disease and its associated abnormalities. A 40-month observation of 28 eyes showed a 92.9% rate of adequately attached retinas, but visual acuity equal to or better than 0.05 was achieved in only 35.7% [11]. In a later study on 10 eyes with an average observation period of 28.8 ( $\pm 28.4$ ) months, the final mean visual acuity in patients with measurable visual acuity was 0.1 ( $P=0.06$ ) and the retina was properly reattached in 9 eyes (90%) [9]. The most recent results of a retrospective analysis of consecutive patients with RD secondary to coloboma who underwent 23/25G PPV with silicone oil tamponade, evaluating 148 eyes with an average follow-up of 13.1 ( $\pm 13.8$ ) months (range: 3–84 months), demonstrate a 88.5% surgical success rate (131 eyes) with an overall successful outcome achieved in 90.5% (134 eyes). RD recurrence occurred in 17 eyes (11.5%) with an average period of 2.59 ( $\pm 3$ ) months. Eyes that additionally underwent relaxing retinectomy (RR) were more susceptible to redetachment. Correlating factors with the risk included: the type of coloboma, age  $<16$  years, postoperative condition after eye banding, performance of RR, 360° laser barricade, sparing laser therapy to the pit and pars plana lensectomy (PPL). Out of 148 eyes, 109 eyes (73.6%) showed improved best-corrected visual acuity after surgery [12].

Previous studies on colobomatous eyes: 42 eyes [13] and 5 eyes [14], assumed the inclusion of endolaser therapy, with shorter follow-up periods of 3–30 months [13] and 12 months [14], demonstrating success rates of adequately attached retinas at 88.1% [13] and 100% [14], respectively. The best-corrected visual acuity was 0.05 or better in 33 eyes (78.4%) [13] and improvement from preoperative light or hand motion perception to finger counting occurred in 2 eyes, with 3 eyes maintaining preoperative visual acuity at the last follow-up after the intervention [14]. The study conducted on a smaller number of eyes ( $n=5$ ) focused on choroidal coloboma with optic disc involvement [14].

Currently, hope for effective prevention of redetachments secondary to coloboma with optic disc involvement lies in the method of autologous neurosensory retina transplantation [15] to cover the optic disc defect. As a postoperative complication, consideration should be given to high intraocular pressure, for which cycloablation is necessary [15].

The prolonged follow-up and the functional outcomes after surgical interventions demonstrate the complexity of the problem in treating redetachment secondary to coloboma. The challenges arising during the treatment of these RDs indicate that taking preventive measures against their occurrence may be crucial. In a group of paediatric patients with choroidal-retinal coloboma, the justification for using low-intensity light laser photocoagulation along the coloboma edge as prophylactic treatment for rhegmatogenous retinal detachment (RRD) was demonstrated. The study included a total of 335 eyes, of which 103 (30.7%) underwent prophylactic laser photocoagulation. In the untreated group, RRD developed in 56 eyes (24.1%). In the photocoagulated group, there were 3 cases (2.9%) of RRD. The probability of developing RRD was 10.606 times higher in individuals who did not receive prophylactic laser treatment. Although the procedure reduces the risk of RRD, it does not eliminate it entirely [16].

### Choroidal neovascularization in coloboma

In the case of CNV arising from coloboma, there are limited reported cases. The primary method of treatment is laser therapy, with satisfactory results in the regression of neovascularization and preservation of previous best-corrected visual acuity [5]. CNV was treated with thermal laser photocoagulation, and the visual acuity in an eye with a large choroidal-retinal coloboma in the lower quadrant, involving the macula and optic disc, improved from 0.05 to 0.125. This improvement remained stable for 12 years after treatment [17]. Photodynamic therapy combined with intravitreal bevacizumab injections may be an alternative

method for treating recurrent CNV after laser photocoagulation in eyes with choroidal-retinal coloboma [18].

### CONCLUSIONS

In the case of a patient with choroidal coloboma, high bilateral myopia, and astigmatism without other associated systemic anomalies, regular monitoring of visual acuity, assessment of the anterior segment, and fundus examination are crucial. Monitoring concurrent eye conditions and applying the most accurate optical correction, including eyeglasses or contact lenses, helps to maintain long-term good quality of life and useful visual acuity.

Efforts are ongoing to find methods to prevent complications associated with coloboma, including RD, cataracts and CNV. Surgical intervention for secondary complications is crucial, with 23/25G PPV being the standard for RD, accompanied by simultaneous tamponade with silicone oil. While this method improves best-corrected visual acuity, it does not entirely prevent redetachment. Hopes for improvement in this regard lie in the autologous neurosensory retina transplant method. Among the paediatric population with choroidal-retinal coloboma, laser photocoagulation has been shown to reduce the risk of RD but does not eliminate it entirely. Satisfactory results in regressing CNV are achieved with laser therapy. In recurrent cases of CNV, combining laser photodynamic therapy with intravitreal bevacizumab injections demonstrates promising outcomes. The mentioned treatments are associated with statistically good anatomical results, but functional outcomes reflect the complexity of the disease and its associated abnormalities.

*Figures: from the authors' own materials.*

### CORRESPONDENCE

**Klaudia Szala, med student**

Students' Scientific Society, Department of Ophthalmology,  
Faculty of Medical Sciences, Medical University of Silesia,  
Katowice  
40-514 Katowice, ul. Ceglana 35  
e-mail: klaudia.szala@gmail.com  
phone: (+48) 508 915 524

### ORCID

Klaudia Szala – ID – <http://orcid.org/0009-0007-7715-8024>  
Sebastian Sirek – ID – <http://orcid.org/0000-0002-3138-3011>  
Dorota Wyględowska-Promieńska – ID – <http://orcid.org/0000-0001-5336-3460>

### References

1. Gregory-Evans CY, Williams MJ, Halford S et al. Ocular coloboma: a reassessment in the age of molecular neuroscience. *J Med Genet.* 2004; 41(12): 881-91. <https://doi.org/10.1136/JMG.2004.025494>.
2. ALSomiry AS, Gregory-Evans CY, Gregory-Evans K. An update on the genetics of ocular coloboma. *Hum Genet.* 2019; 138(8-9): 865-80. <https://doi.org/10.1007/S00439-019-02019-3>.

3. Warburg M. Classification of microphthalmos and coloboma. *Med Genet*. 1993; 30: 664-9. <https://doi.org/10.1136/jmg.30.8.664>.
4. Lingam G, Sen AC, Lingam V et al. Ocular coloboma – a comprehensive review for the clinician. *Eye*. 2021; 35(8): 2086-109. <https://doi.org/10.1038/s41433-021-01501-5>.
5. Hussain RM, Abbey AM, Shah AR et al. Chorioretinal Coloboma Complications: Retinal Detachment and Choroidal Neovascular Membrane. *J Ophthalmic Vis Res*. 2017; 12(1): 3. <https://doi.org/10.4103/2008-322X.200163>.
6. Selzer EB, Blain D, Hufnagel RB et al. Review of evidence for environmental causes of uveal coloboma. *Surv Ophthalmol*. 2022; 67(4): 1031-47. <https://doi.org/10.1016/J.SURVOPHTHAL.2021.12.008>.
7. Ogawa GSH. Congenital iris coloboma repair with excision of colobomatous sphincter muscle. *J Cataract Refract Surg*. 2021; 47(8): 1088-91. <https://doi.org/10.1097/JJCRS.0000000000000440>.
8. Onwochei BC, Simon JW, Bateman JB et al. Ocular Colobomata. *Surv Ophthalmol*. 2000; 45(3): 175-94. [https://doi.org/10.1016/S0039-6257\(00\)00151-X](https://doi.org/10.1016/S0039-6257(00)00151-X).
9. Hocaoglu M, Karacorlu M, Ersoz MG et al. Outcomes of vitrectomy with silicone oil tamponade for management of retinal detachment in eyes with chorioretinal coloboma. *Retina*. 2019; 39(4): 736-42. <https://doi.org/10.1097/IAE.0000000000000214>.
10. Hanneken A, de Juan E, McCuen BW. The Management of Retinal Detachments Associated With Choroidal Colobomas by Vitreous Surgery. *Am J Ophthalmol*. 1991; 111(3): 271-5. [https://doi.org/10.1016/S0002-9394\(14\)72309-8](https://doi.org/10.1016/S0002-9394(14)72309-8).
11. Ramezani A, Dehghan MH, Rostami A et al. Outcomes of Retinal Detachment Surgery in Eyes with Chorioretinal Coloboma. Original Article. *J Ophthalmic Vis Res*. 2010; 5(4): 240-5.
12. Shenoy P, Katre PS, Kohli GM et al. Coloboma associated retinal detachment: Anatomical and functional results in the era of microincision vitrectomy surgery with an evaluation of risk factors for a recurrence. *Indian J Ophthalmol*. 2022; 70(7): 2498-504. [https://doi.org/10.4103/ijo.IJO\\_2615\\_21](https://doi.org/10.4103/ijo.IJO_2615_21).
13. Pal N, Azad R, Sharma Y. Long-term anatomical and visual outcome of vitreous surgery for retinal detachment with choroidal coloboma. *Indian J Ophthalmol*. 2006; 54(2): 85-8. <https://doi.org/10.4103/0301-4738.25827>.
14. Wei Y, Li Y, Chen F. Vitrectomy treatment of retinal detachments related to choroidal coloboma involving the disk. *Retina*. 2014; 34(6): 1091-5. <https://doi.org/10.1097/IAE.0000000000000088>.
15. Temmerman IM, Mahmoud TH, Veckeneer MAH. Autologous neurosensory retinal transplant to treat refractory serous retinal detachment secondary to optic disk coloboma. *Retin Cases Brief Rep*. 2022; 16(5): 606-9. <https://doi.org/10.1097/ICB.0000000000001031>.
16. Uhumwangho OM, Jalali S. Chorioretinal coloboma in a paediatric population. *Eye*. 2014; 28(6): 728. <https://doi.org/10.1038/EYE.2014.61>.
17. Spitzer M, Grisanti S, Bartz-Schmidt KU et al. Choroidal neovascularization in retinochoroidal coloboma: thermal laser treatment achieves long-term stabilization of visual acuity. *Eye*. 2006; 20(8): 969-72. <https://doi.org/10.1038/SJ.EYE.6702081>.
18. Lee SH, Ahn JK, Yu HG. The Development of Recurrent Choroidal Neovascularization in a Patient with Choroidal Coloboma. *Korean J Ophthalmol*. 2011; 25(1): 63-5. <https://doi.org/10.3341/KJO.2011.25.1.63>.

**Authors' contributions:**

Klaudia Szala: data collecting, draft manuscript preparation, figure preparation.

Sebastian Sirek: study conception and design, analysis and interpretation of results, draft manuscript preparation.

Dorota Wyględowska-Promieńska: study conception and design, editorial corrections, content supervision.

All authors reviewed the results and approved the final version of the manuscript.

**Conflict of interest:**

The authors declare no conflict of interest.

**Financial support:**

None.

**Ethics:**

The content presented in the article complies with the principles of the Helsinki Declaration, EU directives and harmonized requirements for biomedical journals.