


# Triple hit on ocular surface inflammation – case reports



## Marek E. Prost

Department of Ophthalmology, Military Institute of Aviation Medicine, Warsaw  
Head: Radosław Różycki, MD, PhD

### HIGHLIGHTS

Combined eye drops in the form of suspensions are a good alternative to eye drops in the treatment of ocular surface disorders of unknown etiology.

### ABSTRACT

In everyday medical practice, finding the exact cause of conjunctivitis can be difficult without thorough laboratory testing. Therefore, the paper presents cases of treating ocular surface disorders of unknown etiology with the help of combination preparations in the form of a suspension, which allows a wide range of therapeutic effects including bacteria, chlamydia and allergic inflammation and provides a more stable and longer-lasting drug concentration level compared to drugs in the form of aqueous solutions.

**Key words:** ocular surface disease, treatment

## INTRODUCTION

Conjunctivitis and blepharitis are common causes of patient presentation to ophthalmic practice. Although finding the specific cause of inflammation can be difficult without thorough laboratory tests [1], the ophthalmologist must still offer the patient treatment with a wide range of effectiveness. This publication aims to describe such cases.

### CASE ONE. PATIENT WITH CONJUNCTIVITIS

A female patient visited the ophthalmologist's office due to binocular conjunctivitis persisting for about 30 days. Initially, the symptoms manifested as moderate eye redness (congestion), intense eye itching, and significant serous discharge. The patient had a runny nose and nasal itching. After 10 days, she complained of purulent discharge causing the eyelids to stick together, particularly in the morning. The patient had previously been prescribed antibiotic eye drops by her primary care physician for a previous eye infection, but did not use them as the infection resolved quickly. The inflammatory changes did not resolve after 2 weeks, so the patient decided to seek the advice of an ophthalmologist. During the ophthalmic examination, the patient presented ocular congestion, a mucopurulent discharge, and follicular conjunctival reaction. The cornea, anterior chamber, and posterior eye segments were in norm. There was no family history of eye diseases, including recent conjunctivitis. The initial symptoms, such as congestion, pruritus, profuse serous discharge, watery runny nose, and nasal itching, suggested allergic conjunctivitis. Due to the presence of purulent discharge that lasted over 10 days, i.e., a symptom not indicative of allergic inflammation, we suspected bacterial superinfection during the course of allergic conjunctivitis. However, such symptoms should have disappeared after 7 days of administering antibiotic eye drops. The bacteriological examination of conjunctival secretions was waived since the patient had been taking eye drops with antibiotic for quite a long time. The duration of the purulent discharge and the presence of follicular conjunctival reaction may suggest a chlamydial infection, particularly given the patient's recent attendance at a swimming pool. Therefore, a three-component eye suspension containing oxytetracycline, polymyxin B, and hydrocortisone acetate was prescribed (three times a day for 2–3 weeks). In suspension formulations, the active substances are dissolved in an aqueous solution and are also present in an insoluble form. This results in a prolonged release effect of the therapeutic substance, allowing for less frequent dosing and a more stable and longer-lasting drug concentration compared to aqueous solutions. Suspensions also have a smaller peak of maximum concentration, which results in fewer side effects [2]. This preparation contains oxytetracycline, a broad-spectrum antibiotic effective against Gram-positive and some Gram-negative bacteria, including

penicillin-resistant strains, as well as chlamydia. Polymyxin B has a bactericidal effect primarily on Gram-negative bacteria, including *Enterococcus*, *Proteus*, and *Pseudomonas* strains. It is important to note that oxytetracycline is not effective against some of these bacteria [3, 4]. Oxytetracycline and polymyxin B were introduced for treatment in 1950 and 1958, respectively. However, these antibiotics are now used less frequently in ophthalmology due to the emergence of aminoglycosides and fluoroquinolones. As a result, bacterial drug resistance to these antibiotics is not increasing as rapidly as it is to fluoroquinolones [5, 6]. The drug also contains hydrocortisone, a synthetic glucocorticosteroid with anti-inflammatory and anti-allergic effects.

The treatment strategy was effective, as the symptoms of conjunctival inflammation resolved within 7 days.

### CASE TWO. PATIENT WITH CHRONIC REDNESS OF THE EYELID MARGINS

A 40-year-old female patient presented to the ophthalmologist's office with chronic blepharitis lasting with exacerbations and remissions for 2 months. The symptoms were most severe in the morning. Additionally, the patient reported dry and burning eyes. Slit-lamp examination revealed scales and debris along the eyelashes (particularly on the upper eyelids). There was significant congestion and redness of the eyelid margins, ring-like swelling of the skin around the eyelashes, absence of some eyelashes, and small ulcerations on the margins of the lower eyelids (fig. 1, 2). A follicular conjunctival reaction was also found, which is not a sign of blepharitis. No corneal changes were observed during the examination. The tear film break-up time (BUT) test showed a reduction to 5 seconds in the right eye and 6 seconds in the left eye. The clinical picture of the ocular lesions in the described patient favored anterior blepharitis. The patient received treatment

FIGURE 1

Congestion, redness, small ulcerations on the edge of the lower eyelid, and the absence of some eyelashes.

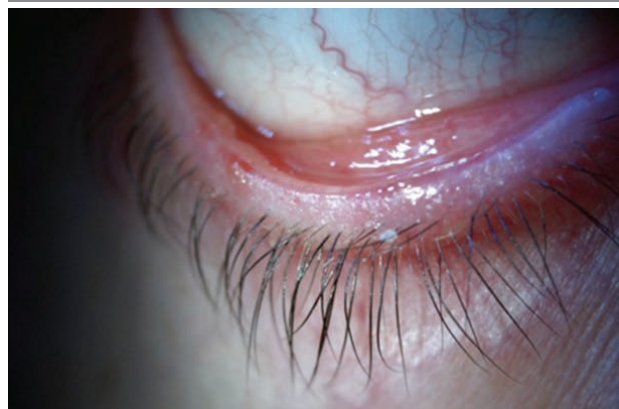
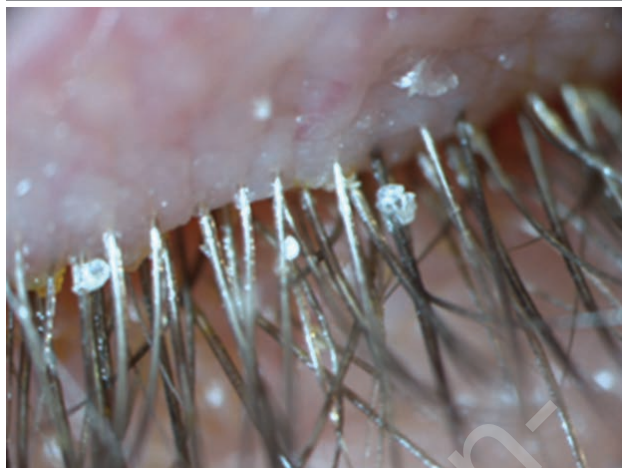
FIGURE 2

Numerous scales on the eyelashes of the upper eyelid and swelling of the skin around the eyelashes in the patient.



with various medications, primarily drops, due to discomfort with the use of eye ointments.

Blepharitis is typically caused by *Staphylococcus aureus*, which commonly colonizes the skin of the eyelids. The mechanism of inflammatory action of these bacteria is complex. In addition to directly causing blepharitis, they also release toxins and activate an excessive cellular immune response. This can lead to the development of corneal lesions, such as epithelial defects, peripheral corneal infiltrates, and corneal neovascularization. Blepharitis can increase the risk of developing styes. Anterior blepharitis appears to occur more often (80%) in women aged 40–50 years. The differential diagnosis should exclude *Demodex*, rosacea, eyelid atopic dermatitis, and psoriasis. However, in this case, the presence of a follicular conjunctival reaction characteristic of *Chlamydia*, was unusual for blepharitis.

Treating anterior blepharitis can be challenging as inflammation frequently reoccurs. The treatment involves cleaning and massaging the eyelid margins to remove scales and debris, applying heat to the eyelids using compresses and devices, and administering antibiotics and corticosteroids. The patient was prescribed an eye suspension formulation containing oxytetracycline, polymyxin B, and hydrocortisone due to poor tolerance of eye ointments. Additionally, she was advised to maintain hygiene and warm the eyelid margins. The prescribed preparation was a suspension to ensure prolonged contact with the eyelid margin. This results in a prolonged release effect of the therapeutic substances contained in it, providing a much more stable drug concentration compared to aqueous solutions. Oxytetracycline is an antibiotic that is active against Gram-positive and Gram-negative bacteria and to treat infections caused by *Chlamydia*. Oxytetracycline contains polymyxin B, a polypeptide antibiotic that primarily targets Gram-negative bac-

teria. This formulation reduces inflammation and inhibits excessive local cell-type immunity. In the treatment of anterior blepharitis, the patient was prescribed a preparation containing oxytetracycline, polymyxin B, and hydrocortisone. Additionally, eyelid hygiene and heating treatments were recommended, along with the use of artificial tears [7]. The drug prescribed contained oxytetracycline, an antibiotic that can also act on infections caused by *Chlamydia*. In this case, the presence of a follicular conjunctival reaction was indicative of *Chlamydia* infection.

#### ADVANTAGES OF COMBINED PREPARATIONS IN THE FORM OF SUSPENSIONS

Preparations containing a single active substance are typically used in the treatment of ocular surface disorders. In some patients, monotherapy may not be sufficient, particularly in cases where it is challenging to identify the precise cause of inflammation. Ocular suspensions have the effect of prolonging the release of the drug substance and providing a more stable drug concentration compared to aqueous solutions. Additionally, they are better tolerated by patients than eye ointments. Reliability of the drug is always a concern in the case of eye drops, because about 50% of patients do not comply with the treatment plan. Combination formulations help avoid prescribing multiple medications. Instead of applying, for example, 3 different types of eye drops every 5 minutes, the patient applies eye drops only once, which significantly reduces the amount of time they spend on treatment, and that in turn increases the reliability of use [8, 9]. The use of combined preparations is also associated with greater acceptance of the treatment by patients [9]. Another advantage of combination formulations is their reduced exposure to preservatives (combination formulations contain only one preservative instead of, three, sometimes different, preservatives). This minimizes the effect of preservatives on the ocular surface. Combination formulations also avoid the so-called “wash-out effect”. For many patients, especially those who are active, it is difficult to administer, for example, three drugs every 5 minutes. Therefore, patients minimize the time between injections of another drug into the conjunctival sac. This leads to a decrease in the therapeutic concentration of all drugs used, and some of them flow onto the eyelids, since the capacity of the conjunctival sac is 20–30  $\mu\text{L}$ , and each drop is 50  $\mu\text{L}$ . Drug wash-out is common and particularly affects people who use three or more types of drops or suspensions. So far, no higher incidence of side effects has been found with combination medications than with their individual components. It seems that we can expect exactly the same side effects that occur with single drug administration, but the benefit is reduced exposure to preservatives and the resulting side effects.

#### CORRESPONDENCE

**Prof. Marek E. Prost, MD, PhD**

Department of Ophthalmology,  
Military Institute of Aviation Medicine  
01-755 Warszawa, ul. Krasińskiego 54/56  
e-mail: marekprost@wp.pl

#### ORCID

Marek E. Prost – ID – <http://orcid.org/0000-0002-5620-4171>

#### References

1. Narayana S, McGee S. Bedside Diagnosis of the 'Red Eye': A Systematic Review. *Am J Med.* 2015; 128(11): 1220-4.e1.
2. Jachowicz R, Czech A. Postacie leków do oczu. In: Prost M, Jachowicz R, Nowak JZ. *Kliniczna Farmakologia Okulistyczna*. Edra Urban & Partner, 2016: 25-72.
3. Prost M. Podstawy antybiotykoterapii schorzeń powierzchni oka. *Ophththerapy. Terapie w Okulistyce.* 2014; 1(1): 26-32.
4. Prost M. Bakteryjne zapalenie spojówki i rogówki – wytyczne terapeutyczne. *Ophththerapy, Terapie w Okulistyce.* 2018; 5(suppl 1): 5-9.
5. Høvdning G. Acute bacterial conjunctivitis. *Acta Ophthalmol.* 2008; 86(1): 5-17.
6. Jefferis J, Perera R, Everitt H et al. Acute infective conjunctivitis in primary care: who needs antibiotics? An individual patient data meta-analysis. *Br J Gen Pract.* 2011; 61(590): e542-8.
7. Pflugfelder SC, Karpecki PM, Perez VL. Treatment of Blepharitis: Recent Clinical Trials. *Ocular Surface.* 2014; 12(4): 273-84.
8. Robin AL, Covert D. Does adjunctive glaucoma therapy affect adherence to the initial primary therapy? *Ophthalmology.* 2005; 112(5): 863-8. <https://doi.org/10.1016/j.ophtha.2004.12.026>.
9. Shirai C, Matsuoka N, Nakazawa T. Comparison of adherence between fixed and unfixed topical combination glaucoma therapies using Japanese healthcare/pharmacy claims database: a retrospective non-interventional cohort study. *BMC Ophthalmic.* 2021; 21(1): 52. <https://doi.org/10.1186/s12886-021-01813-w>.

#### Conflict of interest:

None.

#### Financial support:

None.

#### Ethics:

The content presented in the article complies with the principles of the Helsinki Declaration, EU directives and harmonized requirements for biomedical journals.