

# Corneal peripheral hypertrophic subepithelial degeneration — case report



**Dorota Wyględowska-Promieńska<sup>1,2</sup>, Łukasz Drzyzga<sup>2</sup>,  
Dorota Śpiewak<sup>2</sup>, Mariola Dorecka<sup>1,2</sup>**

<sup>1</sup> Department of Ophthalmology, Faculty of Medical Sciences in Katowice, Medical University of Silesia in Katowice, Poland  
Head: prof. Dorota Wyględowska-Promieńska, MD, PhD

<sup>2</sup> Department of Ophthalmology, Prof. K. Gibiński University Clinical Center, Medical University of Silesia in Katowice, Poland  
Head: prof. Dorota Wyględowska-Promieńska, MD, PhD

## ABSTRACT

**Purpose:** The aim of the paper is to present the case of a 53-year-old female patient who, based on the clinical picture and optical coherent tomography of the anterior segment (AS-OCT), was diagnosed with peripheral hypertrophic subepithelial degeneration (PHSD) and underwent surgical treatment in the form of superficial keratectomy with mechanical removal of degenerative plaques.

**Methods:** Analysis of AS-OCT images and corneal tomography based on Scheimpflug images and surgical treatment – superficial keratectomy with mechanical removal of degenerative plaques.

**Results:** Before treatment, the best corrected visual acuity (BCVA) for distance, as assessed by the Snellen chart, was 3/50 c.cor +10.50/-6.50 ax 18° in the right eye (RE) and in the left eye (LE) 5/10 c.cor +10.75/-3.00 ax 48°. Preoperative keratometry performed with the Pentacam device was K1 32.7 D and K2 46.0 D in the OP and K1 42.5 D and K2 44.7 D in the LE. Postoperative BCVA in RE was 5/8 c.cor +3.50/-1.00 ax 120° at 5 months of follow-up and in LE 5/6 c.cor +4.75/-1.00 ax 64° at 3<sup>rd</sup> month of observation. Postoperative keratometry (Pentacam) in RE K1 was 44.6 D, K2 46.9 D in the 5<sup>th</sup> month of observation, and in LE K1 45.6 D, K2 46.5 D in the 3<sup>rd</sup> month of observation. As a result of the treatment, BCVA improved, astigmatism decreased and corneal translucency improved.

**Conclusions:** AS-OCT and Scheimpflug-based corneal tomography are helpful in the diagnosis of PHSD. Superficial keratectomy with mechanical removal of degenerative plaques seems to be an effective treatment for PHSD.

**Key words:** peripheral hypertrophic subepithelial corneal degeneration, peripheral corneal haze, superficial keratectomy, Pentacam, AS-OCT

## HIGHLIGHTS

The aim of paper is to discuss a case of a rare disease called peripheral hypertrophic subepithelial degeneration, characterized by high astigmatism and low visual acuity, as well as a description of the treatment used and a discussion of the treatment results.

## INTRODUCTION

PHSD is a clinical entity of unknown etiology, described for the first time in 2003, which mainly affects young and middle-aged women and the triggering mechanism of the disease may be hormonal changes and genetic factors. PHSD is characterized by bilateral and progressive superficial fibrosis between the corneal epithelium and Bowman's layer. The changes are localized paralimbal and paracentrally, on the nasal and temporal sides. They are often accompanied by superficial limbal neovascularization, and astigmatism, which increases over time, leads to a gradual decrease in visual acuity [1].

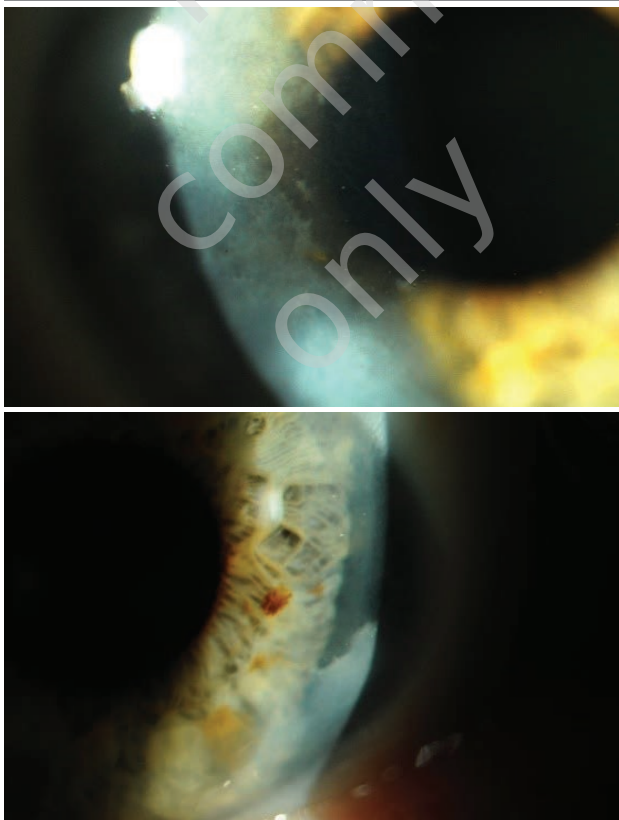
## A CASE REPORT

A 53-year-old woman diagnosed with PHSD based on clinical findings and optical coherence tomography (AS-OCT) of the anterior segment of the eye (fig. 1). Before treatment, the best corrected visual acuity (BCVA) for distance as assessed by the Snellen chart was:

- in the right eye (RE) 3/50 c.cor +10.50/-6.50 ax 18°
- in the left eye (LE) 5/10 c.cor +10.75/-3.00 ax 48°.

FIGURE 1

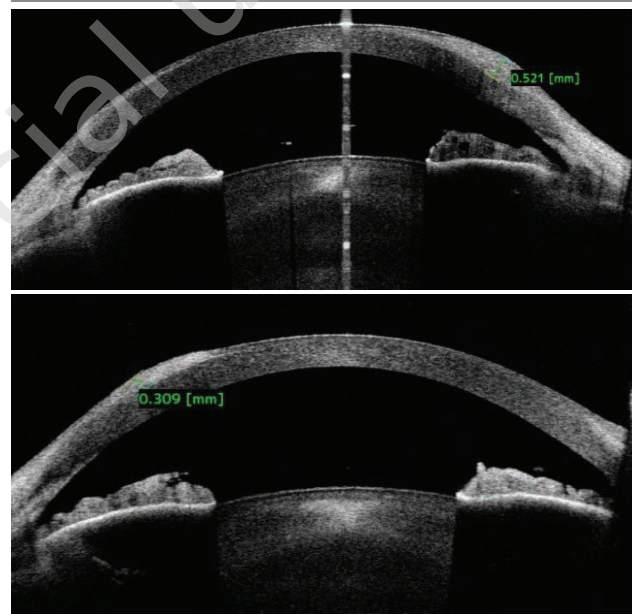
Right and left eye before surgery.



In the AS-OCT CASIA examination in the right eye, a subepithelial plaque with a maximum thickness of 521  $\mu\text{m}$  was found, and in the left eye with a maximum thickness of 309  $\mu\text{m}$ . The thickness of the epithelium was varied and determined by the variable thickness of the subepithelial fibrosis, i.e. the thinnest epithelium was in the place of the thickest fibrosis. Subepithelial fibrosis, according to the available literature [2], is a collagen plaque, which results in the disappearance of Bowman's layer in the area of degeneration (fig. 2).

FIGURE 2

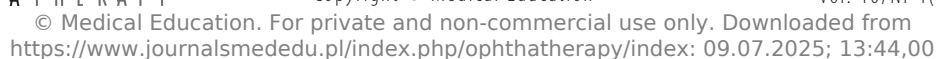
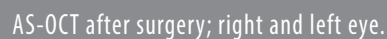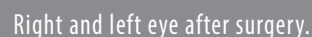AS-OCT before surgery; right and left eye.



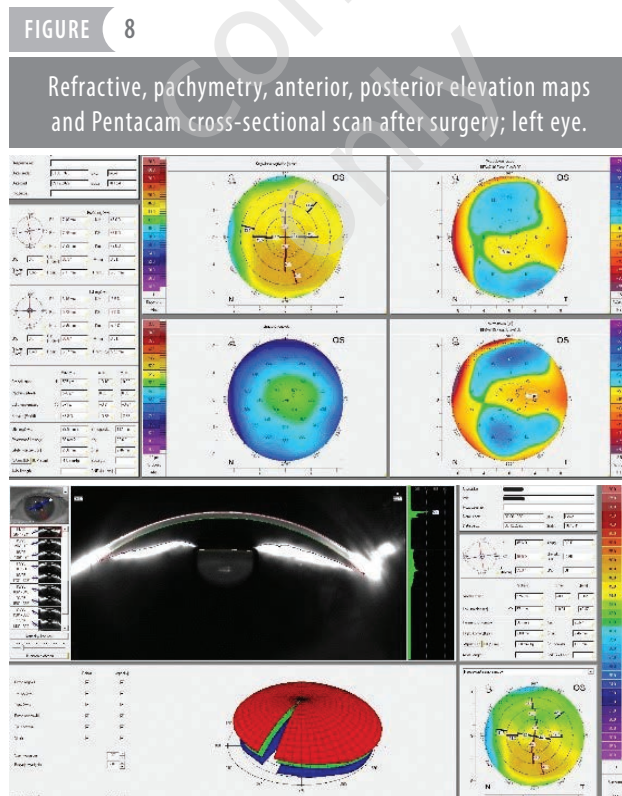
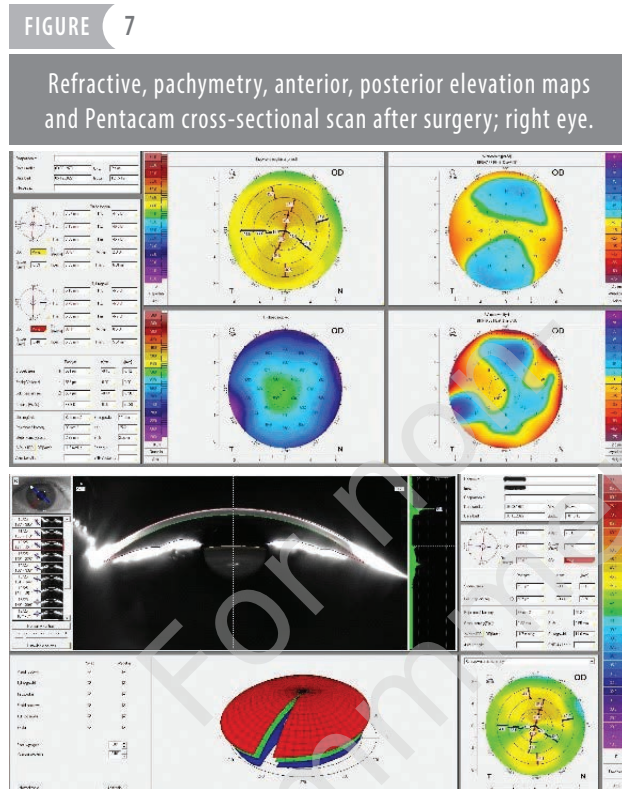
Pre-operative keratometry, performed with the Pentacam device, was: K1 32.7 D ax 17.9° and K2 46.0 D in RE, i.e. corneal astigmatism was 13.3 D (fig. 3), and in LE: K1 42.5 D ax 29.4° and K2 44.7 D, i.e. corneal astigmatism was 2.2 D (fig. 4). The patient underwent surgical treatment – superficial keratectomy with mechanical removal of degenerative plaques. The indication for the procedure was corneal astigmatism over 13 D in RE and approx. 3 D in LE, significant corneal irregularity with accompanying ocular surface disease, including unstable tear film. Postoperatively, topical anti-inflammatory therapy (0.1% dexamethasone), antibiotic therapy (levofloxacin) and intensive moisturizing therapy were administered (fig. 5). The use of mitomycin C or other antimetabolites during surgery is not recommended [2]. In postoperative AS-OCT CASIA, thanks to superficial keratectomy with mechanical removal of degenerative plaques in both eyes, the subepithelial plaque was not visualized and a regular corneal surface was obtained with the correct course of the epithelialization process (fig. 6).



Refractive, pachymetry, anterior, posterior elevation maps and Pentacam cross-sectional scan before surgery; right eye.



Postoperative keratometry, based on the Pentacam analysis, in RE, in the 5<sup>th</sup> month of observation, is: K1 44.6 D ax 173°; K2 46.9 D (corneal astigmatism 2.3 D) (fig. 7), and in LE, in the 3<sup>rd</sup> month of observation: K1 45.6 D ax 9.3°; K2 46.5 D (corneal astigmatism 0.9 D) (fig. 8).



After treatment, during the 5-month observation period of the RE and the 3-month observation of the LE, a significant improvement in visual acuity was obtained, and the best corrected visual acuity (BCVA) for distance, assessed according to the Snellen chart, is:

- in RE it is 5/8 c.cor +3.50/-1.00 ax 120° in the 5<sup>th</sup> month of observation
- in LE it is 5/6 c.cor +4.75/-1.00 ax 64° in the 3<sup>rd</sup> month of observation.

After the treatment, refractive astigmatism was reduced to about 1 D, corneal translucency improved, and there was no recurrence of the disease.

## DISCUSSION

PHSD is a rare disease entity of the cornea, occurring mainly in middle-aged women, most often idiopathic, although it is postulated that a smoldering, slight inflammatory process with low TGF- $\beta_1$  concentration may lead to the development of PHSD. The expression of the *HLA-B44* gene may also play a role in the development of the disease [2, 3]. In a publication by Järventausta et al., immunohistochemical analysis of the subepithelial plaque revealed non-specific changes of a non-inflammatory nature, absence of vessels in the fibrous tissue and the presence of three different types of fibroblasts: keratocyte-like cells positive for CD34, myofibroblasts which were positive for smooth muscle actin (SMA) and fibroblasts that were negative for CD34 and SMA. A small amount of CD68-positive macrophages was also observed [2].

The characteristic features are greyish-white fibrosis between the corneal epithelium and the Bowman's membrane, leading to thinning of the corneal epithelium and Bowman's membrane atrophy, often accompanied by focal, parailimbal neovascularization [4]. Initially, these lesions involve the perilimbal area and then gradually extend to the central part of the cornea, but without affecting the central part, and the lesion's border is sharply demarcated from the clear, transparent cornea. The lesions are bilateral, although they may vary in intensity in each eye.

A typical symptom is the deterioration of visual acuity, caused by the flattening of the central part of the cornea and the formation of regular or irregular astigmatism, usually above 2 D [2, 5]. The symptom is mild irritation of the ocular surface associated with an irregular corneal surface and instability of the tear film [6].

PHSD should be differentiated from Salzmann's nodular degeneration (SND) and progressive corneal degeneration, also non-inflammatory, usually idiopathic, although wearing contact lenses or surgery may be a trigger [7]. The characteristic symptoms of SND are blue-gray corneal nodules that vary in size, are diffuse, often occur in its central part



and do not reach the periphery of the cornea. In PHSD, on the contrary, the changes are located mainly on the periphery of the cornea and reach the limbus [3]. SND affects patients of all ages and, like PHSD, is more common in women [6]. PHSD and SND are distinct, clinically distinct disease entities with a greater inflammatory component in SND.

PHSD should be differentiated from Terrien's marginal degeneration, especially in the initial phase, when the disease process begins with corneal haze, i.e. the morphology and location of the lesion may resemble the image characteristic of PHSD. The lesions are usually bilateral, symmetrical and enlarge parallel to the limbus. Over time, a steep medial edge and a mildly running peripheral edge of the ulcer appear [8, 9]. In contrast to PHSD, Terrien's marginal degeneration is characterized by yellow lipid deposits and peripheral thinning of the cornea. Peripheral thinning of the cornea and the absence of a hyperreflective subepithelial structure are found in AS-OCT [1].

Some similarity to PHSD can be observed in the course of conjunctival intraepithelial neoplasia (CIN) due to peripheral opacities, however, this disease shows different clinicopathological characteristics. CIN is squamous cell carcinoma in situ, in which there are dysplastic epithelial cells.

Clinical signs are difficult to distinguish from PHSD and include irritation of the ocular surface and decreased visual acuity. Physical examination reveals well-circumscribed lesions as in PHSD, but unlike PHSD, corneal opacities are translucent, without subepithelial fibrosis, and associated blood vessels dilate in the direction of the lesion. The difference can also be seen on AS-OCT, which shows a pattern of hyperreflective, thickened epithelium and an abrupt transition to normal corneal epithelium. In the course of PHSD, the epithelium is normal or shows thinning over subepithelial fibrosis [9].

## CONCLUSIONS

PHSD is a clinical entity that should be considered in the differentiation of peripheral corneal opacities, ocular surface irritation, visual acuity deterioration, and astigmatism above 2 D. Modern diagnostic methods, such as AS-OCT and corneal tomography based on Scheimpflug images, make the diagnosis much easier, and superficial keratectomy with mechanical removal of degenerative plaques seems to be an effective method of treating PHSD.

*Figures: from the authors' own materials.*

## CORRESPONDENCE

**Prof. Dorota Wyględowska-Promieńska, MD, PhD**  
Department of Ophthalmology, University Clinical Center  
40-514 Katowice, ul. Ceglana 35  
e-mail: dwyględowska@sum.edu.pl

## ORCID

Dorota Wyględowska-Promieńska – ID – <http://orcid.org/0000-0001-5336-3460>  
Dorota Śpiewak – ID – <http://orcid.org/0009-0001-3596-7970>  
Mariola Dorecka – ID – <http://orcid.org/0000-0003-1768-9628>

## References

1. Gunzinger JM, Voulgari N, Petrovic A et al. Peripheral hypertrophic subepithelial corneal degeneration: clinical aspects related to in vivo confocal microscopy and optical coherence tomography. *Int Med Case Rep J*. 2019; 12: 237-41.
2. Järventausta PJ, Tervo TM, Kivela T et al. Peripheral hypertrophic subepithelial corneal degeneration – clinical and histopathological features. *Acta Ophthalmol*. 2014; 92(8): 774-82.
3. Raber IM, Eagle RC, Jr. Peripheral Hypertrophic Subepithelial Corneal Degeneration. *Cornea*. 2022; 41(2): 183-91.
4. Maust HA, Raber IM. Peripheral hypertrophic subepithelial corneal degeneration. *Eye Contact Lens*. 2003; 29(4): 266-9.
5. Jeng BH, Millstein ME. Reduction of hyperopia and astigmatism after superficial keratectomy of peripheral hypertrophic subepithelial corneal degeneration. *Eye Contact Lens*. 2006; 32: 153-6.
6. Gore DM, Iovieno A, Connell BJ et al. Peripheral hypertrophic subepithelial corneal degeneration: nomenclature, phenotypes, and long-term outcomes. *Ophthalmology*. 2013; 120: 892-8.
7. Farjo AA, Halperin GI, Syed N et al. Salzmann's nodular corneal degeneration clinical characteristics and surgical outcomes. *Cornea*. 2006; 25: 11-5.
8. Ding Y, Murri MS, Birdsong OC et al. Terrien marginal degeneration. *Surv Ophthalmol*. 2019; 64(2): 162-74.
9. Mandal S, Sachdeva G, Nagpal R et al. Early onset unilateral Terrien's marginal degeneration. *BMJ Case Rep*. 2022; 15(7): e248889.

For non-commercial use only

**Authors' contributions:**

Dorota Wyględowska-Promieńska: study conception and design, analysis and interpretation of results; Łukasz Drzyzga: study conception and design, data collection, analysis and interpretation of results, draft manuscript preparation; Dorota Śpiewak: data collection, analysis and interpretation of results, draft manuscript preparation; Mariola Dorecka: data collection, analysis and interpretation of results. All authors reviewed the results and approved the final version of the manuscript.

**Conflict of interest:**

None.

**Financial support:**

None.

**Ethics:**

The content presented in the article complies with the principles of the Helsinki Declaration, EU directives and harmonized requirements for biomedical journals.