

Band keratopathy – chelation or therapeutic photokeratectomy



Ismael Alsoubie¹, Aneta Pyza¹, Julia Kaczmarek¹,
Kinga Czarnacka¹, Dominika Prokop¹, Bartosz Kuźlik¹,
Alicja Chmura¹, Ada Pandey¹, Małgorzata Gawlak¹,
Bartłomiej Żaczek¹, Katarzyna Sajak-Hydzik^{1,2}, Ilona Pawlicka^{1,2},
Agnieszka Piskorz^{1,2}, Maciej Kozak^{1,2}, Anna Maria Roszkowska²

¹ Faculty of Medicine and Health Sciences, Andrzej Frycz Modrzewski Academy in Krakow
Dean: Prof. KAAFM Janusz Ligeza, PhD

² Clinical Ophthalmology Department, Section „A”, Provincial Ophthalmological Hospital in Krakow
Director: Maciej Kozak, MD, PhD

HIGHLIGHTS

Band keratopathy can significantly impair vision. The chelation treatment and phototherapeutic keratectomy effectively remove the deposits that cause the disease.

ABSTRACT

Corneal degeneration changes corneal shape and causing its translucency disappear. The division of corneal degeneration is made according to the type deposited in its layer. Among the factors causing keratopathy, the following can be mentioned: iron, collagen, hemosiderins, and calcium salts, the last ones cause band keratopathy. This feature is characteristic of the deposition of opacities in the superficial layers of the cornea. In the treatment of band keratopathy, ethylenediaminetetraacetic acid chelation and excimer laser phototherapeutic keratectomy are discussed.

Key words: band keratopathy, calcium deposits, EDTA chelation, phototherapeutic keratectomy, excimer laser, corneal degeneration, ethylenediaminetetraacetic acid

INTRODUCTION

In the optical system of the eye the cornea is the first center focusing light rays. It performs its optical function thanks to correct size, smooth surface, even and correct convex curvature, and complete transparency [1]. The cornea consists of five layers: the epithelium, the anterior limiting membrane (the so-called Bowman's membrane), where calcium crystals are most often deposited, the stroma of the cornea (the so-called corneal stroma), the posterior limiting lamina (Descemet's membrane) and the endothelium [2].

BAND KERATOPATHY

Band keratopathy is a chronic, degenerative disease of the cornea, which may occur secondary to chronic inflammation of the eye, e.g. in anterior uveitis, in patients with glaucoma, in the case of atrophic eyes and those filled with silicone oil [3]. It can also occur in patients with disturbed calcium and phosphate metabolism, when there is an increase in the level of calcium in the body, e.g. in the case of hyperparathyroidism, sarcoidosis, lupus, or chronic renal failure [4]. The above-mentioned corneal degeneration is also found in patients after a posterior vitrectomy.

This corneal degeneration is caused by the deposition of calcium hydroxyapatite, mainly at the level of the basement membrane, Bowman's layer, and in the superficial part of the cornea, causing visual impairment [5, 6] (fig. 1). At the initial stages of the disease, the course is often asymptomatic. However, as the disease progresses, visual acuity decreases and significant impairment occurs, which is the result of the deposition of gray-white opacities along the palpebral fissure [3, 7]. In addition, superficial damage to the eyeball can cause pain and lead to corneal ulceration [3, 7].

Treatment

The main goal of treating band keratopathy is to remove calcium deposits and restore smoothness and transparency to the cornea. Various methods are used in the treatment of band keratopathy, including ethylenediaminetetraacetic acid (EDTA) chelation and excimer laser phototherapeutic keratectomy (PTK) [8].

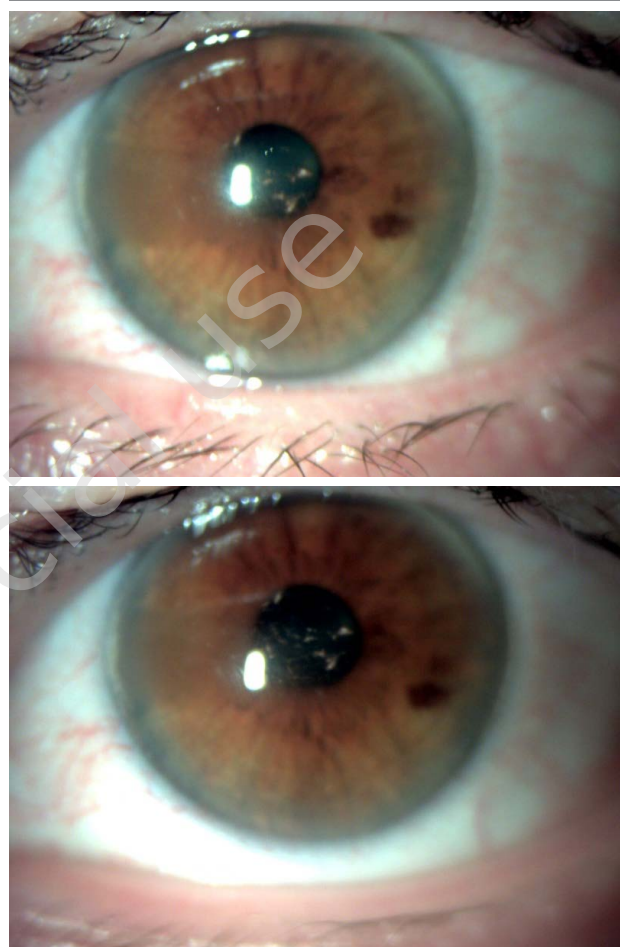
EDTA acid is widely used both in the food industry (as a food additive), cosmetics, pharmaceutical and medical industries, where it is used as an anticoagulant in blood collection tubes. It is also used in ophthalmology as the most common method of treating band keratopathy [9].

EDTA is a metal ion chelator. Thanks to it, it is possible to capture calcium deposits that are present in the superficial layers of the cornea in the course of band keratopathy.

The chelation procedure is performed in the operating block, under local anesthesia. A palpebral hiatus is used to keep the eyelid open, and then the operator removes

FIGURE 1

Band keratopathy – before EDTA chelation treatment.



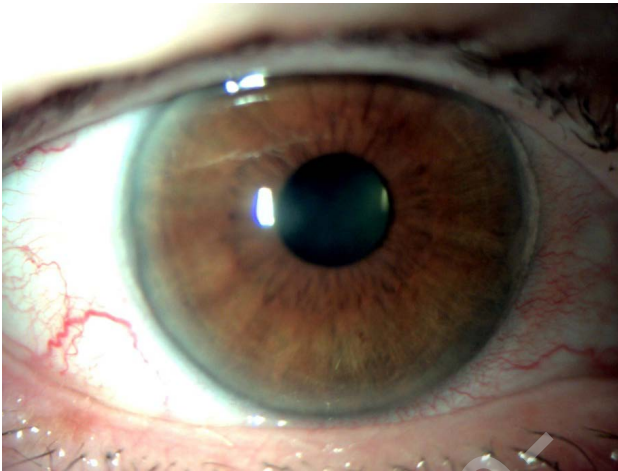
the corneal epithelium in the place of its opacity. In the next stage of the procedure, a 2–4% solution of EDTA is applied to the surface of the corneal opacity for several minutes. This is done with a cellulose sponge or a sterile cotton applicator. The calcium plaques are then scraped off. If the turbidity is not completely removed, EDTA is re-applied. This is done until the patient's cornea is clear [10, 11] (fig. 2).

Najjar et al. in their retrospective study showed that the EDTA chelation treatment improves visual comfort, eliminates the symptoms of band keratopathy, and improves visual acuity.

56 patients (65 eyes) treated with EDTA chelation were qualified for the study. Nine people were excluded from this group during the study. Each of the patients complained of at least one ailment resulting from band keratopathy. After the treatment, 98% of patients achieved partial improvement or complete resolution of their symptoms. Only one patient (2%) experienced complications after the procedure in the form of a permanent loss of the epithelium and then a corneal ulcer. The average healing time was 8 days. In

FIGURE 2

Band keratopathy – after EDTA chelation treatment.



35.2% of eyes visual acuity significantly improved, in 7.8% of eyes visual acuity deteriorated, while in 56.9% visual acuity did not change or improved slightly [11].

In a retrospective analysis of the medical history of patients treated with EDTA chelation for band keratopathy at Glasgow University Hospital between 2009 and 2015, Al-Hity et al. showed that the procedure is a safe and effective treatment, but has a moderate risk of recurrence. Among the 89 analyzed cases, visual acuity did not change or slightly improved in 79.8%, while in 13.5% it significantly improved [7]. Chelation with EDTA removes only the calcium precipitated on the cornea but does not remove the cause of its precipitation. Therefore, there is a risk of symptomatic band keratopathy recurring. Al-Hity et al. in their study assessed the risk of recurrence at 28.1%, with only 16% of them requiring repeated EDTA chelation. Whereas Najjar et al. estimated the risk of recurrence at 17.8% [7, 11].

Kobayashi et al. examined 24 eyes treated with EDTA chelation for band keratopathy. According to their analysis, visual acuity improved significantly. In all cases, partial or complete elimination of eye complaints related to the disease was achieved. The procedure did not significantly change the curvature of the cornea [10].

Excimer laser PTK is one of the surgical methods of treating corneal pathologies, such as degeneration or opacity, erosions, dystrophies or scars resulting from injuries or corneal inflammation. It is a procedure performed with an excimer laser, which consists of the removal and modeling of the superficial layers of the cornea (epithelium and part of the substantia). During this procedure, there is no interference in the deeper layers of the cornea [12]. The PTK treatment improves visual acuity and reduces surface irregularities and pain. It is also effective in the treatment of recurrent erosions resistant to pharmacological treatment or in the removal of superficial corneal scars [13, 14].

Wei et al. described the use of therapeutic PTK in band keratopathy after retinoblastoma treatment. Thanks to this procedure, visual acuity improved, and the correct surface and transparency of the cornea were restored. This was due to the removal of calcium deposits causing corneal opacity. Additionally, no postoperative complications were observed in the patient [15].

In another retrospective study presented by Qian et al., a group of people who were treated with CT during the treatment of band keratopathy was assessed. It was caused by filling the eyeball with silicone oil, which resulted in some patients suffering from chronic uveitis. This inflammation was the cause of the pain and discomfort of the eyeball. Based on the results of the study, it was shown that all patients experienced a partial or complete regression of symptoms and improved visual acuity by eliminating corneal opacities. In addition, during the observation of patients after the use of CT, no complications or recurrence of symptoms were found [16].

In another study, Sharma et al. conducted a retrospective analysis of band keratopathy caused by silicone oil in the eyeball. In the examined patients, there was also a loss of visual acuity due to opacity and the formation of an irregular surface of the cornea. This was due to the deposition of calcium deposits. PTK was used for therapeutic purposes. Significant improvement in corneal transparency has been reported. Isolated recurrences were noted, which were corrected by the re-operation of PTK. No postoperative complications were observed in this group of patients [17].

Treatment comparison

The first important thing to note when comparing the two methods is the cost and availability of the treatment method. Access to PTK is usually limited, and the cost often exceeds the price of chelation with EDTA several times. Histological analyses have shown that band keratopathy is primarily the result of calcium deposits, but other deposits can also form. When we are dealing with any material other than calcium deposits, the effectiveness of using EDTA decreases. However, the effectiveness of PTK does not depend on the composition of deposits in the cornea [16, 18]. Another important aspect is the postoperative smoothness of the corneal surface. During the chelation procedure, before applying EDTA, the operator manually removes the epithelium from the cornea in the place of its opacity. This is the so-called manual superficial keratectomy, which does not provide a regular eye surface. Meanwhile, PTK is a method characterized by high precision that allows the removal of corneal tissues without affecting the adjacent tissues. In addition, PTK is a procedure by which we can control the depth as well as the area of excimer ablation. This is related to the minimization of side effects [18].

It also seems that PTK reduces the number of recurrences and postoperative complications. There is also a higher percentage of patients who have improved visual acuity after PTK compared to EDTA chelation.

Summing up, it can be said that each of these procedures has its advantages and disadvantages, and their combination can be very beneficial even in very difficult cases. Therefore, at this point, it is worth mentioning the article by Spadea et al., in which the activities consisting in complementing each other of these methods were presented. The main purpose of EDTA chelation is to remove calcium deposits from the superficial layers of the cornea. Therefore, some sediments of other origins can be observed only after using the chelation method. This may cause after using this method, the surface of the cornea is not smooth and requires further treatment. In turn, PTK is a method

that is characterized by high accuracy in the ablation of target layers compared to superficial keratectomy performed manually. Thanks to this, the surface of the cornea is regular. It is believed that the combined treatment of EDTA and PTK is a new, effective, and safe method in band keratopathy [19].

CONCLUSION

The paper discusses band keratopathy using treatment methods such as EDTA and PTK chelation. The goal of treating this disease is to remove calcium deposits and restore a smooth corneal surface. Thanks to this, vision is improved and ophthalmological problems are reduced. In addition, both methods of combating the disease were compared by analyzing the available publications.

CORRESPONDENCE

med. student Ismael Alsoubie

Faculty of Medicine and Health Sciences, Andrzej Frycz Modrzewski Academy in Krakow
30-705 Kraków, ul. Gustawa Herlinga-Grudzińskiego 1
e-mail: ismaelalsoubie@gmail.com

ORCID

Ismael Alsoubie – ID – <http://orcid.org/0000-0002-0974-3025>
Aneta Pyza – ID – <http://orcid.org/0009-0000-5318-1368>
Julia Kaczmarek – ID – <http://orcid.org/0009-0001-2268-6547>
Kinga Czarnacka – ID – <http://orcid.org/0000-0002-6889-6507>
Alicja Chmura – ID – <http://orcid.org/0000-0003-0733-1542>
Dominika Prokop – ID – <http://orcid.org/0000-0001-7318-7716>
Ada Pandey – ID – <http://orcid.org/0000-0001-9467-1005>
Bartłomiej Żaczek – ID – <http://orcid.org/0000-0002-9184-3649>
Bartosz Kuźlik – ID – <http://orcid.org/0000-0001-8028-5525>
Małgorzata Gawlak – ID – <http://orcid.org/0000-0003-4573-1379>
Maciej Kozak – ID – <http://orcid.org/0000-0001-7993-2588>
Ilona Pawlicka – ID – <http://orcid.org/0000-0003-1556-7678>
Katarzyna Sajak-Hydzyk – ID – <http://orcid.org/0000-0002-1973-2717>
Agnieszka Piskorz – ID – <http://orcid.org/0000-0003-4553-0497>
Anna Maria Roszkowska – ID – <http://orcid.org/0000-0002-8083-3437>

References

1. Niżankowska H. Okulistyka. Podstawy kliniczne. PZWL, Warszawa 2007.
2. Pogrzebielski A. Budowa narządu wzroku. Medycyna Praktyczna. <https://www.mp.pl/pacjent/okulistyka/zdroweoczy/68655,budowa-narzadu-wzroku> (access: 30.06.2023).
3. Kwon YS, Song YS, Kim JC. New treatment for band keratopathy: superficial lamellar keratectomy, EDTA chelation and amniotic membrane transplantation. *J Korean Med Sci.* 2004; 19(4): 611-5. <http://doi.org/10.3346/jkms.2004.19.4.611>.
4. Wiedemann J, Cursiefen C. Bandkeratopathie bei ektopter Vitamin-D-Produktion bei Sarkoidose [Band keratopathy in ectopic vitamin D production in sarcoidosis]. *Ophthalmologie.* 2022. <http://doi.org/10.1007/s00347-022-01679-3>.
5. Ferda D, Mrukwa-Kominek E. Powikłania rogówkowe po zabiegu witrektomii przez pars plana. *Okulistyka po Dyplomie.* 2013; 3(3): 23-5.
6. Rekomendacja nr 123/2013 z dnia 16 września 2013 r. Prezesa Agencji Oceny Technologii Medycznych w sprawie zasadności wydawania zgód na refundację produktu leczniczego Ophthalosiloxane (Dimethicone), krople do oczu we wskazaniach: jaskra w zaawansowanym stadium, keratopatia oczna. https://bipold.aotm.gov.pl/assets/files/zlecenia_mz/2013/159/REK/RP_123_2013_ophtasiloxane.pdf (access: 30.06.2023).
7. Al-Hity A, Ramaesh K, Lockington D. EDTA chelation for symptomatic band keratopathy: results and recurrence. *Eye (Lond).* 2018; 32(1): 26-31. <http://doi.org/10.1038/eye.2017.264>.
8. Jhanji V, Rapuano CJ, Vajpayee RB. Corneal calcific band keratopathy. *Curr Opin Ophthalmol.* 2011; 22(4): 283-9. <http://doi.org/10.1097/ICU.0b013e3283477d36>.
9. Narvaez J, Chang M, Ing J et al. Simplified, Readily Available Method for the Treatment of Band Keratopathy With Ethylenediaminetetraacetic Acid. *Cornea.* 2021; 40(10): 1360-2. <http://doi.org/10.1097/ICO.0000000000002635>.
10. Kobayashi W, Yokokura S, Hariya T et al. Two percent ethylenediaminetetraacetic acid chelation treatment for band-shaped keratopathy, without blunt scratching after removal of the corneal epithelium. *Clin Ophthalmol.* 2015; 9: 217-23. <http://doi.org/10.2147/OPHTH.S75938>.
11. Najjar DM, Cohen EJ, Rapuano CJ et al. EDTA chelation for calcific band keratopathy: results and long-term follow-up. *Am J Ophthalmol.* 2004; 137(6): 1056-64. <http://doi.org/10.1016/j.ajo.2004.01.036>.
12. Nagpal R, Maharana PK, Roop P et al. Phototherapeutic keratectomy. *Surv Ophthalmol.* 2020; 65(1): 79-108. <http://doi.org/10.1016/j.survophthal.2019.07.002>.
13. Wilson SE, Marino GK, Medeiros CS et al. Phototherapeutic Keratectomy: Science and Art. *J Refract Surg.* 2017; 33(3): 203-10. <http://doi.org/10.3928/1081597X-20161123-01>.
14. Deshmukh R, Reddy JC, Rapuano CJ et al. Phototherapeutic keratectomy: Indications, methods and decision making. *Indian J Ophthalmol.* 2020; 68(12): 2856-66. http://doi.org/10.4103/ijo.IJO_1524_20.
15. Wei R, Li M, Yang W et al. Case Report: Phototherapeutic Keratectomy for Band Keratopathy Secondary to Chemo-Laser-Cryotherapy for Retinoblastoma. *Front Med (Lausanne).* 2021; 8: 668762. <http://doi.org/10.3389/fmed.2021.668762>.
16. Qian Y, Zhao P, Li H et al. Transepithelial phototherapeutic keratectomy for the treatment of severe band keratopathy. *Int Ophthalmol.* 2020; 40(10): 2469-74. <http://doi.org/10.1007/s10792-020-01574-3>.
17. Sharma N, Mannan R, Sinha R et al. Excimer laser phototherapeutic keratectomy for the treatment of silicone oil-induced band-shaped keratopathy. *Eye Contact Lens.* 2011; 37(5): 282-5. <http://doi.org/10.1097/ICL.0b013e31821269f1>.
18. Stewart OG, Morrell AJ. Management of band keratopathy with excimer phototherapeutic keratectomy: visual, refractive, and symptomatic outcome. *Eye (Lond).* 2003; 17(2): 233-7. <http://doi.org/10.1038/sj.eye.6700327>.
19. Spadea L, Giannico MI, Iannaccone A et al. Excimer laser-assisted phototherapeutic keratectomies combined to EDTA chelation for the treatment of calcific band keratopathy. *Eur J Ophthalmol.* 2022; 32(1): NP42-NP46. <http://doi.org/10.1177/1120672120969033>.

Authors' contributions:

All authors have equal contribution to the paper.

Conflict of interest:

None.

Financial support:

None.

Ethics:

The content presented in the article complies with the principles of the Helsinki Declaration, EU directives and harmonized requirements for biomedical journals.