

The use of modern monofocal „plus” lenses in the cataract surgery



**Bartłomiej Markuszewski^{1,2}, Sabina Ziółkowska^{1,3},
Anna Markuszewska¹, Edward Wylęgała²**

¹ Wrocław Ophthalmology Center
Head: Jolanta Markuszewska-Żelbomska, MD, PhD

² Chair and Clinical Department of Ophthalmology, School of Medical Science in Zabrze,
Medical University of Silesia in Katowice
Head: prof. Edward Wylęgała, MD, PhD

³ Department of Ophthalmology, University Clinical Hospital in Wrocław
Head: prof. Marta Misiuk-Hojto, MD, PhD

HIGHLIGHTS

Pseudo-lens monovision is a good way to be more free from the required spectacle correction.

ABSTRACT

The use of monofocal “plus” lenses allows for greater independence from spectacle correction than monofocal lenses. Studies show good visual function of patients at almost all distances and minimal presence of undesirable optical artifacts in the postoperative refraction setting of bilateral emmetropia and monovision. The paper presents the use of monofocal “plus” lenses in the monovision setting.

Key words: cataract, monovision, monofocal plus, extended depth of focus

INTRODUCTION

Lens replacement surgery is medical and elective procedure for vision correction. The medical indications for lens surgery are ocular pathologies, i.e., cataract [1, 2], primary or secondary glaucoma, a history of ocular trauma that can cause injury to the lens and its ligaments, and congenital anomalies of the anterior segment of the eye. The main goal of treatment is to eliminate the patient's visual impairment. In rare situations, such as primary angle-closure glaucoma, the clear lens is often removed despite the lack of vision deterioration. In refractive lens exchange, the patient's natural lens is replaced with an artificial intraocular lens, which usually leads to a significant vision improvement. Patients who have undergone refractive lens surgery, often with pre-existing visual impairments, do not need glasses for far and intermediate distances, but they may need spectacle correction for near distances [3]. Elective refractive procedures are gaining popularity because people want to be free of additional spectacle correction for refractive errors or presbyopia. The first systematically conducted operations of refractive lens exchange were carried out in the last decades of the 19th century by the Polish ophthalmologist Wincenty Fukała in Vienna [4], and today are increasingly popular thanks to the availability of advanced technology lenses. Currently, refractive lens exchange provides clear vision at most distances without additional spectacle correction [5].

TYPES OF INTRAOCULAR LENSES AND ABERRATIONS OF THE EYE'S OPTICAL SYSTEM

Currently available types of intraocular lenses include modern monofocal foldable lens, extended depth-of-focus (EDOF) lens, and multifocal lens. Each one has advantages and limitations. A monofocal lens has one, usually far, focusing distance. EDOF lens, by alternating positive and negative spherical aberrations, stretches the focal point of the retina, which in most patients increases independence from additional spectacle correction without significant loss of mesopic contrast sensitivity. Multifocal lenses provide clear focus at near, intermediate and far distances, with relatively less light directed to the focused image, which results in a reduced contrast sensitivity and poorer visual function when the amount of available light is limited [6–8]. We can divide night-time dysfotopsia into: halo, which is attributed to the optics of the lens, and starburst, glare and flare, which are associated with postoperative refractive error or ocular surface diseases [9]. The multifocality is achieved by inducing optical diffraction and division into segments that handle light differently. Multifocal lenses are widely used and allow good, spectacle-free vision at far, intermediate and near distances [10]. On the other hand, they are expensive [11], targeted only for a narrow group

of patients [12], and require a neuroadaptation period [13]. Lenses with combined optical technologies are also available on the market. Spherical corneal aberrations depend on patient's age. In 90% of cases, corneal spherical aberration is +0.27 μm with a high standard deviation of +0.10 μm . In the remaining 10%, spherical aberration is negative. The young lens compensates for the positive spherical aberrations. With ageing, the lens loses this property and contributes to positive spherical aberrations causing worsening of the optical performance. Contrast sensitivity is best in patients in their 20s and 30s and deteriorates with age. Spherical aberration comes into play when pupils are greater than 4 mm. Therefore, it has the most impact under mesopic and scotopic conditions [14].

Monofocal „plus”

Monofocal intraocular lens is characterized by the frequent presence of negative spherical aberrations that compensate for the cornea aberrations. Clear vision at one point of focus is possible only if postoperative refraction correction has been achieved. Monofocal “plus” lenses have spherical aberrations that increase depth of field from +1.25 to +1.50 D. Such amplification provides clear vision at intermediate distances (e.g., screen, car speedometer). With the first use of pseudophakic monovision in 1984 [15] and targeting the postoperative refraction in the dominant eye and offset in the non-dominant eye from -1.0 D to -1.50 D, the functional depth of focus was extended, and no additional spectacle correction is necessary [16–20]. However, monovision also has some disadvantages. Spatial vision and stereopsis are possible if both eyes can focus at the same distance [21].

INTRAOCULAR LENS SELECTION

Personalized selection process of the right IOL is important to address patient's visual needs and expectations. Due to the ubiquitous use of computers and smartphones, as well as the increased incidence of cataract at a young age, there is a need for functional vision at intermediate distances [22, 23]. It is important to assess postoperative vision and determine the refractive target before the surgical treatment. During qualification, the doctor should discuss with the patient aspects of functional vision for daily activities, such as walking on uneven surfaces, climbing stairs, driving, work, using a computer or smartphone, or reading [24].

RAYONE EMV LENS

Rayner RayOne EMV lens (enhanced monovision) is a monovision lens with an extended depth of focus. RayOne EMV uses the same platform of other Rayner lenses. It is 1-piece, hydrophilic acrylic IOL with 26% hydration, and Abbe number of 56. Developed in collaboration with Pro-

fessor Graham Barrett, RayOne EMV's truly non-diffractive optic utilizes positive spherical aberration to provide an increased depth of focus up to +1.50 D (like spectacles). RayOne EMV lens has positive spherical aberration at the center of its optic blended edge region to maintain visual acuity under mesopic conditions [25]. RayOne EMV is a non-diffractive IOL without unwanted photic phenomena. Limited spherical aberrations complement natural corneal aberrations by increasing depth of focus without inducing halos or glare, as in the case of standard monofocal lenses.

The use of IOL with a refractive monovision in patients with bilateral cataract ensures good vision at any distance without loss of intermediate focus points. With a depth of focus of +1.50 D, patients get a smooth transition zone, significantly different from that of standard monofocal lenses (fig. 1). Due to binocular emmetropia, patients achieve depth of focus to intermediate distances within a functional range of 60–80 cm. The lens is preloaded into a disposable injector with delivery through a 2.2 mm or a larger incision. The injector is equipped with a patented lock and roll technology that allows for the smoother rolling when delivering the lens.

STUDY GROUP WITH RAYONE EMV LENSES (RAYNER)

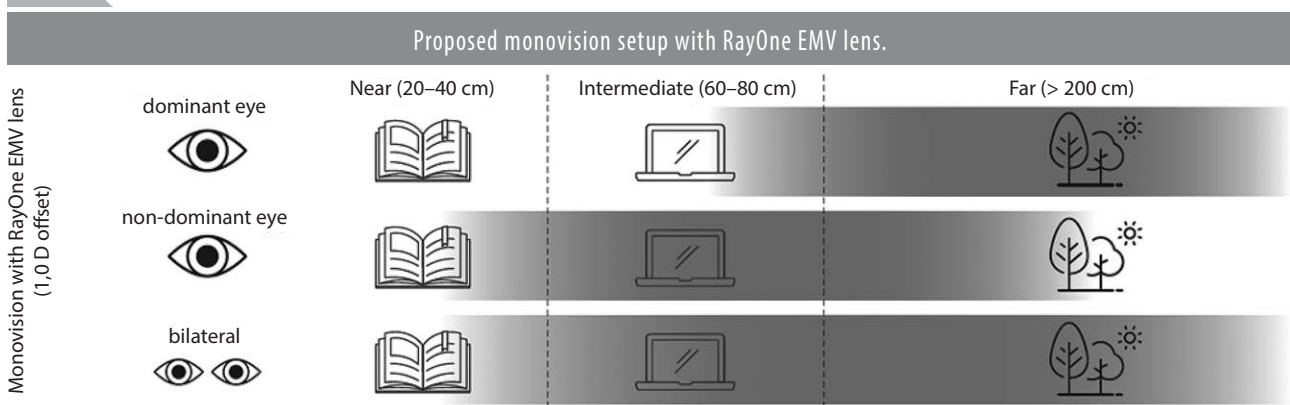
A total of 30 patients were operated on an outpatient basis due to the presence of bilateral cataracts with vision deterioration below 0.6 on the Snellen chart. Patients were divided into two equal groups. In Group 1, postoperative refraction was targeted for emmetropia. In Group 2, postoperative refraction was targeted for monovision, with -1.0 D target refraction in the non-dominant eye. The aim of the study was to determine potential differences in far, intermediate and near vision in patients with Rayner RayOne EMV lens with an emmetropic and monovision targets. The study was conducted according to the Declara-

tion of Helsinki and was approved by the local bioethics committee (6/PNDR/2021). Patient biometrics were obtained by using the Tomey OA-2000 and Bausch & Lomb Ace (Heidelberg Engineering Anterior). The power of IOLs was calculated using Barrett universal formula. The inclusion criteria for the post-operative analysis was the presence of cataracts, the absence of macular and optic nerve disease, corneal astigmatism of less than 1 D, no corneal disease or scarring. An additional exclusion criterion was previous eye surgery. Follow-ups were performed 2 weeks after surgical treatment. Patients were operated by a single surgeon. They underwent routine phacoemulsification with intraocular lens implantation. The eyes were operated on a month apart. All patients received the same premedication regimen and postoperative drugs, i.e., levofloxacin eye drops 3 days prior to surgery and up to 7 days postoperatively, 0.1% dexamethasone for 14 days postoperatively, and diclofenac up to 21 days postoperatively. In addition, regular use of moisturizing eye drops with hyaluronic acid and trehalose was recommended.

RESULTS

In both groups, the mean refractive error in spherical equivalent improved from -1.75 (± 2.45) to 0.35 (± 0.23) ($p < 0.001$ for all parameters). The mean uncorrected binocular visual acuity in Group 1 and 2 did not differ and was 0.01 LogMAR ($p = 0.654$). There were no differences in uncorrected binocular visual acuity in patients at intermediate distances, i.e., 66 cm. According to the Jaeger scale, visual acuity in Group 1 and 2 was J2 ($p = 0.152$). No statistical difference was observed in uncorrected binocular near visual acuity at 40 cm ($p = 0.316$). In Group 1, the value was J2.71, and in Group 2 J2.14. Adverse events, dislocated or tilted IOLs were not reported in the postoperative follow-up. There was also no evidence of posterior lens capsule opacification, although the postoperative follow-up was short.

FIGURE 1



QUALIFICATION FOR LENS IMPLANTATION

Case 1.

A patient in her 70s, referred from an ophthalmology outpatient clinic, presented to qualification for the bilateral cataract removal. In the past she had bilateral nuclear cataract but had very good vision in both eyes and used glasses only for reading. Therefore, we can assume that the patient did not have amblyopia, and her refractive errors were similar in both eyes, close to emmetropia. At the time of presentation, the patient had pseudomyopia associated with the presence of a nuclear cataract in the left eye. The advancement of the cataract in the right eye has not changed its refraction. The other structures of the eye showed no pathology, and the potential for postoperative vision was assessed as high. The patient was referred by her ophthalmologist who did not notice any significant vision deterioration. The patient even claimed that her near vision had improved. The patient did not drive nor spend much time reading. Therefore, we performed Rayner RayOne EMV implantation with a planned postoperative 1 D monovision and a left non-dominant eye set for near. The right eye was operated on later and targeted for emmetropia. Phacoemulsification with intraocular lens (IOL) implantation was performed. Ultimately, the goal of refraction correction was achieved. With binocular vision, the patient achieved full far and near visual acuity (40–60 cm). The optotype contrast test showed no difference in terms of mesopic and photopic contrast sensitivity. In the post-operative questionnaire, the patient reported no need to wear glasses all day, only for high-precision tasks, such as needle threading. The patient reported no additional optical artifacts, was satisfied with her vision and with the fact that she did not need spectacle correction for most of her daily activities.

Case 2.

A 66-year-old patient presented to the qualification vis-

it preceding cataract removal. The patient had cataracts in both eyes with symmetrical hyperopia. He was active, travelling a lot, skiing, going to the movies and theater, and driving. During the qualification examination, the patient admitted that he did not want to wear glasses but maintain the quality of vision at far distances. Rayner RayOne EMV IOLs with a postoperative refractive target of bilateral emmetropia were recommended. The patient achieved full visual acuity at far distances and good visual acuity at intermediate distances. The patient does not wear glasses for computer work or to use smartphone but uses an additional spectacle correction of +1.50 D for reading. The patient reported no additional optical artifacts and expressed satisfaction with his vision allowing him to stay active.

CONCLUSIONS

Even though foldable IOLs have been used since the 1980s, there is still an ongoing debate about which IOL is best for the patient. A monofocal IOL with EDOF is a good option that does not induce unwanted optical effects. The Rayner RayOne EMV study group achieved good uncorrected binocular visual acuity, particularly at far and intermediate distances. In the monovision group, near vision was better, but this result was not statistically significant. However, further research on larger group of patients wearing IOLs for a longer period of time is necessary to confirm these results. More attention should be paid to the patient-defined outcome of IOL implementation. Patients with pseudomyopia as a result of nuclear cataract that is particularly severe in one eye, are naturally good candidates for the induction of monovision by Rayner RayOne EMV. Because of cataract, they have already experienced monovision, its benefits and limitations, so they can make a more informed decision. On the other hand, patients requiring good spatial vision, particularly at far distances, seem better candidates for binocular emmetropia.

CORRESPONDENCE

Bartłomiej Markuszewski, MD
Wrocław Ophthalmology Center
50-231 Wrocław, ul. Zakładowa 11
e-mail: b.markuszewski@wco.com.pl

ORCID

Bartłomiej Markuszewski – ID – <http://orcid.org/0000-0002-5733-5923>
Sabina Ziółkowska – ID – <http://orcid.org/0000-0003-2859-5803>
Anna Markuszewska – ID – <http://orcid.org/0009-0001-7662-304X>
Edward Wylęgała – ID – <http://orcid.org/0000-0002-6707-5790>

References

1. Bourne RR, Stevens GA, White RA et al. Causes of vision loss worldwide, 1990-2010: a systematic analysis. *Lancet Glob Health*. 2013; 1(6): e339-49.
2. Asbell PA, Dualan I, Mindel J et al. Age-related cataract. *Lancet*. 2005; 365(9459): 599-609.
3. Marcos S, Barbero S, Jiménez-Alfaro I. Optical quality and depth-of-field of eyes implanted with spherical and aspheric intraocular lenses. *J Refract Surg*. 2005; 21(3): 223-35.
4. Schmidt D, Grzybowski A. Fukala (1847-1911) and the early history of clear lens operations in high myopia. *Saudi J Ophthalmol*. 2013; 27: 41-6.
5. Kaweri L, Wavikar C, James E et al. Review of current status of refractive lens exchange and role of dysfunctional lens index as its new indication. *Indian J Ophthalmol*. 2020; 12: 2797-803.
6. Black S. A clinical assessment of visual performance of combining the TECNIS((R)) Symphony Extended Range of Vision IOL (ZXR00) with the +3.25 D TECNIS Multifocal 1-piece IOL (ZLB00) in subjects undergoing bilateral cataract extraction. *Clin Ophthalmol*. 2018; 12: 2129-36.
7. Venter JA, Pelouskova M, Collins BM et al. Visual outcomes and patient satisfaction in 9366 eyes using a refractive segmented multifocal intraocular lens. *J Cataract Refract Surg*. 2013; 39(10): 1477-84.
8. Cochener B, Lafuma A, Khoshnood B et al. Comparison of outcomes with multifocal intraocular lenses: A meta-analysis. *Clin Ophthalmol*. 2011; 5: 45.
9. Auffarth G. Enhanced monofocals: minimising dysphotopsia and maximising visual quality. *Eurotimes*. 2021; June(Suppl): 3-4.
10. Salerno LC, Tiveron MC Jr, Alio JL. Multifocal intraocular lenses: Types, outcomes, complications and how to solve them. *Taiwan J Ophthalmol*. 2017; 4(7): 179-84.
11. Hu JQ, Sarkar R, Sella R et al. Cost-effectiveness analysis of multifocal intraocular lenses compared to monofocal intraocular lenses in cataract surgery. *Am J Ophthalmol*. 2019; 208: 305-12.
12. Braga-Mele R, Chang D, Dewey S et al. Multifocal intraocular lenses: relative indications and contraindications for implantation. *J Cataract Refract Surg*. 2014; 40: 313-22.
13. de Vries NE, Webers CA, Touwslager WR et al. Dissatisfaction after implantation of multifocal intraocular lenses. *J Cataract Refract Surg*. 2011; 37: 859-65.
14. Al-Sayyari TM, Fawzy SM, Al-Saleh AA. Corneal spherical aberration in Saudi population. *Saudi J Ophthalmol*. 2014; 28(3): 207-13.
15. Boerner CF, Thrasher BH. Results of monovision correction in bilateral pseudophakes. *J Am Intraocul Implant Soc*. 1984; 10: 49-50.
16. Zhang F, Sugar A, Jacobsen G et al. Visual function and spectacle independence after cataract surgery: Bilateral diffractive multifocal intraocular lenses versus monovision pseudophakia. *J Cataract Refract Surg*. 2011; 37: 853-8.
17. Labiris G, Giarmoukakis A, Patsiamanidi M et al. Mini-monovision versus multifocal intraocular lens implantation. *J Cataract Refract Surg*. 2015; 41: 53-7.
18. Chen M, Atebara NH. A comparison of a monofocal Acrysoft IOL using the “blended monovision” formula with the multifocal array IOL for glasses independence after cataract surgery. *Ann Ophthalmol*. 2007; 39: 237-40.
19. Wilkins MR, Allan BD, Rubin GS et al.; Moorfields IOL Study Group. Randomized trial of multifocal intraocular lenses versus monovision after bilateral cataract surgery. *Ophthalmology*. 2013; 120(12): 2449-55.
20. Mahrous A, Ciralsky JB, Lai EC. Revisiting monovision for presbyopia. *Curr Opin Ophthalmol*. 2018; 29: 313-17.
21. Evans BJ. Monovision: A review. *Ophthalmic Physiol Opt*. 2007; 27: 417-39.
22. MacRae S, Holladay JT, Glasser A et al. Special report: American Academy of Ophthalmology Task Force consensus statement for extended depth of focus intraocular lenses. *Ophthalmology*. 2017; 124: 139-41.
23. Bellucci R, Cargnoni M, Bellucci C. Clinical and aberrometric evaluation of a new extended depth-of-focus intraocular lens based on spherical aberration. *J Cataract Refract Surg*. 2019; 45: 919-26.
24. Ribeiro F, Cochener B, Kohnen T et al. Definition and clinical relevance of the concept of functional vision in cataract surgery ESCRS Position Statement on Intermediate Vision: ESCRS Functional Vision Working Group. *J Cataract Refract Surg*. 2020; 46(suppl 1): S1-S3.
25. Łabuz G, Son HS, Naujokaitis T et al. Laboratory Investigation of Preclinical Visual-Quality Metrics and Halo-Size in Enhanced Monofocal Intraocular Lenses. *Ophthalmol Ther*. 2021; 10(4): 1093-104.

For non-
commercial use
only

Authors' contributions:

All authors have equal contribution to the paper.

Conflict of interest:

None.

Financial support:

None.

Ethics:

This study was in line with the Declaration of Helsinki and was approved by the local bioethics committee with the signature: 6/PNDR/2021.