

Vitreous floaters – etiology, diagnostics and treatment



Joanna Skowronek¹, Anna Świąch^{1,2}

¹ Department of Vitreoretinal Surgery, Independent Public University Hospital No. 1 in Lublin
Head: prof. Jerzy Mackiewicz, MD, PhD

² OPTIMUM Ophthalmology Centre, Warsaw
Scientific Director: Jaromir Wasyluk, MD, PhD

HIGHLIGHTS

The article discusses vitreous floaters, their aetiology, process of posterior vitreous detachment, also diagnostics and treatment including effects of supplementation with antioxidants and exogenous amino acids.

ABSTRACT

Vitreous floaters are one of the most common complain of ophthalmological patients. The aetiology of floaters includes pathological process (vitreous haemorrhages, injuries, diabetics or uveitis) and also natural age-related changes in vitreous body. Diagnosis and treatment depends on the severity of the symptoms. Process of posterior vitreous detachment requires particularly careful monitoring, because of potential complications such as retinal tears or retinal detachment. Supplementation with anti-glycation and antioxidant substances allows to reduce complains of patients with vitreous floaters.

Key words: vitreous floaters, vitreous body, PVD, posterior vitreous detachment

INTRODUCTION

Vitreous floaters affect many people of different ages. They cause discomfort at near and far distances. Patients report problems reading, using the computer, telephone or driving.

Floaters, described by patients as flying flies, clouds, zig-zags, threads, specks or dots, are best seen when looking at a bright background, called “miodesopsia” (fig. 1).

FIGURE 1

Vitreous floaters – particularly visible when patients are looking at a bright background.



The severity of reported symptoms depends on the floater's size, distribution, density, and the distance between the floaters and the retina, location in the visual axis, and patient's anxiety levels. It is difficult to determine the exact incidence rate of vitreous floaters. It can be estimated that up to 70% of people are affected, with higher incidence among myopes and hyperopes [1]. Even young people, below 30 years of age, complain of vitreous floaters. In many patients, vitreous floaters have a negative impact on health-related quality of life, and even some of them show a higher rate of psychological distress compared to the control.

THE COMPOSITION OF THE VITREOUS BODY

The vitreous body is mainly composed of water (99%), type II and IX collagen, hyaluronic acid and ascorbate. It accounts for about 80% of the volume of the human eye and assists vision, supports the eyeball, absorbs the shock

waves, and provides physical support to the retina. The vitreous body allows oxygen to diffuse from the retinal vessels into the anterior segment of the eyeball. The central part of the vitreous body is occupied by the core made up of interconnected bundles of collagen fibrils separated by hydrated hyaluronic acid molecules.

The central vitreous is surrounded by the vitreous cortex. The vitreous is attached to the posterior surface of the lens with the Wieger's ligament (which disappears around the age of 30 years); the space between is called the Berger's space. From the back, the vitreous body is firmly attached to the retina at the vessels, at the periphery of the optic nerve disc, in the periorbital area, and at the pars plana of the ciliary body about 2 mm anterior to the ora serrata and 3–4 mm posterior to it. Here, the collagen fibers are densely packed together and arranged in parallel to each other. Owing to laminin and fibronectin, the vitreous is firmly attached to the anterior surface of the retina – the limiting membrane.

THE ETIOLOGY OF VITREOUS FLOATERS

The risk of vitreous opacities is associated with some pathological conditions such as vitreous hemorrhage in diabetes or after ocular trauma, uveitis, increasing age, or posterior vitreous detachment (PVD). Vitreous hemorrhage is also associated with non-proliferative diabetic retinopathy, but spontaneous absorption of exudative lesions is visible within a few weeks. A careful inspection of the retina is necessary for the detection any tears or vitreoretinal traction that may lead to retinal detachment. In case of dense hemorrhages, an ultrasound examination is performed for accurate eyeball imaging and possible surgical intervention (fig. 2). Vitrectomy is indicated for long-standing, dense vitreous hemorrhages. Vitreous hemorrhages may also develop because of blunt trauma to the eyeball. In such a case, it is important to find the cause of the lesion and intervene appropriately. Patients often report vitreous opacities caused by amyloidosis or due to inflammatory response following capsulotomy or intravitreal injections (fig. 3). With ageing, the vitreous body undergoes structural changes. Vitreous degeneration results from a progressive reorganization of the hyaluronic acid and collagen molecular networks. The vitreous undergoes the phenomenon of synchysis and syneresis. Initially, vitreous liquefaction occurs because hyaluronic acid separates from the collagen fibers. Then, collagen fibers aggregate together, forming bundles within the space filled with liquefied vitreous [2]. Once a rupture occurs in the cortical part of the vitreous body, vitreous fluid leaks through the tear and the vitreous body separates from the retina.

Patients commonly report PVD because of its frustrating symptoms. PVD affects about 60% of people over the age

FIGURE 2

Hemorrhage into the vitreous body with minor traction on ultrasound examination of the eyeball.

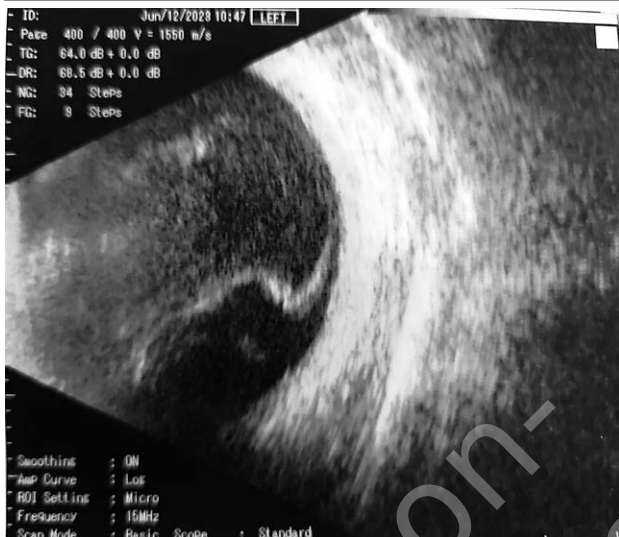
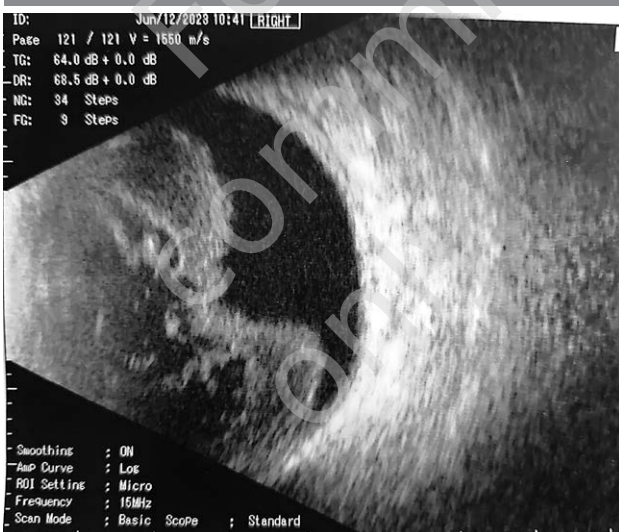
FIGURE 3

Dense post-inflammatory tortuosity on ultrasound examination of the eyeball.



of 70. Vitreous opacities are described as floating clumps, best seen by the patient against a bright background. About 50% of PVD cases occur in people aged 50 years and older. PVD is diagnosed more often in women than in men, probably due to hormonal changes associated with menopause. It is 7–10 times more frequent in aphakic as compared to phakic eyes. PVD develops about 18–24 months after cataract surgery [3]. Even though many patients acquire improved visual acuity after cataract surgery, some patients complain of discomfort due to the presence of vitreous opacities [4]. Oxidative stress is associated with degener-

ative changes in the vitreous body [5]. Oxidative stress is caused by an imbalance between oxidation processes and the activity of the antioxidant system. Reactive oxygen species are neutralized by enzymatic and non-enzymatic antioxidants such as tocopherol, ascorbic acid, glutathione, carotene, superoxide dismutase, catalase and glutathione peroxidase. Increased levels of ROS disrupt vitreous collagen fibers in the process of hyaluronic acid depolymerization leading to collagen aggregation. The process of oxidative stress is exacerbated by hyperglycemia, which causes non-enzymatic glycation and glycooxidation. Deterioration of collagen in the vitreous can lead to vitreous degeneration, pathological changes in the vitreoretinal junction, and microcirculatory abnormalities in diabetic retinopathy [6]. Recent studies have suggested that antioxidants such as ascorbic acid and collagen fiber glycation inhibitors (l-lysine, procyanidin) may reduce visual complaints associated with vitreous opacities [7–9]. L-lysine and inositol have been found to have good anti-glycating effects and may have beneficial effect in vitreoretinal diseases. Inositol was found to be useful in inhibiting collagen glycooxidation. It reduces the formation of collagen cross-linking, which can help maintain its structure. Inositol is synthesized in the body and can be found in nuts, beans, and yeast. L-lysine is an essential amino acid found in cheese, eggs, milk, fish, cocoa, meat and soy. The body does not have the ability to synthesize it, so it must be supplied through the diet, unlike endogenous amino acids. The antiglycation effect of l-lysine is stronger than of inositol. Recent studies indicate the important role of l-lysine in preventing collagen glycation and in the treatment of eye diseases, particularly of vitreous body [10].

Some antioxidants (e.g., vitamins) must also be supplied from external sources. Vitamin C is one the most potent antioxidants, found mainly in fruits and vegetables. It is responsible for neutralizing free radicals, and its deficiency leads to impaired collagen synthesis, decreased immunity, fatigue or anemia. Selenium is an essential component of many enzymes, including a powerful antioxidant – glutathione peroxidase. It can be found in seafood, fish, chickpeas or milk. Selenium deficiency is associated with nervous system disorders, thyroid diseases, immune system disorders, and an increased risk of developing civilization diseases or cancer. Zinc, a cofactor of about 200 enzymes, is extremely important for the proper functioning of the body. Zinc is also a component of another important antioxidant – superoxide dismutase. Zinc can be found in cheese, porridge, pumpkin or sunflower seeds. Zinc deficiency may lead to many health problems, including skin lesions, impaired wound healing, and decreased immunity. Furthermore, zinc helps maintain normal vision. The effects of antioxidant deficiency prove their importance for the proper functioning of the entire body; therefore,

it is worth ensuring an adequate supply of antioxidants in the diet, both in food and supplementation. There are commercially available ready-made preparations containing necessary ingredients: antioxidants and protein glycation-inhibiting flavonoids and l-lysine. The positive role of a properly composed diet in the prevention of many diseases, including eye diseases, has been recently increasingly recognized. The 2018 study included 463 patients (334 women and 129 men) aged 14–61 years reporting the presence of visual disturbances related to vitreous floaters/opacities. The study group received a 3-month supplementation – 1 capsule daily containing l-lysine (125 mg), hesperidin from bitter orange extract, proanthocyanidin from grape extract (23.75 mg), vitamin C (40 mg) and zinc (5 mg). According to the subjective assessment in the questionnaire, nearly 91% of the respondents showed a reduction in their reported complaints – a slight improvement in 25.9%, a moderate improvement in 27.6%, a significant improvement in 28.4%, and a very significant improvement in 8.7% of people. Favorable results were observed in both women and men, especially in the group below 50 years of age [11].

Visual comfort improvement has been reported after the use of potassium iodine eye drops in the treatment of troublesome vitreous floaters [12]. Potassium iodine is also recommended in vitreous pathologies such as post-hemorrhagic floaters – it supposedly accelerates their absorption [13]. Potassium iodine binds free radicals, speeds up metabolism and has anti-inflammatory properties, so it has long been used in the treatment of many eye diseases. Iodine is essential for the proper synthesis of ft_3 and ft_4 , and its deficiency can lead to hypothyroidism. The recommended intake of iodine depends on age, gender or lifestyle, and its increased supply is required during pregnancy and lactation. Foods high in iodine include fish, especially sea fish, shellfish, eggs, and dairy products. Including commercially available potassium iodine eye drops in the treatment of post-hemorrhagic vitreous lesions should be considered. PVD is a long-term process and can last up to several months.

We distinguish partial and complete PVD (fig. 4–6). Its course can be chronic or acute. Symptoms that require urgent ophthalmology follow-up include flashes (photopsia), opacities, or blurred vision. Posterior vitreous detachment may also be accompanied by vitreous hemorrhage due to possible retinal tears. Periodic ophthalmic follow-up is recommended to monitor the progression of lesions and urgently intervene. If a retinal tear is present, it needs to be treated with a laser. This is an indication for urgent photocoagulation, as retinal tear can lead to retinal detachment. Such complications occur in about $\frac{1}{5}$ of patients presenting with symptomatic PVD.

DIAGNOSTICS

Vitreous opacities can be visualized on ultrasound biomicroscopy. Patients often describe the Weiss ring as a blurred ring-shaped opacity. On B-scan ultrasound, PVD is described as a thin, hyperreflective line at the border of the vitreous body. It is also visible on OCT imaging.

TREATMENT

Since there are no consensus guidelines on the treatment of vitreous floaters, this process is not easy. Laser vitreolysis or vitrectomy are recommended if symptoms are particularly bothersome [14]. Nd:YAG laser vitreolysis uses laser energy to fragment vitreous opacity and shift them off the optical axis [15]. Sometimes, for better results, the treatment should be repeated. Vitreolysis is recommended to treat single, centrally located opacities [16], with a distance more than 3 mm from the retina. Contraindications to vitreolysis include young age, glaucoma, small floaters located peripherally or too close to the retina, many small opacities,

FIGURE 4

Vitreous detachment adjacent to the macular area – OCT.

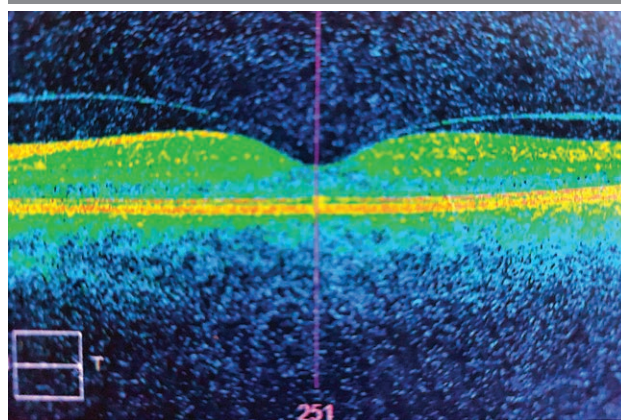


FIGURE 5

Vitreoretinal traction on OCT.

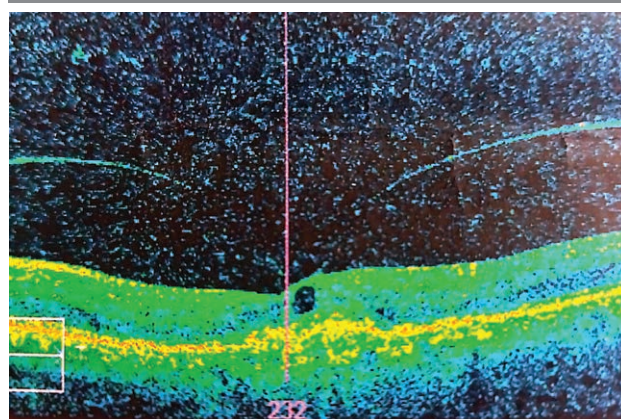
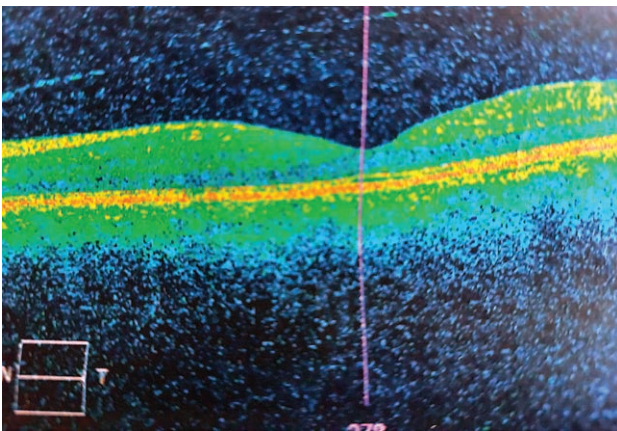


FIGURE 6

Completely detached vitreous body visualized on OCT.



or active vitreous inflammation. The undoubted advantage of vitreolysis is that it is performed as an outpatient procedure and is relatively short. The percentage of positive results reaches almost 90%. The risk of possible complications is relatively low and is associated with the use intraocular lens: eye discomfort, intraocular pressure spike, temporary deterioration of vision, macular edema, hemorrhage into the vitreous body, or retinal detachment [17]. Due to potential risks and complications, vitrectomy is the primary treatment for severe floaters that impact patient's vision

[18, 19]. Vitrectomy is indicated if vitreous opacities prevent the diagnosis of serious retinal pathologies. Vitrectomy should also be considered in patients who persistently complain that opacities adversely affect their quality of life. Complications of vitrectomy include cataract formation, increased risk of developing primary open angle glaucoma, retinal tear or detachment, vitreous hemorrhage, and endophthalmitis.

The results of the procedure are very good, with about 90% of patients reporting improvement, reduction or resolution of their complaints. The decision about the treatment should be undertaken together with the patient after considering all possible complications and benefits.

CONCLUSIONS

Vitreous floaters negatively affect patients' health-related quality of life [20]. Therefore, they require attention and intervention not only due to their severity, but also because of the level of patient frustration [21, 22]. In our ophthalmic practice, we may encounter patients complaining on vitreous floaters lowering patient's visual comfort. In such cases, we should be understanding, offer proper supplementation with proven efficacy, and, in the case of complications, recommend appropriate treatment.

Figures: from the authors' own materials.

CORRESPONDENCE

Joanna Skowronek, MD

Department of Vitreoretinal Surgery, Independent Public University Hospital No. 1 in Lublin
20-079 Lublin, ul. Chmielna 1
e-mail: joanna.skowronek89@gmail.com

ORCID

Anna Świąch – ID – <http://orcid.org/0000-0002-2238-6966>

References

1. Webb BF, Jadon R, Schroeder MC et al. Prevalence of vitreous floaters in a community sample of smartphone users. *Int J Ophthalmol.* 2013; 6(3): 402-5.
2. Jamroz-Witkowska A, Łukasik U, Skonieczna K et al. Zmiany w ciele szklistym związane z wiekiem – patogeneza, objawy i leczenie. *Okulistyka.* 2015; 1: 11-3.
3. de Smet MD, Gad Elkareem AM, Zwinderman AH. The Vitreous, the Retinal Interface in Ocular Health and Disease. *Ophthalmologica.* 2013; 230: 165-78.
4. Kim J, Lee HJ, Park IW et al. Comparison of Floaters after Cataract Surgery with Different Viscoelastics. *Int J Med Sci.* 2018; 15(3): 223-7.
5. Ankamah E, Sebag J, Ng E et al. Vitreous antioxidants, degeneration, and vitreo-retinopathy: exploring the links. *Antioxidants.* 2020; 9: 7.
6. Kamińska A, Dudek A. Rola ciała szklistego w procesie widzenia. *Okulistyka.* 2019; 3(XXII): 48-51.

7. Ankamah E, Green-Gomez M, Roche W et al. Dietary Intervention With a Targeted Micronutrient Formulation Reduces the Visual Discomfort Associated With Vitreous Degeneration. *Transl Vis Sci Technol.* 2021; 10(12): 19.
8. Deguine V, Menasche M, Ferrari P et al. Free radical depolymerization of hyaluronan by Maillard reaction products: role in liquefaction of aging vitreous. *Int J Biol Macromol.* 1998; 22: 17-22.
9. Deguine V, Labat-Robert J, Ferrari P et al. Aging of the vitreous body. Role of glycation and free radicals. *Pathol Biol (Paris).* 1997; 45: 321-30.
10. Sulochana KN, Ramprasad S, Coral K et al. Glycation and glycoxidation studies in vitro on isolated human vitreous collagen. *Med Sci Monit.* 2003; 9(6): BR260-4.
11. Sobol M, Oseka M, Kaercher Th et al. (BON 030) The effect of oral supplementation with L-lysine, hesperidin, proanthocyanidins, vitamin C and zinc on the subjective assessment of the quality of vision in patients with vitreous floaters. *J Alzheimers Dis.* 2018; 3(64): 1034.
12. Raczyńska K, Kokot W, Krajka-Lauer J et al. Jod w leczeniu zwyrodnienia ciała szklistego. *Klin Oczna.* 2004; 3(Suplement): 518-20.
13. Winkler R. Iodine – A Potential Antioxidant and the Role of Iodine/Iodide in Health and Disease. *Nat Sci.* 2015; 7: 548-57.
14. Broadhead GK, Hong T, Chang AA. To Treat or Not to Treat: Management Options for Symptomatic Vitreous Floaters. *Asia Pac J Ophthalmol (Phila).* 2020; 9(2): 96-103.
15. Souza CE, Lima LH, Nascimento H et al. Objective assessment of YAG laser vitreolysis in patients with symptomatic vitreous floaters. *Int J Retina Vitreous.* 2020; 6: 1.
16. Brasse K, Schitz-Valckenberg S, Junemann A et al. YAG laser vitreolysis for treatment of symptomatic vitreous opacities. *Ophthalmologe.* 2019; 116(1): 73-84.
17. Sobolewski P. Witreoliza i zwyrodnienie ciała szklistego – zapobieganie, leczenie i rozpoznawanie. *Okulistyka po Dyplomie.* 2015; 1: 11-3.
18. Milston R, Madigan MC, Sebag J. Vitreous floaters: Etiology, diagnostics, and management. *Surv Ophthalmol.* 2016; 61(2): 211-27.
19. Mason JO 3rd, Neimkin MG, Mason JU 4th et al. Safety, efficacy, and quality of life following sutureless vitrectomy for symptomatic vitreous floaters. *Retina.* 2014; 34(6): 1055-61.
20. Wagle AM, Lim W-Y, Yap T-P et al. Utility values associated with vitreous floaters. *Am J Ophthalmol.* 2011; 152(1): 60-5.
21. Sebag J. Floaters and the quality of life. *Am J Ophthalmol.* 2011; 152(1): 3-4.e1.
22. Kim Y-K, Young Moon S, Mi Yim K. Psychological Distress in Patients with Symptomatic Vitreous Floaters. *J Ophthalmol.* 2017; 2017: 3191576.

Authors' contributions:

Joanna Skowronek: idea of the project, collecting the literature, preparation of the manuscript; Anna Święch: edition of the manuscript.

Conflict of interest:

None.

Financial support:

None.

Ethics:

The content presented in the article complies with the principles of the Helsinki Declaration, EU directives and harmonized requirements for biomedical journals.