

# Efficacy of oral steroid therapy in the treatment of acute maculopathy in the course of hand, foot and mouth disease – 3 case reports



Adam Cywiński<sup>1</sup>, Daniela Ferda-Lewińska<sup>1</sup>, Marcin Gacek<sup>1,2</sup>

<sup>1</sup> Silesian Eye Treatment Centre in Żory, Poland  
Head: Adam Cywiński, MD, PhD

<sup>2</sup> Department of Physics, Faculty of Production Engineering and Materials Technology,  
Częstochowa University of Technology, Poland  
Head: Assoc. prof. Jan Świerczek, D.Sc., M.Sc.

## HIGHLIGHTS

Sudden, profound loss of vision, also in terms of color discrimination, resulting from acute maculopathy in the course of adult hand, foot and mouth disease is mostly reversible. Oral steroid therapy used in the right dose and time allows regaining vision even after a few days from its implementation.

## ABSTRACT

An oral steroid therapy has been used in three patients who experienced a rapid deterioration of vision in one eye. The loss of vision was preceded by the appearance of skin symptoms, observed in hand, foot and mouth disease, commonly known as the Boston's disease. Each of the patients had previous contact with this disease. Hospitalization of the first patient, during which general antibiotic therapy, antiviral drugs and short-term intravenous steroid therapy were used, brought only a slight improvement in visual acuity. Given the accompanying colour discrimination dysfunction, oral steroid therapy was introduced in this patient, already in the outpatient setting. The therapy brought a significant improvement in visual acuity in a short time and restored the ability to distinguish colours. This form of treatment was used in another two patients with similar, good result.

**Key words:** hand, foot and mouth disease, retinitis, steroid therapy, sudden visual loss

## INTRODUCTION

*Boston's disease* is a colloquial term for a disease of hands, feet, and mouth. It is caused by a viral infection. The correct medical name is hand, foot and mouth disease (HFMD), which is a reference to the characteristic rash located in these areas. It is very often confused with chickenpox due to the appearance of this rash. Other terms for the condition include vesicular rash, enteroviral bullous stomatitis with eczema, or simply a disease of feet, hands and mouth. Unlike chickenpox, hand, foot and mouth disease is caused by Coxsackieviruses, from the group of enteroviruses. The disease most often affects young children, less often adults. It spreads primarily by droplets. Contact with the stool of an infected person, e.g. during a child's visit to the toilet, is also a possible route of infection. HFMD spreads mainly in places where children under 5 years of age stay, i.e. in nurseries and kindergartens. The peak incidence occurs in summer months. The disease has a characteristic course with four phases:

1. **Latent phase** – it is the incubation period of the disease, with no clinical signs. It lasts 3–5 days. During this period, the virus penetrates the lymphatic system.
2. **Prodromal phase** – it lasts 2–3 days and is characterized by flu-like or acute retroviral symptoms. Fever can reach 40°C. It is accompanied by chills, bone and joint pains and headaches, malaise, and appetite disorders. In some cases, red dots on the oral mucosa, hands and feet can be seen in this phase. The virus penetrates from the lymphatic system into the blood and a sudden increase in viraemia begins.
3. **Full development phase** – it lasts 7–10 days. At this time, typical discoloration and blisters are observed. Skin lesions on the hands or feet are small, 5–19 mm in diameter. They are salmon in colour. In addition, they may be accompanied by inflammation of the throat and palatine tonsils. The lesions are painful and felt primarily when eating food and swallowing saliva. The rash subsides in about a week.
4. **Remission phase** – it usually lasts about 4 weeks, but it can be longer. During this period, skin and mucosal lesions disappear.

**Targeted treatment** – none, mainly antipyretics and adequate hydration. Antibiotic therapy is not implemented due to its ineffectiveness.

**Complications** are rare. The most common complications include fever, dehydration resulting from refusal to drink fluids due to pain when swallowing, sometimes diarrhoea. Bacterial superinfections appear mainly in children scratching skin lesions due to intense itching. Neurological complications are very rare and include meningitis, encephalitis, and flaccid paralysis [1–8]. What is the connection of HFMD with eye disease? Inflammatory lesions in

the retina and/or choroid develop in some adults exposed to the disease.

## OBJECTIVE

Retrospective evaluation of clinical changes and the effectiveness of oral steroid therapy in three patients with ocular complications of HFMD, in whom previous hospitalization did not bring favourable results.

## MATERIAL AND METHOD

Three patients, including two women and one man, aged 24–32, came to the Silesian Eye Treatment Centre in Żory within 4 weeks due to significant deterioration in visual acuity lasting about 7–10 days. Two patients had previously been hospitalized.

### Medical history

The main reason for the doctor's appointment and subsequent hospitalization was the appearance of a central scotoma in the visual field in one eye, which was accompanied by a significant decrease in visual acuity and loss of colour recognition. All patients had previous contact with a child with HFMD. The loss of vision was accompanied by the presence of skin lesions in characteristic locations of the body. During hospitalization, acute idiopathic maculopathy was diagnosed in one case, and central retinitis in the other two cases. The patients received systemic antibiotic therapy and short-term intravenous steroid therapy. Two patients were prescribed oral acyclovir. Visual acuity to far distances upon admission to the hospital did not exceed recognition of the largest optotype on Snellen charts assessed at a distance of 1 m. Upon discharge, visual acuity to far distances was 0.1–0.7 (logMar) and to near distances 1.5–2.0 (Snellen). During hospitalization, diagnostic examinations were performed, including fluorescein angiography (FA) and optical coherence tomography (OCT) of the macula. FA showed the presence of an inflammatory leakage within the macula. OCT showed oedema of the neurosensory retina, mainly its outer layers. One of the patients underwent a visual evoked potentials (VEP) examination (flash and pattern) due to colour recognition disorders. The test showed no signs of optic neuritis. The lack of access to all tests, made in hospital tests (information available only in hospital records) did not allow for any other form of their interpretation and visualization. In the patient (aged 30), who was the first to come for a consultation in Żory (patient "0"), immediately after leaving the hospital, visual acuity to far distances in the affected left eye reached the value of 0.7 (logMar), and visual acuity to near distances was D-2.0 (Snellen). In addition, it was accompanied by visual impairment in the field of colour recognition (in the right eye, visual acuity and colour recog-

nition were normal). A standard colour photograph of the fundus showed pigment rearrangements in the projection of an irregularly shaped macula (fig. 1). OCT of the macula of the left eye revealed slight elevations of the photoreceptor layer, pigment rearrangements within the retinal pigment epithelium (RPE) and slight oedema of the outer layers of neurosensory retina (fig. 2). Similar changes were found in the other two patients, but they were more pronounced in the patient with significantly reduced visual acuity to far distances – to 1.0 (logMar). A colour photograph of the fundus showed differences in the intensity of changes within the RPE to the disadvantage of the patient with poorer visual acuity (fig. 3). Interestingly, this patient did not receive general steroid therapy during hospitalization, but only antibiotic therapy and acyclovir. It is worth mentioning that in all cases visual acuity and colour recognition in the other eye were normal.

Due to colour recognition disorders, patient “0” was recommended to undergo VEP examination (flash and pattern). They did not show any deviations from the normal state (fig. 4A, B). In the absence of a clear relationship between the anatomical image of the fundus (benign changes) and a significant decrease in visual acuity combined with colour vision disorders, it was recommended to implement oral steroid therapy while maintaining the rigor of dosage.

## RESULTS

Patient “0” received the initial dose of the formula containing 64 mg of methylprednisolone, with the recommendation to reduce it according to the schedule. The follow-up appointment, which took place 5 days later, showed a significant improvement in visual acuity to far and near distances, and regained colour recognition in the affected eye. Vision to far distances changed from 0.7 to 0.1 (logMar) and to near distances from D-2.0 to D-0.5 (Snellen). Oral steroid therapy was recommended for the other two patients. In the case of the male patient, vision to far distances improved from 0.8 to 0.1 (logMar) in 5–7 days. In the case of the second female patient, it took approx. 3 weeks to notice improvement from 0.9 to 0.1 (logMar). During this period, the patient continued to take methylprednisolone. The OCT of the macula practically did not change (fig. 5). The location of the lesion in OCT coincides with the lesion visible on the colour photograph of the eye fundus taken a month after the introduction of steroid therapy. In addition to the thickening of RPE, located under the fovea, there is a slight discoloration surrounding the lesion (fig. 6). Changes in pattern VEP respond, taken before including oral steroid therapy were observed (fig. 7A, B). During the first consultation in Żory, none of the patients had any skin lesions characteristic of hand, foot and mouth disease.

FIGURE 1

A colour photograph of the fundus of the left eye in the range up to 45°. Patient “0”. A few days after the onset of sudden vision loss, a noticeable irregular pigment density rearrangement involving the fovea. The lesion is surrounded by an area of lighter colour. Visual acuity to far distances 0.7 (logMar), to near distances D-0.5 (Snellen). The patient received, among others, 3-day intravenous steroid therapy during hospitalization.

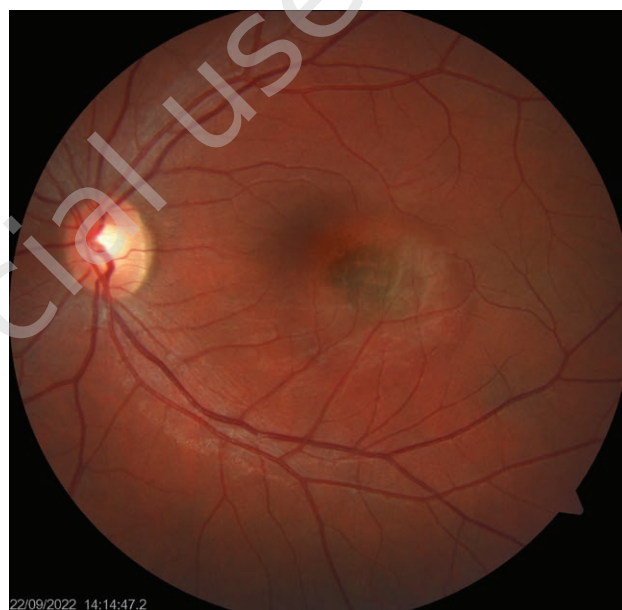

FIGURE 2

OCT of the macula in the left eye performed on the same day as the colour photograph presented in figure 1 was taken. Mild elevation of the photoreceptor layer, pigment rearrangement within the RPE and slight edema of the outer layers of the neurosensory retina can be observed.

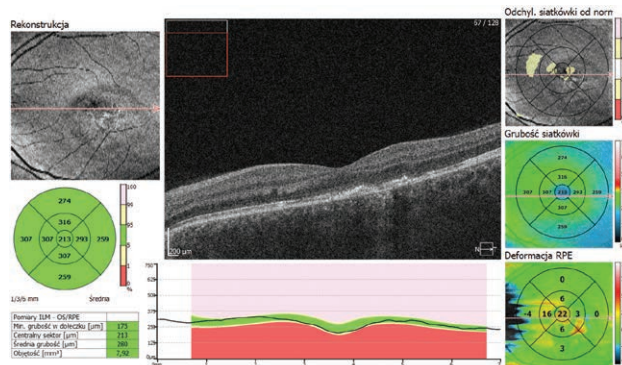
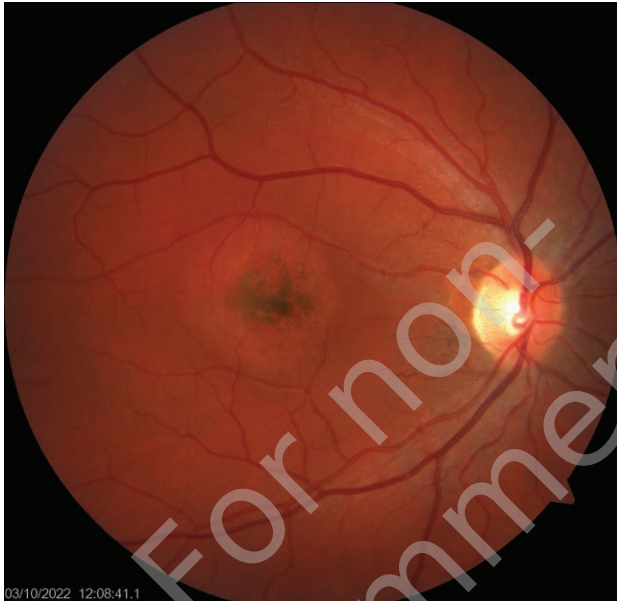



FIGURE 3

A colour photograph of the fundus of the right eye up to 45°. A few days after the onset of sudden vision loss, there is visible rearrangement and pigment densification involving the fovea, surrounded by a ring – an area of lighter colour. Visual acuity to far distances = 1.0 (logMar), to near distances D-2.0 (Snellen). The patient did not receive steroid therapy during hospitalization.



## DISCUSSION

Based on the analysis of the above cases and on the information contained in publicly available articles, it can be concluded that we are dealing with a monocular, acute idiopathic maculopathy in the course of hand, foot and mouth disease. As already mentioned, the disease is caused by Coxsackieviruses, from the group of enteroviruses. Although such cases are not very common, the disease seems to be quite well described. Its main carriers are children. The disease, passing to adults, can lead to ocular complications. This is where the naming dilemma comes in. The adjective 'idiopathic' refers to a situation in which the cause of the development of the disease remains unknown [9]. In this case, the cause-and-effect relationship seems clear. In the *Gass Atlas* the following information about this condition can be found:

1. A transient dysfunction of the outer layers of the retina, visible in *flash* electroretinography (ERG).
2. Indocyanine angiography may show involvement of the inner choroid as a result of spreading pathology.
3. The central part of the lesion in fundus autofluorescence (FAF) is hyperautofluorescent, and the outer part is hypoautofluorescent [9].

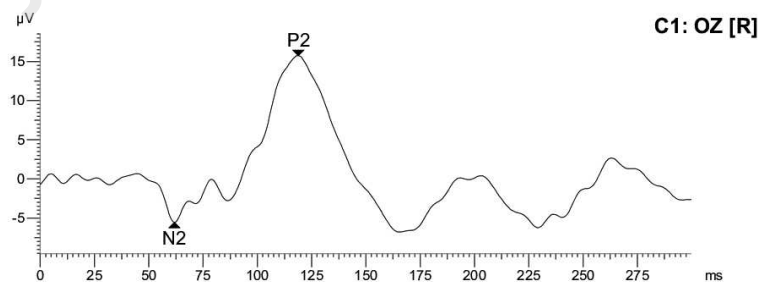
As a reminder – autofluorescence examination (FAF) gives us information about the condition of the RPE cells. Enables the detection and registration of lipofuscin deposits. Lipofuscin is a naturally occurring marker of metabolism

FIGURE 4

A. VEP flash result with interpretation in patient "0". B. VEP pattern result with interpretation in patient "0".

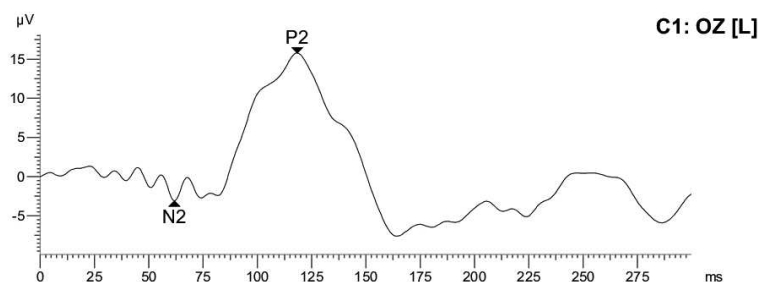
### 1.Step: trans. 2.0

Meas. range:  $\pm 400 \mu V$   
Sample freq.: 2.01kHz (498 $\mu s$ )  
Meas. filter: 1Hz - 100Hz  
  
Impedance: (+) 5K $\Omega$  (-) 6K $\Omega$   
Background: dark  
Stimulator: int.LED 2cd/m<sup>2</sup> white  
Avg's/Artef.: 80 / 0  
  
Marker N2: 61.7ms -5.6 $\mu V$   
Marker P2: 118.9ms 21.3 $\mu V$



### 2.Step: trans. 2.0

Meas. range:  $\pm 400 \mu V$   
Sample freq.: 2.01kHz (498 $\mu s$ )  
Meas. filter: 1Hz - 100Hz  
  
Impedance: (+) 5K $\Omega$  (-) 6K $\Omega$   
Background: dark  
Stimulator: int.LED 2cd/m<sup>2</sup> white  
Avg's/Artef.: 80 / 0  
  
Marker N2: 61.7ms -3.1 $\mu V$   
Marker P2: 118.4ms 18.9 $\mu V$

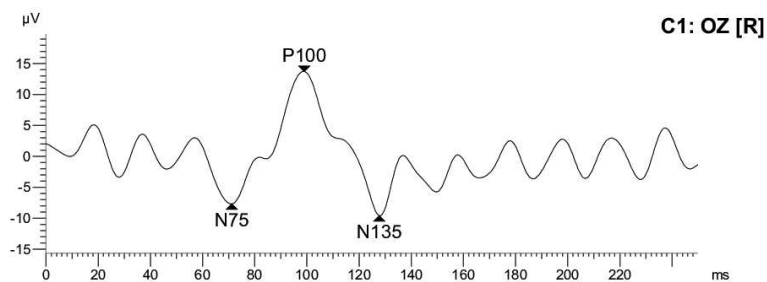


**1.Step: Patt 1.0°**

Meas. range:  $\pm 400\mu V$   
 Sample freq.: 1.98kHz (505 $\mu s$ )  
 Meas. filter: 1Hz - 100Hz

Impedance: (+) 6K $\Omega$  (-) 6K $\Omega$   
 Stimulator: ext. CRT/Checkerboard/PattRev  
 Pattern: 48pix/21x21/1.01°  
 Ext.light: 610Lux  
 Avg's/Artef.: 80 / 0

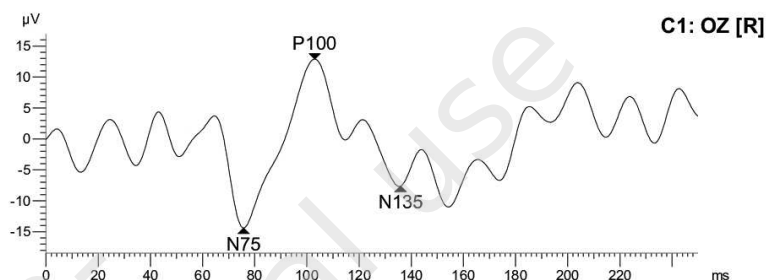
Marker N75: 71.2ms -7.7 $\mu V$   
 Marker P100: 99.0ms 21.4 $\mu V$   
 Marker N135: 127.7ms -9.6 $\mu V$

**2.Step: Patt 0.3°**

Meas. range:  $\pm 400\mu V$   
 Sample freq.: 1.98kHz (505 $\mu s$ )  
 Meas. filter: 1Hz - 100Hz

Stimulator: ext. CRT/Checkerboard/PattRev  
 Pattern: 14pix/73x73/0.29°  
 Ext.light: 610Lux  
 Avg's/Artef.: 80 / 0

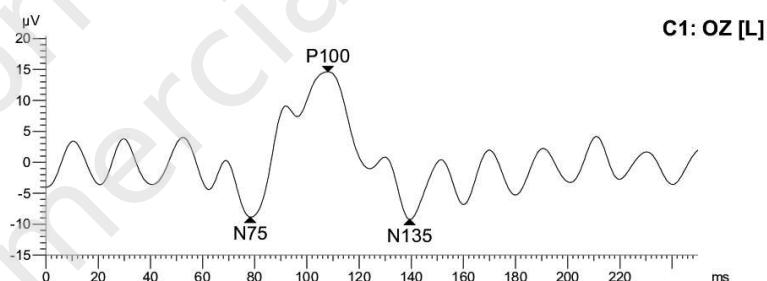
Marker N75: 75.7ms -14.4 $\mu V$   
 Marker P100: 103.0ms 27.3 $\mu V$   
 Marker N135: 135.9ms -7.7 $\mu V$

**3.Step: Patt 1.0°**

Meas. range:  $\pm 400\mu V$   
 Sample freq.: 1.98kHz (505 $\mu s$ )  
 Meas. filter: 1Hz - 100Hz

Impedance: (+) 6K $\Omega$  (-) 6K $\Omega$   
 Stimulator: ext. CRT/Checkerboard/PattRev  
 Pattern: 48pix/21x21/1.01°  
 Ext.light: 630Lux  
 Avg's/Artef.: 80 / 0

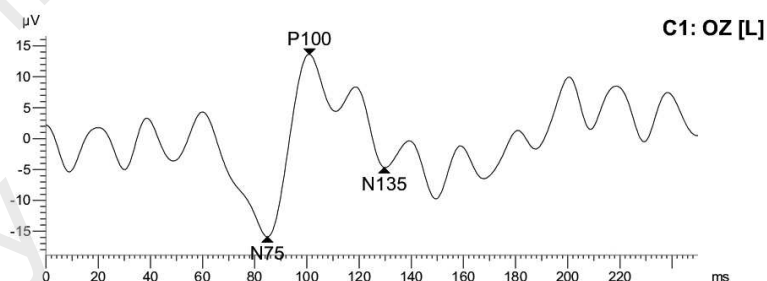
Marker N75: 78.3ms -8.9 $\mu V$   
 Marker P100: 108.0ms 23.5 $\mu V$   
 Marker N135: 139.3ms -9.2 $\mu V$

**4.Step: Patt 0.3°**

Meas. range:  $\pm 400\mu V$   
 Sample freq.: 1.98kHz (505 $\mu s$ )  
 Meas. filter: 1Hz - 100Hz

Stimulator: ext. CRT/Checkerboard/PattRev  
 Pattern: 14pix/73x73/0.29°  
 Ext.light: 580Lux  
 Avg's/Artef.: 80 / 0

Marker N75: 84.8ms -15.9 $\mu V$   
 Marker P100: 101.0ms 29.6 $\mu V$   
 Marker N135: 129.7ms -4.7 $\mu V$



in RPE. The analysis of this component gives important information about the state of the retina. Hyperautofluorescence indicates increased metabolism within the RPE, and hypoautofluorescence indicates reduced or no metabolism (black areas in FAF – fig. 8).

Falk et al. point out that in the initial period of changes occurring in the eye in the indirect biomicroscopy examination, the presence of microaneurysms and intraretinal haemorrhages surrounding the fovea can be observed. OCT shows a break and irregularity in the RPE located in the central part of the fovea.

These changes result from focal inflammation of the retina and choroid [10]. Other changes visible in a speculum examination, fluorescein angiography or OCT, mainly in the early stages of inflammation, include: retinitis, uveitis, presence of exudates in the mid-periphery of the macula, retinal vasculitis, subfoveal exudative neurosensory retinal

detachment, inflammation of the outer layers of the retina and irregular round fields of grey retinal oedema involving the macula [11, 12]. Other authors, describing changes in vision, point to a sudden, significant decrease in visual acuity occurring at the onset of the disease. Vision gradually improves over time. Despite the presence of pigment changes, visible in the macular projection in most cases, the final loss of vision is usually insignificant [11, 13].

Taking into account the abnormalities detected in the *flash* and *pattern* VEP, visual impairment in the field of colour recognition, the question arises whether we are dealing only with changes in the retina or with pathology such as retinitis and an inflammatory component covering further elements of the visual pathway, i.e. the second and third neuron of visual pathway, or the optic nerve.

What about treatment then? Since the disease is not bacterial pathway, antibiotic therapy is ineffective, as is the use of

FIGURE 5

Left eye: OCT of the macula taken before (left result) and 30 days (right result) after implementation of steroid therapy. The local RPE thickening in the subfoveal area, causing its partial oedema draws attention. Despite the lack of visible morphological changes, visual acuity improved from 1.0 to 0.1 (logMar) for far distances, and from D-2.0 to D-0.5 (Snellen) for near distances. Vision recovery time significantly extended, up to 3 weeks. The patient did not receive general steroid therapy during hospitalization.

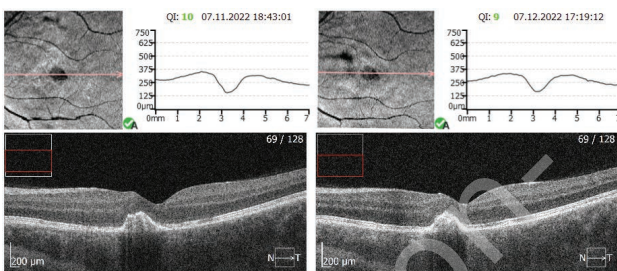
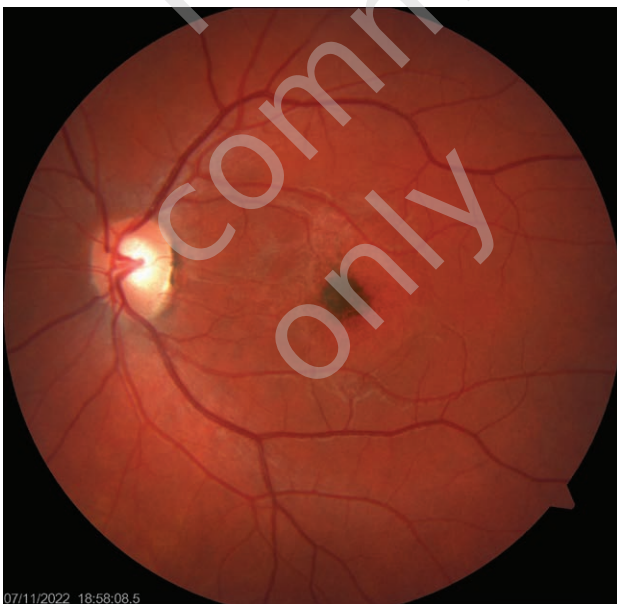

FIGURE 6

A colour photograph in the range up to 45° taken in the eye presented in figure 5. The accumulation of pigment is more concentrated, surrounded by a ring of lighter colour.



antiviral formulas containing acyclovir [14]. Some authors believe that the eye disease regresses on its own and does not require treatment. As the author's experience shows, the implementation of oral steroid therapy in two out of three patients led to a very quick (practically within 3–7 days) return of visual acuity to almost normal values. Only in the third case, in which not even short-term steroid therapy was implemented during hospitalization (immediately after the sudden loss of vision), and the visual acuity was the worst, it took much longer to regain good vision. Vision improved after nearly 3 weeks while the patient continued oral steroid therapy. In a very detailed article describing a case of acute idiopathic maculopathy in a 35-year-old woman, Agrawal et al. drew attention to the beneficial effect of long-term steroid therapy resulting in regaining normal vision by the patient [12].

It is worth emphasizing that when deciding to implement oral steroid therapy, it is important to remember to use the right dose of the drug. An appropriately high (read: right) starting dose and then its gradual reduction constitute the key to achieving the intended therapeutic effect. It cannot be expected that a patient whose body weight is, for example, 80 kg will obtain a therapeutic benefit from the use of a dose of, for example, 15 mg of corticosteroids. Such therapy could be perceived as a misunderstanding or ignorance of treatment principles. The use of inadequately low doses of corticosteroids causes that therapy is often considered ineffective and thus abandoned. Resuming steroid therapy, but in the right dosage (e.g. 1 mg/kg of body weight), brings the expected benefits [15].

In the described group of three patients, steroid therapy with a formula containing methylprednisolone was started with a dose of 1 mg/kg of body weight, and then it was gradually reduced. The treatment effect was very beneficial.

## CONCLUSIONS

A sudden and significant loss of visual acuity, accompanied by the loss of colour recognition, most often occurring in one eye, preceded by or accompanied by skin lesions characteristic of hand, foot and mouth disease, is most likely a consequence of acute maculopathy. Despite the viral background of this disease, the sudden introduction of oral steroid therapy, of course, in the right dose and at the right time, allowed for a quick normalization of vision, despite the pigment changes observed on the eye fundus, located mainly within the macula.

*Figures: from the author's own materials.*

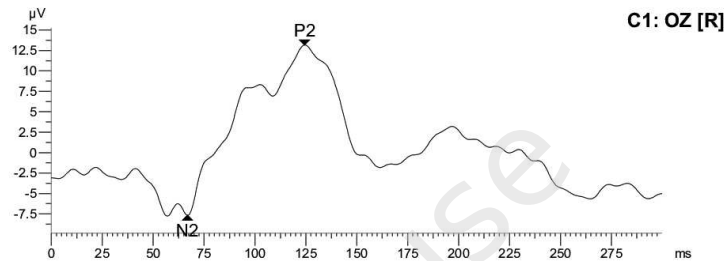


FIGURE 7

A. VEP *flash* result of right eye – correct response, left eye – borderline normal. B. VEP *pattern*, after stimulation of the 1<sup>st</sup> degree – correct response, after stimulation of the 3<sup>rd</sup> degree, the p100 amplitude decreased to 80% of the normal value in the right eye, to 50% of the normal value in the left eye. Changes in the macula. No signs of optic neuritis.

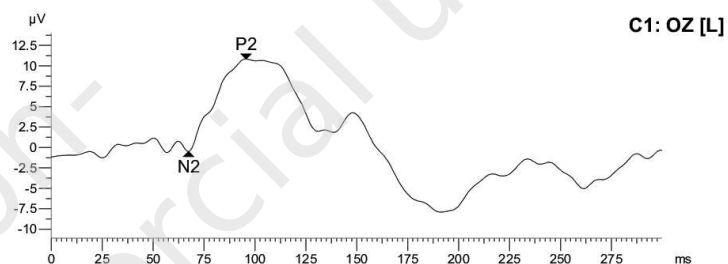
**1.Step: trans. 2.0**

Meas. range:  $\pm 400\mu V$   
Sample freq.: 2.01kHz (498 $\mu s$ )  
Meas. filter: 1Hz - 100Hz  
Impedance: (+) 5K $\Omega$  (-) 3K $\Omega$   
Background: dark  
Stimulator: int.LED 2cd/m<sup>2</sup> white  
Avg's/Artef.: 80 / 0  
Marker N2: 66.8ms -7.7 $\mu V$   
Marker P2: 124.4ms 20.9 $\mu V$



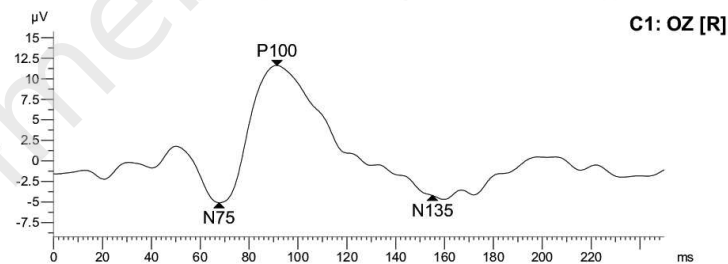
**2.Step: trans. 2.0**

Meas. range:  $\pm 400\mu V$   
Sample freq.: 2.01kHz (498 $\mu s$ )  
Meas. filter: 1Hz - 100Hz  
Impedance: (+) 4K $\Omega$  (-) 3K $\Omega$   
Background: dark  
Stimulator: int.LED 2cd/m<sup>2</sup> white  
Avg's/Artef.: 80 / 0  
Marker N2: 67.4ms -0.5 $\mu V$   
Marker P2: 95.5ms 11.3 $\mu V$



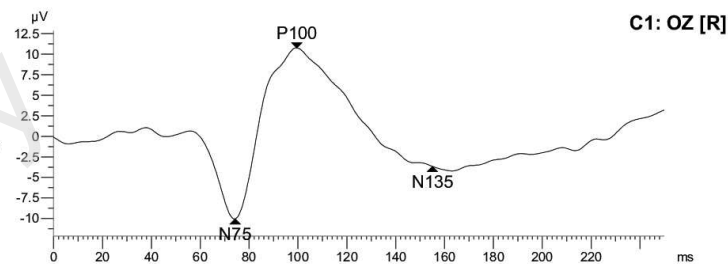
**1.Step: Patt 1.0°**

Meas. range:  $\pm 400\mu V$   
Sample freq.: 1.98kHz (505 $\mu s$ )  
Meas. filter: 1Hz - 100Hz  
Impedance: (+) 5K $\Omega$  (-) 3K $\Omega$   
Stimulator: ext. CRT/Checkerboard/PattRev  
Pattern: 48pix/21x21/1.01°  
Ext.light: 600Lux  
Avg's/Artef.: 80 / 0  
Marker N75: 67.7ms -5.1 $\mu V$   
Marker P100: 91.4ms 16.7 $\mu V$   
Marker N135: 155.0ms -4.2 $\mu V$



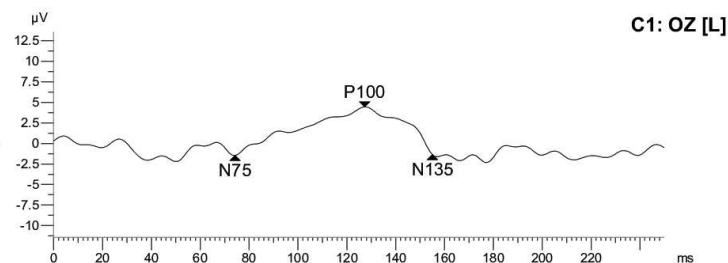
**2.Step: Patt 0.3°**

Meas. range:  $\pm 400\mu V$   
Sample freq.: 1.98kHz (505 $\mu s$ )  
Meas. filter: 1Hz - 100Hz  
Impedance: (+) 4K $\Omega$  (-) 3K $\Omega$   
Stimulator: ext. CRT/Checkerboard/PattRev  
Pattern: 14pix/73x73/0.29°  
Ext.light: 600Lux  
Avg's/Artef.: 80 / 0  
Marker N75: 74.2ms -10.1 $\mu V$   
Marker P100: 99.5ms 20.8 $\mu V$   
Marker N135: 155.0ms -3.7 $\mu V$



**3.Step: Patt 1.0°**

Meas. range:  $\pm 400\mu V$   
Sample freq.: 1.98kHz (505 $\mu s$ )  
Meas. filter: 1Hz - 100Hz  
Impedance: (+) 4K $\Omega$  (-) 3K $\Omega$   
Stimulator: ext. CRT/Checkerboard/PattRev  
Pattern: 48pix/21x21/1.01°  
Ext.light: 550Lux  
Avg's/Artef.: 80 / 0  
Marker N75: 74.2ms -1.5 $\mu V$   
Marker P100: 127.2ms 5.9 $\mu V$   
Marker N135: 155.0ms -1.3 $\mu V$



**4.Step: Patt 0.3°**

Meas. range:  $\pm 400\mu V$   
Sample freq.: 1.98kHz (505 $\mu s$ )  
Meas. filter: 1Hz - 100Hz  
Impedance: (+) 5K $\Omega$  (-) 3K $\Omega$   
Stimulator: ext. CRT/Checkerboard/PattRev  
Pattern: 14pix/73x73/0.29°  
Ext.light: 600Lux  
Avg's/Artef.: 80 / 0  
Marker N75: 56.6ms -0.1 $\mu V$   
Marker P100: 99.8ms 3.5 $\mu V$   
Marker N135: 155.0ms -0.5 $\mu V$

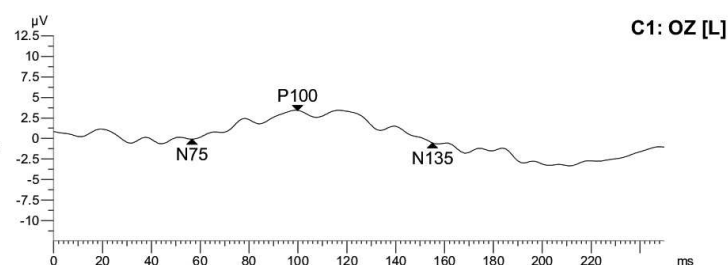
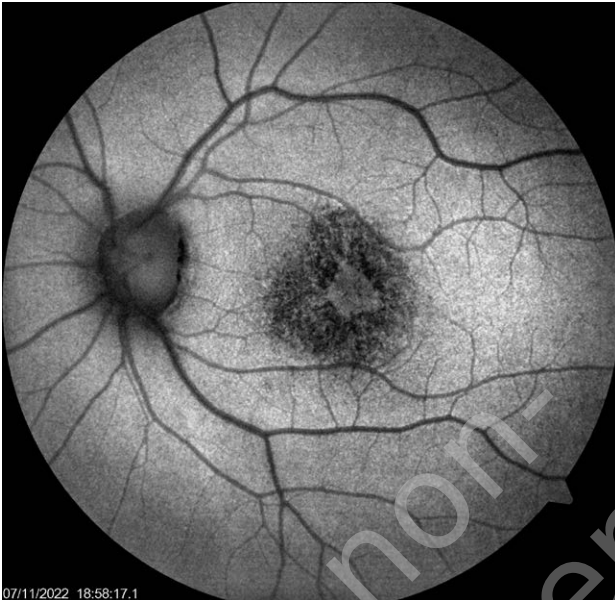


FIGURE 8

Autofluorescence (FAF). Alternating fields of hyper- and hypofluorescence in the projection of the macula.



**CORRESPONDENCE**

**Adam Cywiński, MD, PhD**

Silesian Eye Disease Treatment Centre in Żory  
44-240 Żory, ul. Okrężna 11  
tel. +48 502 137 635  
email: adamcyw@gmail.com

**ORCID**

Adam Cywiński – ID – <http://orcid.org/0000-0001-8732-7396>  
Marcin Gacek – ID – <https://orcid.org/0000-0002-1185-623X>

**References**

1. Nassef C, Ziemer C, Morrell DS. Hand-foot-and-mouth disease: a new look at a classic viral rash. *Curr Opin Pediatr*. 2015; 27(4): 486-91.
2. Jurek P, Wasilonek M. Bostonka atakuje. Dziwna wysypka to charakterystyczny objaw. Online: <https://www.medonet.pl/choroby-od-a-do-z/choroby-zakazne,choroba-bostonska--bostonka---wysypka--wirus--objawy--leczenie,artykul,1669641.html>.
3. Kuchciak-Brancewicz M, Bienias W, Kaszuba A. Choroba bostońska. *Dermatologia Praktyczna*. 2014; 1: 9-23.
4. Marczyńska M, Popielska J. Wysypki pęcherzykowe w infekcjach wirusowych. *Pediatrica po Dyplomie*. 2017; 2: 23-7.
5. Nassef C, Ziemer C, Morrell DS. Hand-foot-and-mouth disease: a new look at a classic viral rash. *Curr Opin Pediatr*. 2015; 27(4): 486-91.
6. Omaña-Cepeda C, Martínez-Valverde A, del Mar Sabater-Recolons M et al. A literature review and case report of hand, foot and mouth disease in an immunocompetent adult. *BMC Res Notes*. 2016; 9: 165.
7. Dziubek Z. Choroby zakaźne i pasożytnicze. PZWL, Warszawa 2003: 235-6.
8. Bienias W, Gutfreund K, Szewczyk A et al. Zespół dłoni, stóp i ust, czyli choroba bostońska: etiologia, obraz kliniczny i terapia. *Dermatologia Dziecięca*. 2013; 3: 18-21.
9. Agarwal A. Chapter 10: Infectious Diseases of the Retina and Choroid. In: Gass' Atlas of Macular Diseases. 5<sup>th</sup> ed. Elsevier 2013: 970.
10. Falk ZE, Malik KJ. Unilateral acute idiopathic maculopathy in a patient with hand-foot-mouth disease: a case report. *Retin Cases Brief Rep*. 2022; 16(5): 540-2. <http://doi.org/10.1097/ICB.0000000000001046>.
11. Duman R, Duman N, Kutluksaman B et al. A review of unilateral acute idiopathic maculopathy related to hand-foot-mouth disease with a representative case. *Int Ophthalmol*. 2016; 36(3): 445-52. <http://doi.org/10.1007/s10792-015-0147-6>.



12. Agrawal R, Bhan K, Balaggan K et al. Unilateral acute maculopathy associated with adult onset hand, foot and mouth disease: case report and review of literature. *J Ophthalmic Inflamm Infect*. 2015; 5: 2. <http://doi.org/10.1186/s12348-015-0034-3>.
13. Jung CS, Payne JF, Bergstrom CS et al. Multimodality diagnostic imaging in unilateral acute idiopathic maculopathy. *Arch Ophthalmol*. 2012; 130(1): 50-6. <http://doi.org/10.1001/archophthalmol.2011.359>.
14. Acyklowir, aciclovirum – zastosowanie, działanie, opis. Online: <https://www.doz.pl/leki/w1385-Acyklowir>.
15. Corticosteroid (Oral Route, Parenteral Route). Online: <https://www.mayoclinic.org/drugs-supplements/corticosteroid-oral-route-parenteral-route/proper-use/drg-2007049>.

For non-commercial use only

**Authors' contributions:**

Adam Cywiński – idea, development of diagnostics, literature review, writing a manuscript, supplementation of the literature.

Daniela Ferda Lewińska – literature review, description of eye changes in the retina and choroid.

Marcin Gacek – literature review, description of diseases of the hands, feet and mouth.

**Conflict of interest:**

None.

**Financial support:**

None.

**Ethics:**

The content presented in the article complies with the principles of the Helsinki Declaration, EU directives and harmonized requirements for biomedical journals.