

Risk factors for central serous chorioretinopathy

Maciej Gawęcki, MD, PhD^{1,2}

¹ Department of Ophthalmology, Specialist Hospital in Chojnice
Head: Maciej Gawęcki, MD, PhD

Dobry Wzrok Ophthalmological Clinic, Gdańsk
Head: Maciej Gawęcki, MD, PhD



HIGHLIGHTS

The central serous chorioretinopathy (CSCR) onset is related to numerous risk factors, both endogenous and exogenous, which undergo constant research.

Most important exogenous risk factors for the onset of CSCR are steroid intake and high level of emotional stress. Among endogenous risk factors most prominent are male gender, alterations of the level of endogenous corticoids and maladaptive personal traits. CSCR is associated with increased choroidal thickness, however rather independent of refraction error type.

ABSTRACT

Central serous chorioretinopathy is a well-described ocular disorder affecting primarily young individuals. As chronic forms of central serous chorioretinopathy are often leading to significant visual impairment, potential risk factors for its development are constantly analyzed in numerous studies. Review of available research shows that predominant risk factors for central serous chorioretinopathy include male gender, steroid intake, pregnancy, Cushing syndrome, chronic or acute stress, maladaptive personal traits, and increased choroidal thickness. Other factors, such as hypertension, gastric ulcer and reflux or genetic predispositions probably increase the risk of central serous chorioretinopathy onset, but its quantification remains the question of debate.

Key words: central serous chorioretinopathy, risk factors, steroids, hypertension, choroidal thickness

INTRODUCTION

Central serous chorioretinopathy (CSCR) is a common and well described disease, however its pathomechanism still remains a medical mystery. For a few decades CSCR was treated as a benign, self-limiting disorder, that typically resolves spontaneously within a few weeks from disease onset. More thorough research proved that spontaneous resolution occurs in as much as 84% of cases, however the remaining percentage of subjects develop chronic CSCR [1]. Chronic forms of CSCR, usually defined as lasting longer than 4 months, are damaging to the retina [2, 3]. Most of the patients with long-lasting chorioretinopathy end-up with some form of visual impairment, in some cases significant [4, 5]. Numerous research was conducted to identify possible risk factors for the onset or CSCR persistence, nevertheless results are often inconsistent and contradictory. The aim of this descriptive review is to present solid data on these factors basing on available modern ophthalmological literature.

CLASSIFICATION OF RISK FACTORS IN CSCR

Risk factors analyzed in the context of the CSCR incidence could be divided into systemic, referring to genetics, comorbidities, gender, age or drug intake and local, such as axial length of the eyeball (AL), refraction error or choroidal thickness.

Systemic risk factors

Gender

CSCR affects significantly more frequently males than females. Although gender distribution in various studies differs, consequently higher prevalence in males is reported. Haimovici et al. observed ratio 2.8 : 1 males to females ration out in his study cohort [6], which is an observation similar to reported by Spaide (2.6 : 1) [7] and Tittl (2.7 : 1) [8]. Nevertheless, Kitzmann et al. reported annual incidence of CSCR at 9.9 per 10,000 individuals for men and 1.7 per 100,000 for women, which indicates much higher male to female ratio [9].

Genetic predisposition

So far clear link between the presence of specific genes and the occurrence of CSCR has not been established, nevertheless large genetic research on genetic predispositions for CSCR incidence is ongoing. Familial predisposition for CSCR has been described in some studies that incline to seek the genetic background of that disorder [10, 11]. Some reports show relevance of CSCR occurrence to different variants of complement factor H gene [12, 13] or C4B gene [14]. CSCR has also been associated with the age-related macular degeneration (AMD) encoded genes, like ARMS2,

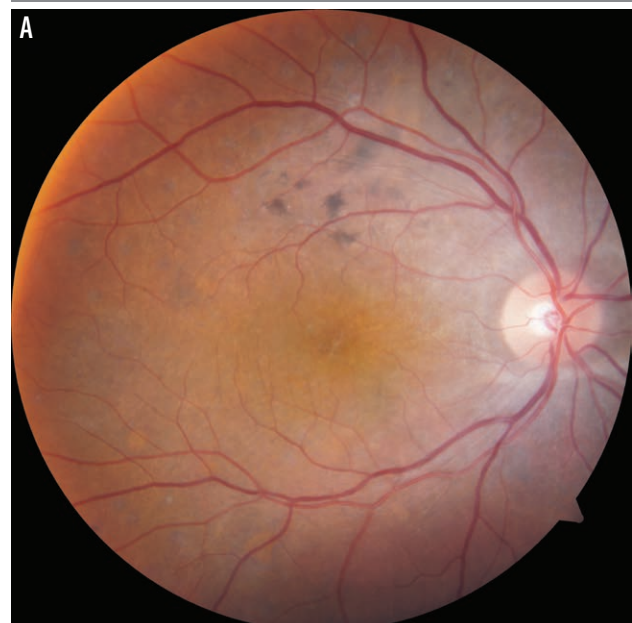
or cadherin 5 [15, 16]. It has to be stated, though, that definite conclusions of genetic studies in CSCR and their practical consequences are yet to be formulated.

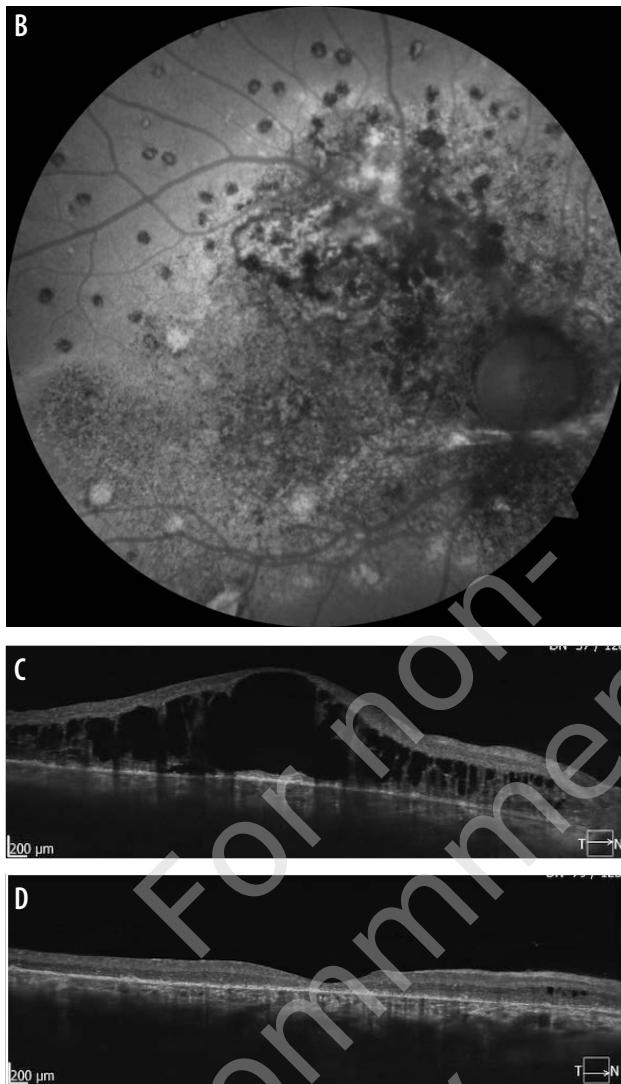
Exogenous steroid intake

Steroid intake is regarded a major risk factor for CSCR development. The occurrence of CSCR was reported after oral and topical application of drugs containing steroids. The highest odds to ratio (OR) of 37.1 for the onset of CSCR in patients taking systemic steroids was observed in a large study by Haimovici et al. It has to be noted, though, that other studies present significantly different numbers. Tittl et al. for the CSCR patients with oral corticosteroid intake report OR at 3.2 [8] and Rim reports hazard ratio (HR) at 1.81 for the patients who had ever used corticosteroids [17]. Interestingly, the onset of CSCR was observed not only after systemic use of steroids but also after topical, e.g., after inhalation, intraarticular injections, or application of dermatological ointments [18–20]. CSCR associated with steroid intake usually has complex morphology evaluated on fluorescein angiography (FA), fundus autofluorescence (FAF) and spectral domain optical coherence tomography (SD-OCT) exams and usually involves multiple leakage points, areas of pigment epithelial detachment (PED) and retinal pigment epithelium (RPE) atrophy.

FIGURE 1

Fundus photograph (A) and fundus autofluorescence (B) of the patient with CSCR associated with long-lasting oral steroid intake. Scan C presents the picture of SD-OCT before photodynamic therapy and scan D after such treatment.





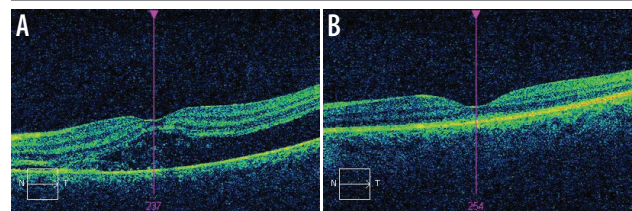
(3/11 in Brinks et al. study) [29]. Additionally, patients with Cushing syndrome present with significantly thicker choroid compared to controls [30].

Alterations in the levels of cortisol and pregnancy related hormones are also believed to cause CSCR episodes in the third trimester of pregnancy [31, 32]. Haimovici et al. calculated the risk for the onset of CSCR in pregnancy at OR 7.1. [6], while in the Kitzmann study pregnant women consisted 9% of all female CSCR patients [9].

The analysis of the abovementioned reports resulted in a proposal of “mineralocorticoid pathway” theory of CSCR pathogenesis that links elevated level of corticoids to fluid retention in the choroid [33]. The theory has consequences in proposed treatment with mineralocorticoid receptor inhibitors, such as oral eplerenone.

FIGURE 2

SD-OCT of the patient with CSCR in the third semester of pregnancy (A) and after delivery (B). Hyperreflective fibrin in subretinal fluid is observed at the first picture, which is a typical finding for the CSCR occurring during pregnancy. Photograph B presents complete resolution of subretinal fluid after delivery, however moderate retinal thinning is noted.



Other drugs

Serous retinal detachments were reported after the use of mitogen-activated protein kinase (MEK) inhibitors used to treat cancer metastases [21], sympathomimetic drugs, such as pseudoephedrine and oxymetazoline used for nasal congestion [22] or phosphodiesterase-5 inhibitors (sildenafil, tadalafil) used to treat erectile dysfunction [23, 24].

Alterations of endogenous corticoids

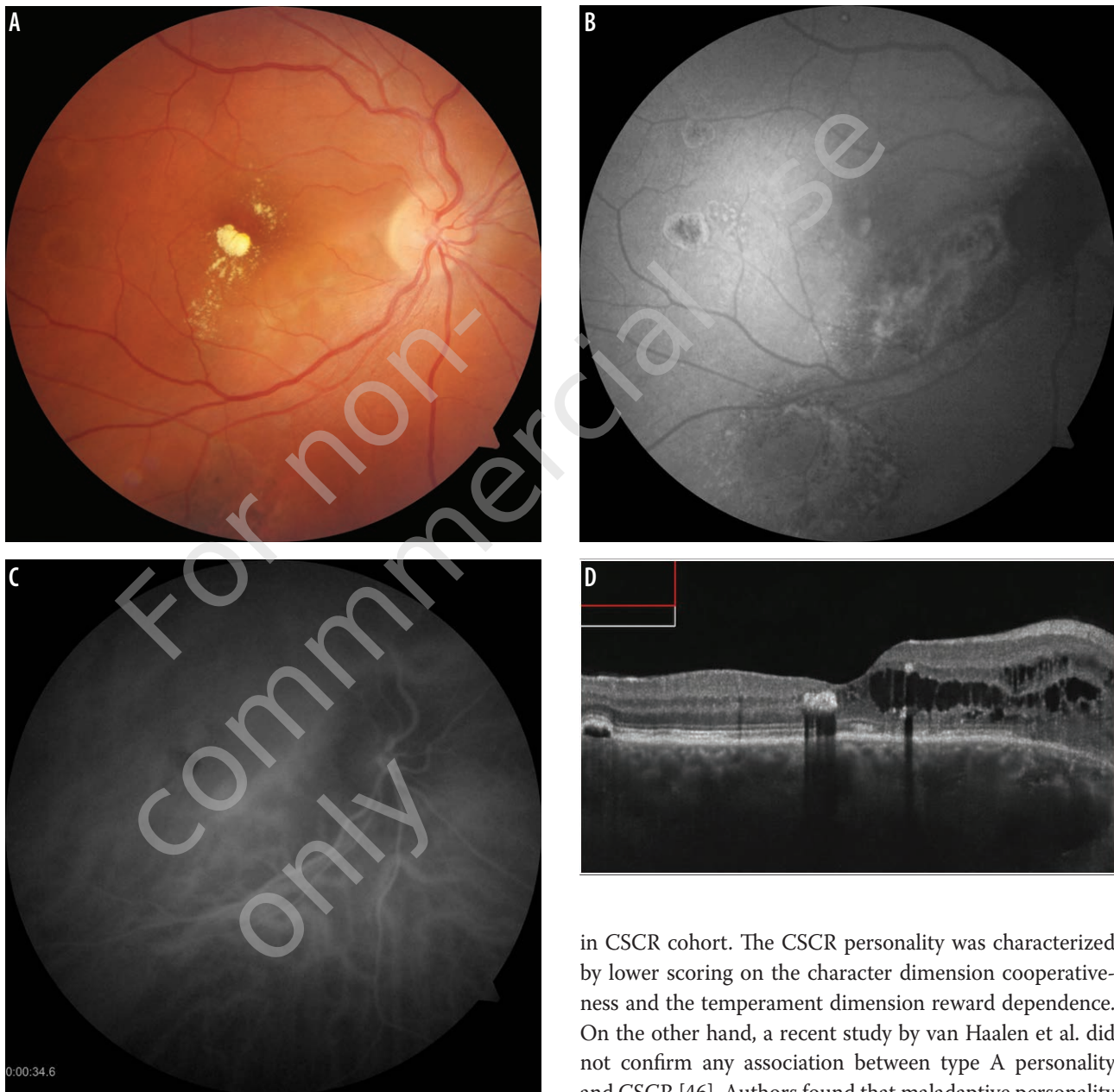
Alterations in the level of endogenous corticosteroids may also play part in CSCR etiopathogenesis. This thesis is supported by a few facts. Firstly, patients with chronic active form of CSCR were reported to have higher levels of endogenous corticoids: androsterone, estrone, etiocholanolone and androstenedione [25]. Some research also show that A type personalities have upraised levels of endogenous corticoids in plasma [26]. A developed hypercortisolemia, i.e., Cushing syndrome, (according to available research) is associated with the risk of CSCR episode [27, 28] and reported to affect high percentage of patients with Cushing syndrome

Stress

Occurrence of CSCR is commonly associated with high level of chronic stress or single stressful episodes as well as sleeping disorders and working on shifts [34–36]. Spahn et al. report higher level of stress a few weeks before the CSCR onset [37]. Gelber et al., in the analysis of 33 CSCR cases found stressful psychological event preceding the onset of symptoms in 91% [35]. Controlled studies of CSCR patients show the higher levels of psychological problems and chronic anxiety as well as perception of more stressful events when compared to healthy individuals [38–41]. Some studies show more intense psychosomatic problems and unfavorable stress coping strategies in acute cases of CSCR compared to chronic CSCR [42]. Generally, results of most of the studies on CSCR indicate the association between the level of stress and the occurrence of CSCR; however, there is still a lack of research that would quantify that. Large meta-analysis of different risk factors in CSCR indicates stress as the prominent factor with the highest OR of 59.35 [43].

FIGURE 3

Color fundus photograph (A), FAF (B), indocyanine green image (C) and SD-OCT scan (D) of the CSCR patient diagnosed with Cushing syndrome. Multiple alterations of the RPE are observed on FAF as well as areas of hyperpermeability of choriocapillaris on ICGA and diffuse macular edema on SD-OCT.



Type of personality

Traditionally, CSCR was associated with type A personality, characterized by competitive drive, sense of urgency, aggressive nature, and hostile temperament. Such characteristics of CSCR patient was first presented by Yannuzzi in 1986 [44]. This finding was confirmed by another study by Conrad et al. [45]. Authors analyzed consecutive CSCR patients and compared them to controls and proved significantly higher emotional distress as measured by the Global Severity Index

in CSCR cohort. The CSCR personality was characterized by lower scoring on the character dimension cooperativeness and the temperament dimension reward dependence. On the other hand, a recent study by van Haalen et al. did not confirm any association between type A personality and CSCR [46]. Authors found that maladaptive personality traits typical for type A personality characteristics are not more frequent in patients with chronic CSCR compared to controls. Modern studies usually abandon a simple classification of personality types in the context of CSCR occurrence. A case control study by Sesar et al. showed that CSCR patients had significantly elevated average reactivity to stressful life events. According to their results, a low level of emotional intelligence may be a factor that contributes to the CSCR occurrence [47]. A large modern meta-analysis of the recent studies on personality disorders occurring in CSCR was conducted by Genovese et al. [40] Authors

concluded, that CSCR patients are not characterized by the prevalence of a formal personality disorder, but typical personality traits that may alter their relationship with others. Patients present with high levels of aggressiveness and anxiety along with low sociability. Authors proposed a model of disease where stress exacerbates prior specific traits in a vicious circle.

Comorbidities

Among systemic disorders analyzed in the context of CSCR onset, hypertension and coronary disease are most frequently mentioned. Tittl et al. reported OR of 2.25 for patients with arterial hypertension to develop CSCR [8]. The association between the CSCR onset and the presence of hypertension and coronary disease was also found by Chatziralli et al. [48], Islam et al. [49] and Eom et al. [50]. Karadag revealed higher 24-hour variabilities of blood pressure in CSCR patients vs. controls.

Gastric problems are often reported in patients with CSCR. A study by Chen et al. pointed out peptic ulcer as a risk factor for the CSCR onset (OR 1.39) [51]. Moreover, according to that study, patients with CSCR had a higher chance to develop peptic ulcer after diagnosis of CSCR (OR 1.43). Patients with CSCR are also considered to be at a higher risk of having gastroesophageal reflux disease compared with controls (OR 6.05) [52]. Additionally, numerous research associate CSCR with the presence of *Helicobacter pylori* in the digestive tract. Some studies show faster subretinal fluid absorption after eradication of that bacteria [53–56], but others do not confirm such finding [57].

Local risk factors

Increased choroidal thickness

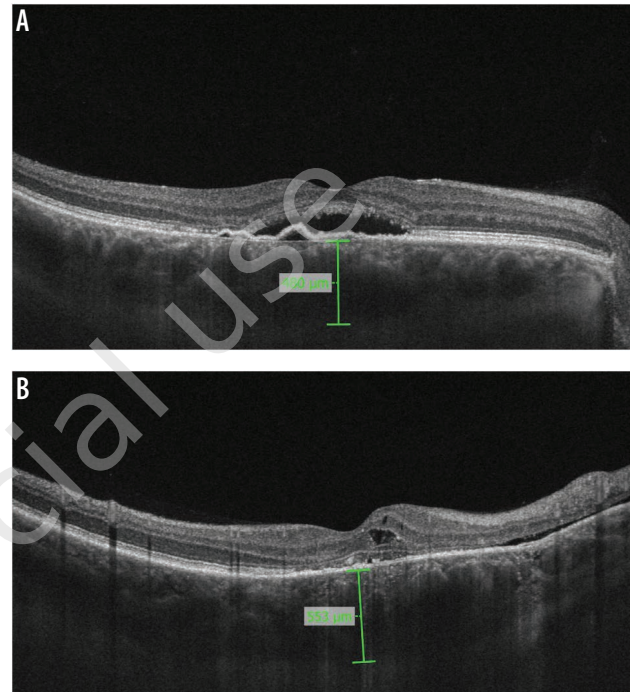
CSCR is nowadays classified as pachychoroid disorder characterized by increased choroidal thickness [58, 59]. Thickened choroid puts an eye at risk of CSCR development that applies also to the fellow CSCR eyes, that typically present also with greater choroidal thickness compared to healthy individuals [3, 60].

Refractive error

Some studies link the occurrence of CSCR to hypermetropia [61] and treat myopia as a protective factor for CSCR [62]. It has to be taken into account, though, that the presence of subretinal fluid in CSCR produces transient retinal elevation which results in hypermetropic shift on refraction testing. Hence, measurements of subjective refraction in active phase of CSCR do not necessarily reflect the actual refractive error. Therefore, results of the studies on risk

FIGURE 4

Increased choroidal thickness on SD-OCT scans (A and B) in two patients.



factors in CSCR based on subjective refraction should be approached with caution.

Axial length

The studies that analyzed association between axial length of the eyeball and the risk of CSCR present inconsistent and often contradictory results. Terao et al. [63] and Oh et al. [64] reported significantly shorter AL in the CSCR eyes vs. controls; however, Arora et al. did not prove such differences [60]. So far, there is no strong evidence to confirm the direct link between the AL and the CSCR risk.

CONCLUSIONS

According to available studies, predominant risk factors for CSCR occurrence include steroid intake, pregnancy, Cushing syndrome, male gender, chronic or acute stress, maladaptive personal traits, and increased choroidal thickness. Other factors, such as comorbidities (hypertension or gastric ulcer and reflux) or genetic predisposition remain the question of debate.

Figures: from the author's own materials.

CORRESPONDENCE

Maciej Gawęcki, MD, PhD

Ophthalmology Clinic „Dobry Wzrok”

80-402 Gdańsk, ul. Kliniczna 1B/2

e-mail: gaweckim@use.pl

ORCID

Maciej Gawęcki – ID – <http://orcid.org/0000-0003-2901-0248>

References

1. Daruich A, Matet A, Marchionno L et al. Acute central serous chorioretinopathy: Factors Influencing Episode Duration. *Retina*. 2017; 37(10): 1905-5.
2. Gawęcki M, Jaszcuk A, Grzybowski A. Short Term Presence of Subretinal Fluid in Central Serous Chorioretinopathy Affects Retinal Thickness and Function. *J Clin Med*. 2020; 9(11): 3429.
3. Gawęcki M, Grzybowski A. Ganglion Cell Loss in the Course of Central Serous Chorioretinopathy. *Ophthalmol Ther*. 2023; 12(1): 517-33.
4. Mrejen S, Balaratnasingam C, Kaden TR et al. Long-term Visual Outcomes and Causes of Vision Loss in Chronic Central Serous Chorioretinopathy. *Ophthalmology*. 2019; 126(4): 576-88.
5. Gawęcki M, Jaszcuk-Maciejewska A, Jurska-Jaśko A et al. Impairment of visual acuity and retinal morphology following resolved chronic central serous chorioretinopathy. *BMC Ophthalmol*. 2019; 19(1): 160.
6. Haimovici R, Koh S, Gagnon DR et al.; Central Serous Chorioretinopathy Case-Control Study Group. Risk factors for central serous chorioretinopathy: a case-control study. *Ophthalmology*. 2004; 111(2): 244-9.
7. Spaide RF, Campeas L, Haas A et al. Central serous chorioretinopathy in younger and older adults. *Ophthalmology*. 1996; 103(12): 2070-9.
8. Tittl MK, Spaide RF, Wong D et al. Systemic findings associated with central serous chorioretinopathy. *Am J Ophthalmol*. 1999; 128(1): 63-8.
9. Kitzmann AS, Pulido JS, Diehl NN et al. The incidence of central serous chorioretinopathy in Olmsted County, Minnesota, 1980-2002. *Ophthalmology*. 2008; 115(1): 169-73.
10. Schellevis RL, van Dijk EHC, Breukink MB et al. Exome sequencing in families with chronic central serous chorioretinopathy. *Mol Genet Genomic Med*. 2019; 7(4): e00576.
11. van Dijk EHC, Schellevis RL, Breukink MB et al. Familial central serous chorioretinopathy. *Retina*. 2019; 39(2): 398-407.
12. Schellevis RL, van Dijk EHC, Breukink MB et al. Role of the Complement System in Chronic Central Serous Chorioretinopathy: A Genome-Wide Association Study. *JAMA Ophthalmol*. 2018; 136(10): 1128-36.
13. Mohabati D, Schellevis RL, van Dijk EHC et al. Genetic risk factors in acute central serous chorioretinopathy. *Retina*. 2019; 39(12): 2303-10.
14. Mohabati D, Schellevis RL, van Dijk EHC et al. Genetic risk factors in severe, nonsevere and acute phenotypes of central serous chorioretinopathy. *Retina*. 2020; 40(9): 1734-41.
15. de Jong EK, Breukink MB, Schellevis RL et al. Chronic central serous chorioretinopathy is associated with genetic variants implicated in age-related macular degeneration. *Ophthalmology*. 2015; 122(3): 562-70.
16. Schubert C, Pryds A, Zeng S et al. Cadherin 5 is regulated by corticosteroids and associated with central serous chorioretinopathy. *Hum Mutat*. 2014; 35(7): 859-67.
17. Rim TH, Kim HS, Kwak J et al. Association of Corticosteroid Use With Incidence of Central Serous Chorioretinopathy in South Korea. *JAMA Ophthalmol*. 2018; 136(10): 1164-9.
18. Fardin B, Weissgold DJ. Central serous chorioretinopathy after inhaled steroid use for post-mycoplasmal bronchospasm. *Br J Ophthalmol*. 2002; 86(9): 1065-6.
19. Chan LY, Adam RS, Adam DN. Localized topical steroid use and central serous retinopathy. *J Dermatolog Treat*. 2016; 27(5): 425-6.
20. Balakrishnan S, Apsingi S, Manjure SB. Sudden loss of visual acuity following intra-articular steroid injection in to the knee joint: a case report. *Cases J*. 2008; 1(1): 428.
21. McCannel TA, Chmielowski B, Finn RS et al. Bilateral subfoveal neurosensory retinal detachment associated with MEK inhibitor use for metastatic cancer. *JAMA Ophthalmol*. 2014; 132(8): 1005-9.
22. Michael JC, Pak J, Pulido J et al. Central serous chorioretinopathy associated with administration of sympathomimetic agents. *Am J Ophthalmol*. 2003; 136(1): 182-5.
23. Asharari KS, Alali NM, Magliyah MS et al. Central Serous Chorioretinopathy Following Oral Use of Adulterated Honey Mixed with Tadalafil: A Case Report. *Int Med Case Rep J*. 2021; 14: 773-6.

24. Mohammadpour M, Khodaparast M, Khorrami-Nejad M. Central serous chorioretinopathy following ingestion of sildenafil citrate. *Clin Optom (Auckl)*. 2019; 11: 73-5.
25. Schellevis RL, Altay L, Kalisingh A et al. Elevated Steroid Hormone Levels in Active Chronic Central Serous Chorioretinopathy. *Invest Ophthalmol Vis Sci*. 2019; 60(10): 3407-13.
26. Zakir SM, Shukla M, Simi ZU et al. Serum cortisol and testosterone levels in idiopathic central serous chorioretinopathy. *Indian J Ophthalmol*. 2009; 57(6): 419-22.
27. van Haalen FM, van Dijk EHC, Dekkers OM et al. Cushing's Syndrome and Hypothalamic-Pituitary-Adrenal Axis Hyperactivity in Chronic Central Serous Chorioretinopathy. *Front Endocrinol (Lausanne)*. 2018; 9: 39.
28. van Dijk EH, Dijkman G, Biermasz NR et al. Chronic central serous chorioretinopathy as a presenting symptom of Cushing syndrome. *Eur J Ophthalmol*. 2016; 26(5): 442-8.
29. Brinks J, van Haalen FM, van Rijssen TJ et al. Central serous chorioretinopathy in active endogenous Cushing's syndrome. *Sci Rep*. 2021; 11(1): 2748.
30. Wang E, Chen S, Yang H et al. Choroidal thickening and pachychoroid in cushing syndrome: Correlation With Endogenous Cortisol Level. *Retina*. 2019; 39(2): 408-14.
31. Sunness JS, Haller JA, Fine SL. Central serous chorioretinopathy and pregnancy. *Arch Ophthalmol*. 1993; 111(3): 360-4.
32. Gawęcki M, Groszewska E. Central serous chorioretinopathy during pregnancy complicated by systemic hypertension – a case report. *Klin Oczna*. 2016; 117(4): 256-9.
33. Behar-Cohen F, Zhao M. Corticosteroids and the retina: a role for the mineralocorticoid receptor. *Curr Opin Neurol*. 2016; 29(1): 49-54.
34. Bousquet E, Dhundass M, Lehmann M et al. Shift Work: A Risk Factor for Central Serous Chorioretinopathy. *Am J Ophthalmol*. 2016; 165: 23-8.
35. Gelber GS, Schatz H. Loss of vision due to central serous chorioretinopathy following psychological stress. *Am J Psychiatry*. 1987; 144(1): 46-50.
36. Ji Y, Li M, Zhang X et al. Poor Sleep Quality Is the Risk Factor for Central Serous Chorioretinopathy. *J Ophthalmol*. 2018; 2018: 9450297.
37. Spahn C, Wiek J, Burger T et al. Psychosomatic aspects in patients with central serous chorioretinopathy. *Br J Ophthalmol*. 2003; 87(6): 704-8.
38. Bazzazi N, Ahmadpanah M, Akbarzadeh S et al. In patients suffering from idiopathic central serous chorioretinopathy, anxiety scores are higher than in healthy controls, but do not vary according to sex or repeated central serous chorioretinopathy. *Neuropsychiatr Dis Treat*. 2015; 11: 1131-6.
39. Sahin A, Bez Y, Kaya MC et al. Psychological distress and poor quality of life in patients with central serous chorioretinopathy. *Semin Ophthalmol*. 2014; 29(2): 73-6.
40. Genovese G, Meduri A, Muscatello MRA et al. Central Serous Chorioretinopathy and Personality Characteristics: A Systematic Review of Scientific Evidence over the Last 10 Years (2010 to 2020). *Medicina (Kaunas)*. 2021; 57(6): 628.
41. Kim YK, Woo SJ, Park KH et al. Association of Central Serous Chorioretinopathy with Psychosocial Factors is Dependent on Its Phase and Subtype. *Korean J Ophthalmol*. 2018; 32(4): 281-9.
42. Lahousen T, Painold A, Luxenberger W et al. Psychological factors associated with acute and chronic central serous chorioretinopathy. *Nord J Psychiatry*. 2016; 70(1): 24-30.
43. Liu B, Deng T, Zhang J. Risk factors for central serous chorioretinopathy: A Systematic Review and Meta-Analysis. *Retina*. 2016; 36(1): 9-19.
44. Yannuzzi LA. Type A behavior and central serous chorioretinopathy. *Trans Am Ophthalmol Soc*. 1986; 84: 799-845.
45. Conrad R, Geiser F, Kleiman A et al. Temperament and character personality profile and illness-related stress in central serous chorioretinopathy. *ScientificWorldJournal*. 2014; 2014: 631687.
46. van Haalen FM, van Dijk EHC, Andela CD et al. Maladaptive personality traits, psychological morbidity and coping strategies in chronic central serous chorioretinopathy. *Acta Ophthalmol*. 2019; 97(4): e572-e579.
47. Sesar AP, Sesar A, Bucan K et al. Personality Traits, Stress, and Emotional Intelligence Associated with Central Serous Chorioretinopathy. *Med Sci Monit*. 2021; 27: e928677.
48. Chatziralli I, Kabanarou SA, Parikakis E et al. Risk Factors for Central Serous Chorioretinopathy: Multivariate Approach in a Case-Control Study. *Curr Eye Res*. 2017; 42(7): 1069-73.
49. Islam QU, Hanif MK, Tareen S. Frequency of Systemic Risk Factors in Central Serous Chorioretinopathy. *J Coll Physicians Surg Pak*. 2016; 26(8): 692-5.
50. Eom Y, Oh J, Kim SW et al. Systemic factors associated with central serous chorioretinopathy in Koreans. *Korean J Ophthalmol*. 2012; 26(4): 260-4.
51. Chen SN, Lian I, Chen YC et al. Increased incidence of peptic ulcer disease in central serous chorioretinopathy patients: a population-based retrospective cohort study. *Retina*. 2015; 35(2): 231-7.

52. Mansuetta CC, Mason JO 3rd, Swanner J et al. An association between central serous chorioretinopathy and gastroesophageal reflux disease. *Am J Ophthalmol.* 2004; 137(6): 1096-100.
53. Mateo-Montoya A, Mauget-Fayse M. *Helicobacter pylori* as a risk factor for central serous chorioretinopathy: Literature review. *World J Gastrointest Pathophysiol.* 2014; 5(3): 355-8.
54. Rahbani-Nobar MB, Javadzadeh A, Ghojzadeh L et al. The effect of *Helicobacter pylori* treatment on remission of idiopathic central serous chorioretinopathy. *Mol Vis.* 2011; 17: 99-103.
55. Casella AM, Berbel RF, Bressanim GL et al. *Helicobacter pylori* as a potential target for the treatment of central serous chorioretinopathy. *Clinics (Sao Paulo).* 2012; 67(9): 1047-52.
56. Zavoloka O, Bezditko P, Lahorzhevska I et al. Clinical efficiency of *Helicobacter pylori* eradication in the treatment of patients with acute central serous chorioretinopathy. *Graefes Arch Clin Exp Ophthalmol.* 2016; 254(9): 1737-42.
57. Dang Y, Mu Y, Zhao M et al. The effect of eradicating *Helicobacter pylori* on idiopathic central serous chorioretinopathy patients. *Ther Clin Risk Manag.* 2013; 9: 355-60.
58. Chung YR, Kim JW, Kim SW et al. Choroidal thickness in patients with central serous chorioretinopathy: Assessment of Haller and Sattler Layers. *Retina.* 2016; 36(9): 1652-7.
59. Hanumunthadu D, van Dijk EHC, Dumpala S et al. Evaluation of Choroidal Layer Thickness in Central Serous Chorioretinopathy. *J Ophthalmic Vis Res.* 2019; 14(2): 164-70.
60. Arora S, Pyare R, Sridharan P et al. Choroidal thickness evaluation of healthy eyes, central serous chorioretinopathy, and fellow eyes using spectral domain optical coherence tomography in Indian population. *Indian J Ophthalmol.* 2016; 64(10): 747-51.
61. Ersoz MG, Arf S, Hocaoglu M et al. Patient characteristics and risk factors for central serous chorioretinopathy: an analysis of 811 patients. *Br J Ophthalmol.* 2019; 103(6): 725-9.
62. Manayath GJ, Arora S, Parikh H et al. Is myopia a protective factor against central serous chorioretinopathy? *Int J Ophthalmol.* 2016; 9(2): 266-70.
63. Terao N, Koizumi H, Kojima K et al. Short axial length and hyperopic refractive error are risk factors of central serous chorioretinopathy. *Br J Ophthalmol.* 2020; 104(9): 1260-5.
64. Oh JH, Oh J, Togloom A et al. Biometric characteristics of eyes with central serous chorioretinopathy. *Invest Ophthalmol Vis Sci.* 2014; 55(3): 1502-8.

Conflict of interest:

None.

Financial support:

None.

Ethics:

The content presented in the article complies with the principles of the Helsinki Declaration, EU directives and harmonized requirements for biomedical journals.