

Diagnosis and treatment of corneal ulcers in the course of systemic autoimmune diseases

Kinga Czarnacka¹, Alicja Chmura-Hołyś¹, Ismael Alsoubie¹,
Oliwia Cwalina¹, Ada Pandey¹, Dominika Prokop¹,
Małgorzata Gawlak¹, Bartosz Kuźlik¹, Katarzyna Guzek¹,
Katarzyna Sajak-Hydzik^{1,2}, Ilona Pawlicka^{1,2}, Agnieszka Piskorz^{1,2},
Maciej Kozak^{1,2}, Anna Roszkowska²

¹ Faculty of Medicine and Health Sciences, Andrzej Frycz Modrzewski Academy in Krakow
Dean: prof. Filip Gołkowski, MD, PhD

² Clinical Ophthalmology Ward, Department of Ophthalmology, Provincial Ophthalmological Hospital in Krakow
Head of Department: prof. Anna Roszkowska, MD, PhD



HIGHLIGHTS

Corneal ulceration is a significant ophthalmologic condition that usually leads to decreased visual acuity. Peripheral ulcerative keratitis is a relatively rare form of corneal ulceration leading to corneal thinning and, sometimes, perforation. If left untreated, it carries the risk of blindness.

ABSTRACT

Peripheral ulcerative keratitis is an inflammatory condition, usually crescent shaped and occurring in the corneal stromal region, where it is always associated with corneal stromal thinning. Peripheral ulcerative keratitis often occurs in the course of rheumatic diseases but is most commonly associated with rheumatoid arthritis. Peripheral ulcerative keratitis is also seen in granulomatosis with polyangiitis, polyarteritis nodosa, relapsing chondritis, and systemic lupus erythematosus. These diseases are analyzed in the article in relation to peripheral ulcerative keratitis with a discussion of individual treatment methods in specific cases.

Key words: peripheral ulcerative keratitis, corneal damage, rheumatoid arthritis, systemic lupus erythematosus, granulomatosis with polyangiitis

INTRODUCTION

The cornea is the first center that focuses the light rays of the optical system of the eye. The visual axis passes through the top of the cornea, and at the border with the sclera is the corneal limbus, which is often affected by immunological changes. Immune complexes are deposited in the limbal capillaries. Keratitis may occur in systemic diseases and may be the result of local or systemic immune mechanisms. A significant percentage of corneal damage occurs in the course of rheumatic diseases against the background of a chronic autoimmune process.

PERIPHERAL ULCERATIVE KERATITIS

Peripheral ulcerative keratitis (PUK), in the course of which ulceration and thinning of the peripheral part of the cornea are observed, may be a consequence of systemic autoimmune diseases. The autoimmune disease in which we can most often observe PUK is rheumatoid arthritis, while it is much less common in systemic lupus erythematosus, granulomatosis with polyangiitis, polyarteritis nodosa or recurrent cartilage. In the pathogenesis of peripheral ulcerative keratitis, mediators of the inflammatory reaction are important, as well as an abnormal response of T lymphocytes with the subsequent production of antibodies responsible for the deposition of immune complexes in the limbus, which can cause vasculitis obliterans with secondary keratitis [1].

DISEASES ASSOCIATED WITH PERIPHERAL ULCERATIVE KERATITIS

Rheumatoid arthritis

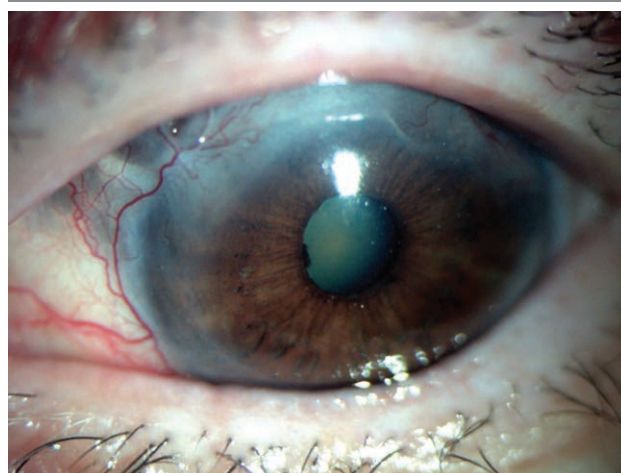
Rheumatoid arthritis (RA, Latin: *arthritis rheumatoidea, polyarthritis chronica evolutiva*) is a systemic disease of unknown cause. The disease is usually associated with the inflammatory disease of the joints, but lesions occur in a number of other organs like lungs, kidneys, small and medium vessels, in diagnosis, as well as in the visual mechanism. Peripheral ulcerative keratitis (PUK) is a rare disease, more common with RA, and a more severe complication of RA [2]. Keratoconjunctivitis, which is the most common manifestation of RA in the test instrument, may also be used for use in the test instrument. It is not uncommon for RA to co-occur with Sjögren's syndrome [3]. Scleritis and episcleritis may also develop in the organ of the visual system. The above-mentioned ocular changes occur in about 30% of patients [3].

When PUK accompanies RA, the first choice treatment is the use of systemic drugs, e.g. glucocorticosteroids (GCS). The use of topical corticosteroids should be avoided because they inhibit the production of collagen fibers, which may re-

sult in corneal perforation. GCS are initially administered at 1 mg/kg/24 h of prednisolone. In the case of a resistant form of the disease with a high risk of blindness, methylprednisolone is recommended at a dose of 1 g/24 h i.v. for 3 consecutive days, followed by oral therapy [4]. Corticosteroids alone are often insufficient and should be administered in combination with immunosuppressants, with cyclophosphamide being the drug of first choice in this group. Other drugs that also have beneficial effects are methotrexate, azathioprine and cyclosporine. The duration of treatment depends on the presence of systemic symptoms of the disease [5, 6]. Always remember to apply lubricants to the outer surface of the eye to help remove proteins and inflammatory mediators. The indication for surgical treatment of PUK (keratoplasty) is corneal perforation [4].

FIGURE 1

Corneal ulcer in a patient with RA.



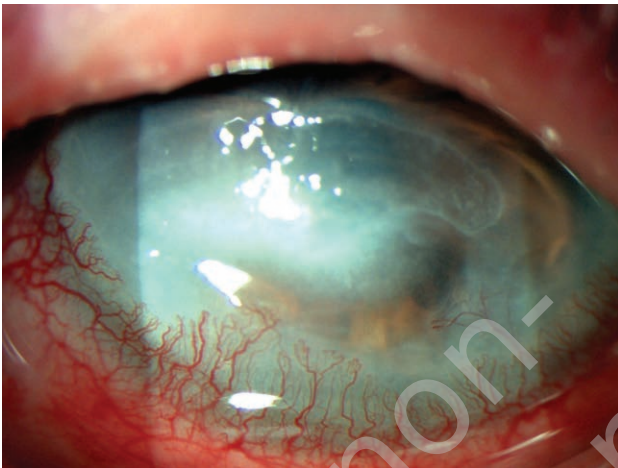Systemic lupus erythematosus

PUK may be related to systemic lupus erythematosus. Systemic lupus erythematosus (SLE) proceeds as a consequence of defects in the immune system. The damage causes inflammation in many tissues and organs. SLE has a wide range of clinical presentations, and ocular symptoms can affect any part of the eye, with a frequency of 33–50% for these symptoms in patients. The most common complications of SLE in the organ of vision include keratoconjunctivitis sicca (dry eye syndrome – 35%), eye movement disorders (30%), and retinopathies (15%). A much less common complication is peripheral ulcerative keratitis, which may occur in the course of active systemic vasculitis, interstitial keratitis, and keratoendotheliitis [7]. Treatment for systemic lupus erythematosus is very similar to treatment for RA. Both systemic treatment: GCS, immunosuppressive drugs and surgical treatment can be used. According to studies,

biological treatment with rituximab and belimumab gives very good results in the treatment of SLE [8].

FIGURE 2

Corneal ulcer.



Granulomatosis with polyangiitis

Granulomatosis with polyangiitis (GPA, *granulomatosis*; formerly *Wegener's granulomatosis*) is a systemic vasculitis that most commonly affects the small vessels and veins in the upper and lower tract as well as the kidney [8]. There is also a limited form, which is characterized by the occupation of only one or two organs with no involvement of the kidneys. Peripheral ulcerative keratitis in granulomatosis with tract inflammation proceed in the earlier stages of the disease and is its first symptom [9]. PUK can be detected in GPA up to 6 months after the diagnosis of the disease in contrast to RA, where it is a late diagnosis, come about on average of 19 years after the diagnosis is confirmed [10]. Coexistence of GPA in PUK can be a dangerous component of vessels [11]. In symptomatic granulomatosis, ocular symptoms are common, accounting for 16% of cases. Alternate signs of children differing from others in occupation of vision [12].

Topical treatment for granulomatosis associated with PUK is ineffective, while surgical treatment is effective but may be difficult in refractory GPA. The best solution in this case is excision of the conjunctiva with complementary cryotherapy, combined with systemic treatment with cyclophosphamide and intravenous and oral corticosteroids [8].

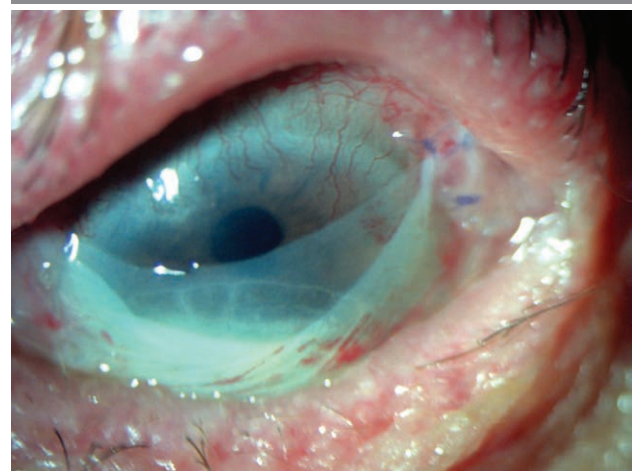
TREATMENT

The main goals in the treatment of PUK are: reduction of inflammation, promotion of ulcer healing, and prevention of corneal infection and perforation. Topical pharmacological, surgical and systemic treatment may be considered, al-

though in some cases local treatment is sufficient. Then topical GCS, antibiotics, immunosuppressive drugs are used in combination with surgical resection of the conjunctiva and inflamed areas, and amniotic membrane transplantation. In a situation where there is a risk of perforation, cyanoacrylate glue can be used, which we apply to the portal of the ulcer. Topical corticosteroids do not cause systemic side effects, but may lead to inhibition of wound healing. Immunosuppressants, such as topical cyclosporine, avoid nephrotoxicity. Local pharmacological treatment should be considered individually, as in some cases it may cause corneal perforation. GCS and immunosuppressants are administered in systemic treatment. GCS therapy should be started with a dose of prednisone 1 mg/kg/24 h or methylprednisolone 1 g/24 h for 3 days. If there is no improvement, immunosuppressants such as cyclophosphamide, methotrexate, azathioprine or cyclosporine are added. Appropriate treatment and doses should be considered on an individual basis. Surgical intervention is indicated in the case of corneal perforation or excessive thinning. Several types of surgery can be considered: layered, penetrating, or crescent keratoplasty [13]. Penetrating keratoplasty is required for large perforations (diameter ≥ 3 mm) [8]. During treatment and convalescence, the patient should be under constant supervision in the event of possible relapses, infection, disease progression or graft rejection. Regardless of which treatment options the patient undergoes, eye lubricants should be used to remove harmful proteins and inflammatory mediators [4].

FIGURE 3

Amniotic membrane.



CONCLUSIONS

In this paper, the subject of peripheral ulcerative keratitis in the course of systemic autoimmune diseases, such as: rheumatoid arthritis, systemic lupus erythematosus and granu-

lomatosis with polyangiitis was developed. In addition, on the basis of the literature, direct and indirect methods of

PUK treatment were presented, the selection of which depends on the stage of the disease.

Figures: from the author's own materials

CORRESPONDENCE

Kinga Czarnacka MSc

Faculty of Medicine and Health Sciences, Andrzej Frycz Modrzewski Academy in Krakow
30-705 Kraków, ul. Gustawa Herlinga-Grudzińskiego 1
e-mail: kinga.czarnacka@gmail.com

ORCID

Ada Pandey – ID – <http://orcid.org/0000-0001-9467-1005>
Alicja Chmura-Hołyś – ID – <http://orcid.org/0000-0003-0733-1542>
Dominika Prokop – ID – <http://orcid.org/0000-0001-7318-7716>
Oliwia Cwalina – ID – <http://orcid.org/0000-0002-7071-0273>
Ismael Alsoubie – ID – <http://orcid.org/0000-00020974-3025>
Bartosz Kuźlik – ID – <http://orcid.org/0000-0001-8028-5525>
Katarzyna Guzek – ID – <http://orcid.org/0000-0003-1790-8667>
Kinga Czarnacka – ID – <http://orcid.org/0000-0002-6889-6507>
Małgorzata Gawlak – ID – <http://orcid.org/0000-0003-4573-1379>
Maciej Kozak – ID – <http://orcid.org/0000-0001-7993-2588>
Ilona Pawlicka – ID – <http://orcid.org/0000-0003-1556-7678>
Katarzyna Sajak-Hydzyk – ID – <http://orcid.org/0000-0002-1973-2717>
Agnieszka Piskorz – ID – <http://orcid.org/0000-0003-4553-0497>
Anna Roszkowska – ID – <http://orcid.org/0000-0002-8083-3437>

References

1. Gupta Y, Kishore A, Kumari P et al. Peripheral ulcerative keratitis. *Surv Ophthalmol.* 2021; 66(6): 977-98. <http://doi.org/10.1016/j.survophthal.2021.02.013>.
2. Bonnet I, Rousseau A, Duraffour P et al. Efficacy and safety of rituximab in peripheral ulcerative keratitis associated with rheumatoid arthritis. *RMD Open.* 2021; 7(1): e001472. <http://doi.org/10.1136/rmdopen-2020-001472>.
3. Bhamra MS, Gondal I, Amarnani A et al. Ocular Manifestations of Rheumatoid Arthritis: Implications of Recent Clinical Trials. *Int J Clin Res Trials.* 2019; 4(2): 139. <http://doi.org/10.15344/2456-8007/2019/139>.
4. Benchérifa S, Amine B, El Binoune I et al. Two cases of perforated corneal ulcers complicating rheumatoid arthritis treated successfully by biological therapy. *BMC Rheumatol.* 2020; 4: 6. <http://doi.org/10.1186/s41927-019-0108-1>.
5. Squirrel DM, Winfield J, Amos RS. Peripheral ulcerative keratitis 'corneal melt' and rheumatoid arthritis: a case series. *Rheumatology.* 1999; 38(12): 1245-8.
6. Sule A, Balakrishnan C, Gaitonde S et al. Rheumatoid corneal melt. *Rheumatology.* 2002; 41(6): 705-6.
7. Palejwala NV, Walia HS, Yeh S. Ocular manifestations of systemic lupus erythematosus: a review of the literature. *Autoimmune Dis.* 2012; 2012: 290898. <http://doi.org/10.1155/2012/290898>.
8. Cao Y, Zhang W, Wu J et al. Peripheral Ulcerative Keratitis Associated with Autoimmune Disease: Pathogenesis and Treatment. *J Ophthalmol.* 2017; 2017: 7298026. <http://doi.org/10.1155/2017/7298026>.
9. Gomes BA, Santhiago MR, Jorge PA et al. Corneal involvement in systemic inflammatory diseases. *Eye Contact Lens.* 2015; 41(3): 141-4. <http://doi.org/10.1097/ICL.0000000000000141>.
10. McKibbin M, Isaacs JD, Morrell AJ. Incidence of corneal melting in association with systemic disease in the Yorkshire Region, 1995-7. *Br J Ophthalmol.* 1999; 83(8): 941-3. <http://doi.org/10.1136/bjo.83.8.941>.
11. Luqmani RA, Bacon PA, Beaman M et al. Classical versus non-renal Wegener's granulomatosis. *Q J Med.* 1994; 87(3): 161-7.
12. Vislislis JM, Lenci L, Goins KM. Peripheral Ulcerative Keratitis (PUK). *EyeRounds.org.* August 25, 2014. <http://EyeRounds.org/cases/194-PUK.htm> (access: 16.02.2023).
13. Feldman BH, Stenz JM, Bunya VY et al. Peripheral Ulcerative Keratitis, June 21, 2022, ICD9 370.00.

For non-commercial use only

Authors' contributions:

All authors have equal contribution to the paper.

Conflict of interest:

None.

Financial support:

None.

Ethics:

The content presented in the article complies with the principles of the Helsinki Declaration, EU directives and harmonized requirements for biomedical journals.