

Floppy eyelid syndrome as an ocular condition associated with increased body mass index – classification, diagnostics and treatment

Paulina Szabelska, Waław Ofman, Dominika Białas,
Radosław Różycki, Joanna Gołębiowska

Department of Ophthalmology, Military Institute of Aviation Medicine, Warsaw
Head: Radosław Różycki, MD, PhD



HIGHLIGHTS

Floppy eyelid syndrome affects a lot of patients, especially in a group with concomitant obesity. The most important part of the diagnostics is the collection of medical history and making adequate clinical tests. Early diagnosis and selection of proper treatment method is a complex process and it is crucial to improve the patients' quality of life.

ABSTRACT

Floppy eyelid syndrome is a common ophthalmic condition characterized by a sagging eyelid, which causes its spontaneous wrinkling during sleep. It can be a result of local and systemic diseases. A characteristic group of patients who suffer from floppy eyelid syndrome are middle-aged men with an increased body mass index. Obesity in this group of patients is recognized as the strongest risk factor for the occurrence of obstructive sleep apnea syndrome. The aim of the article is to review the diagnostic methods that are used in the case of floppy eyelid syndrome. The paper also discusses therapeutic methods including surgical techniques.

Key words: floppy eyelid syndrome, FES, body mass index, obesity, eyelid surgery, obstructive sleep apnea, OSAHS

INTRODUCTION

The definition of floppy eyelid syndrome (FES) was first used in 1981 by Culbertson and Ostler. The authors presented 11 cases (obese middle-aged men) in which the easily reversed upper eyelid with concomitant papillary conjunctivitis was confirmed. They hypothesized that an elevated body mass index (BMI) in patients with capsizes of the upper eyelid during sleep can cause local inflammation [1].

Estimates of the FES prevalence varies depending on the source and range from 2.3% to 3.8% [2]. Available literature suggest that FES is more common than is realised. Problems related to determining the exact epidemiology data of this disease result from the lack of its unambiguous definition and diagnostic criteria.

Flaccidity of the eyelids may result from involution changes occurring both locally and systemically. It usually occurs in middle-aged men with a BMI > 30 kg/m² [1, 3, 4]. Obesity in this group of patients is considered the main risk factor for obstructive sleep apnea syndrome (OSAHS). The authors said that there is a strong correlation between FES, obesity and OSAHS [5–8]. Recent data from the United States and Europe suggest that 14–49% of middle-aged men have clinically relevant symptoms of OSAHS [9]. In one study, among 431 patients diagnosed with OSAHS, FES was confirmed in about 50% of them. Publications also indicate that the higher degree of OSAHS is correlated with the greater probability of FES [8, 10].

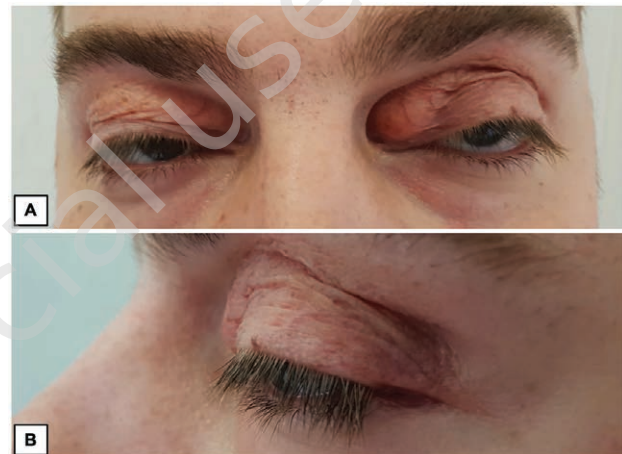Some of the patients have suffered from positional sleep apnea (POSA), which means that they tend to have apnea when lying on their backs. They avoid the supine position by laying on their side [11]. Due to this position their eyelids are spontaneously wrinkled during the sleep (fig. 1).

It is unknown what the main cause of FES is. The authors suggested that there could be a genetic predisposition to the disease. Culbertson and Ostler supposed that spontaneous nocturnal eversion was the main pathogenetic factor [1]. Later, Parunovic reported that nocturnal taping caused distinct relief of the subjective problem, but the keratitis slightly changed [4].

FES mainly affects the upper eyelids, but the lower can also be included in the clinical picture. Patients present easily bending and deforming of the eyelids, especially in the base area. They seem to be soft, rubbery and easily folded (fig. 2) [1, 4, 12].

FIGURE 2

Patient with FES. A. Frontal position. B. Left side position.



FES can be an isolated or co-occurring condition connected with other ocular disorders. Therefore, in medical terminology, we distinguish:

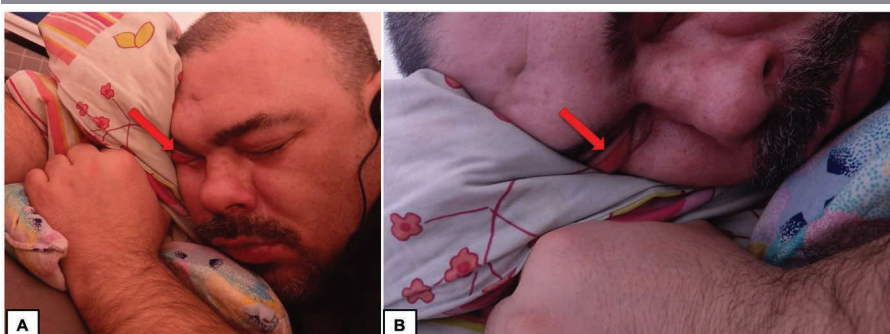
- lax eyelid condition (LAC) – FES as an isolated disease
- lax eyelid syndrome (LES) – FES associated with eye surface disorders such as papillary conjunctivitis or dry eyes [8].

CLASSIFICATION

Several FES classifications are available in the literature [8]. Some of them are based on the visibility of the upper tarsal conjunctiva (UTC) during the examination, after eversion of the eyelid. Others are based on the time at which the eyelid remains inverted or on the presence of irritation of the an-

FIGURE 1

Sleep position in patient with OSAHS. A. Patient lying on the right side. B. Everted upper eyelid of the right side (marked by red arrows).



terior segment of the eye. The available classifications are shown in table 1.

TABLE 1

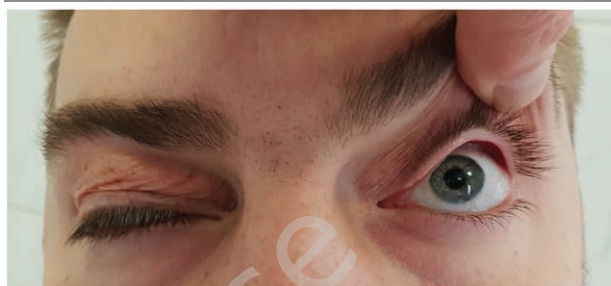
FES classifications according to different authors.

Classification	Stage	Clinical features
Liu et al. (based on UTC visibility)	Mild	UTC visible in less than 1/3
	Moderate	UTC visible from 1/3 to 1/2
	Severe	UTC visible in more than 1/2
Yeung et al. (based on UTC visibility)	Mild	UTC visible from 1/3 to 1/2
	Moderate	UTC visible in more than 1/2
	Severe	spontaneous eversion of the upper eyelid on minimal eyelid retraction or on forced eyelid closure with fully visible UTC
Medel et al. (based on the additional local symptoms presence)	Grade 0	no symptoms of conjunctivitis or sporadic symptoms and minimal papillary reaction
	Grade 1	frequent symptoms, papillary reaction and occasional keratitis, which can be easily managed with local treatment
	Grade 2	constant symptoms and significant papillary reaction with a concomitant corneal disease
Beis et al. (based on the duration of eyelid eversion)	-	the eyelid remains easily everted for up to 6 seconds despite the position of the eye downwards or voluntary orbicular muscle contraction
	-	the eyelid remains spontaneously everted for more than 6 seconds despite the position of the eye downwards or voluntary orbicular muscle contraction

Despite the proposals of several classification systems to assess the degree of FES advancement, the gold standard remains the subjective assessment of upper eyelid eversion, with the evaluation of other clinical features (fig. 3) [8]. There is no single classification that describes all clinical symptoms of FES. In the assessment (include disease severity), there are no scales taking into account the excessive flabbiness of the eyelids skin (dermatochalasis), unwinding of the eyelids (ectropion), entropion and eyelid or eyelashes ptosis presence, as well as the indicators of eye surface disorders.

FIGURE 3

Subjective assessment of the left upper eyelid eversion.

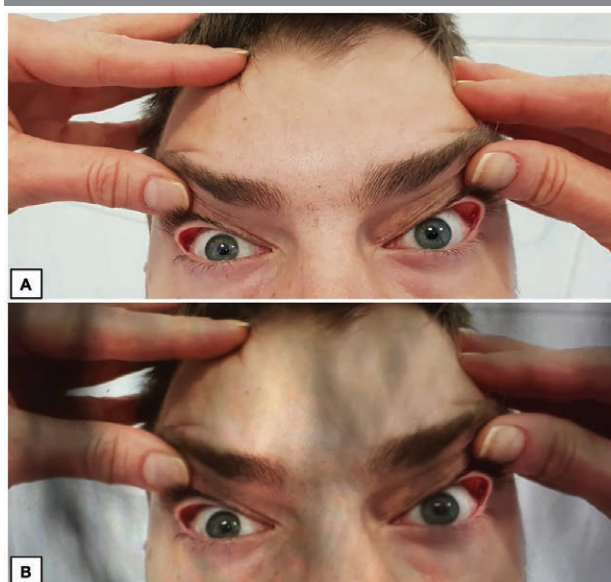


DIAGNOSTICS

In the diagnosis of FES, it is very important to collect the medical history, with particular emphasis on the past ophthalmic infections, presence of purulent or mucous discharge in the conjunctival sac, foreign body sensation or deterioration of visual acuity. Patients often complain of drooping eyelids and the vision “as through the eyelashes” (fig. 4).

FIGURE 4

Picture of vertical lid distraction test in patient with FES. A. Seen by patient without eyelids abnormalities. B. Seen by patient with FES – vision “as through the eyelashes”.



During the basic examination, the physician should pay attention to the co-occurrence of obesity. If there are no clinical features of increased BMI, attention should be paid to bariatric surgery in the previous medical history. All patients should also be examined for possible OSAHS symptoms.

Then, physical examination has to be carried out, including measurements of the visual system. Eye surface and acces-

sory visual structures such as eyelids should be evaluated in a slit lamp. During assessment, attention has to be paid to the features that may indicate chronic irritation or inflammation within the anterior segment of the eye and other symptoms. The clinical manifestations that can be observed at the appointment are summarized in table 2.

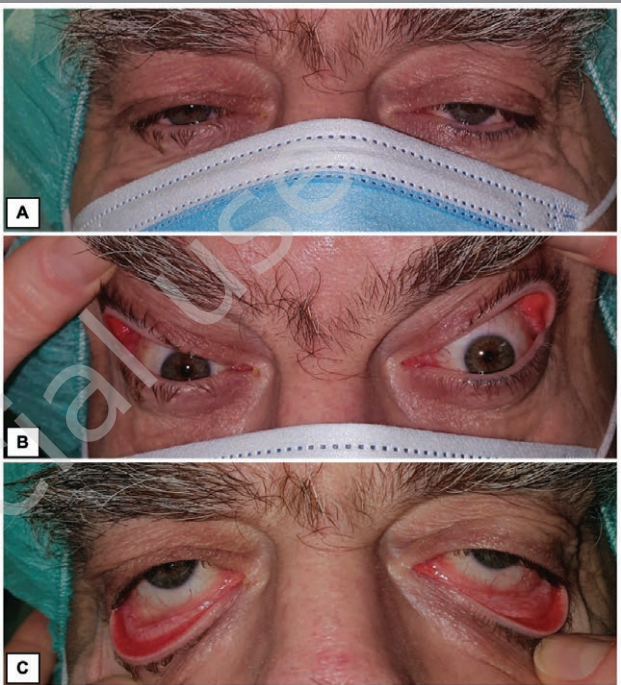TABLE 2
 Clinical signs of FES (based on AAO data) [13].

Clinical signs	
Chronic irritation and inflammation	Others
<ul style="list-style-type: none"> • lash debris (scurf) • tear break-up time (TBUT) < 10 sec. • superior tarsal conjunctival injection • conjunctival papillary reaction presence • punctate fluorescein staining of superior cornea or conjunctiva • conjunctival scrapings reveal predominance of polymorphonuclear leukocytes with variable amounts of eosinophils and lymphocytes • atrophic, soft, and rubbery tarsal plate that can be folded on itself • stringy mucoid conjunctival discharge 	<ul style="list-style-type: none"> • lax upper eyelid • brow easily pulled toward • easily everted and rubbery consistency of the eyelid • frequent horizontal laxity of lower eyelid • eyelid ptosis • dermatochalasis • lacrimal gland prolapse • Meibomian gland dysfunction (MGD) • dry eye syndrome (DES)

The FES diagnosis has to be made on the signs and symptoms, as well as the on the results of diagnostic tests. Additional tests necessary to make a FES diagnosis include: “vertical lid pull/distraction” test – performed with a millimetre ruler. It consists in placing the thumb on the outer 1/3 of the upper eyelid and brings it superiorly and laterally. During the examination patient is in the primary position of gaze. The measurement is made during the maximal vertical pull. In a similar way, the test can be also performed for the lower eyelid (fig. 5).

- “upper eyelid distraction distance” (UEDA) test – performed with a caliper. Following distraction of the upper eyelid, the physician measures the distance from the posterior margin of the upper lid to the bulbar conjunctiva. During the examination patient is in the primary position of downgaze
- “vertical hyperlaxity” test – performed with the millimetre ruler. The researcher measures the maximum distance between the palpebral rim and the centre of the pupil following vertical traction of the upper eyelid
- “upper horizontal distraction” test – performed with the millimetre ruler. It consists in reversing the upper eyelid and recording its duration. During the examination, the physician measure the distance between the anterior corneal pole and the anterior distracted upper eyelid

FIGURE 5
 Patient with floppy eyelids. A. Initial position. B. Vertical lid distraction test of the upper eyelids. C. Vertical lid distraction test of the lower eyelids.



- “time evaluation” test – it measures time in seconds. During the test the duration of eyelid eversion is assessed following manual upper eyelid eversion in the downgaze. It is performed to quantify FES severity
- “snapback” test – it can be referred to as positive or negative. The test involves grasping the eyelid, pulling it off the eye, and letting the lid go. The test result is positive if the time required for the lid to return its proper position is greater than 2 seconds or the patient needs to blink, then the lid will be recorded as positive for laxity. It is used to assess the eyelid tone and the horizontal laxity severity. It is usually performed only for the lower eyelid [8].

All these tests have some limitations, such as the results of the measurements depending on the force used by the researcher carrying out the test.

As a response to these limitations, Karger et al. and Sward have introduced two devices – a “strain gauge device” and “laxometer”, which are able to measure the force required to vertically displace the upper eyelid [2, 14]. These examinations are more precise and reproducible, but their limited availability makes them less practical and have limited usefulness in clinical practice.

In addition to the ophthalmological examination, tests of sleep quality and confirmed OSAHS may be crucial in making a proper diagnosis.

Differential diagnosis of FES includes ophthalmic conditions such as:

- retracted eyelids
- hypotrophy and eyebrow drooping
- chronic inflammation of the eyelid rim
- MGD
- complications of contact lenses use (including giant papillary conjunctivitis)
- keratitis and conjunctivitis based on various etiologies
- ptosis (e.g. neurogenic, myopathic or mechanical etiology)
- dermatochalasis
- ectropion
- DES [8, 13].

TREATMENT

One of the FES treatment methods is topical drugs that aim to relieve the disease symptoms, as well as maintain the integrity of the eye surface. In clinical practice, eye shields, wrapping the eyelid for the night, topical moisturizing drops or ointments are used. The patient should be advised to not rub the eyelids, which may cause their sagging to intensify [1, 4].

Recent clinical studies report that the use of 0.03% bimatoprost (prostaglandin analogue) may be considered as an alternative to surgical treatment. As a side effect of the long-term use of this drug, we can observe eyelid retraction or tension, dermatochalasis involution and deepening of the upper eyelid sulcus, which reduces the extensibility and flaccidity of the eyelids and relieves the symptoms of FES [15].

An alternative to conservative treatment is eyelid surgery. The first surgical techniques used in FES were the full thickness “wedge excision” of the eyelid and “lateral tarsal strip” method. These treatment methods were designed to restore the correct anatomy of the eyelid [16]. In the course of further research, they were modified and improved.

In 2019 Waldie et al., proposed the technique called “FES-plasty”, in which the periosteal flap based on the lower and lateral rim of the orbit is applied to the anterior surface of the

upper tarsal plate and combined with the procedure of shortening of the upper eyelid. Literature data indicates that the “FESplasty” method provided better long-term outcomes in comparison with previous surgical procedures [17].

In 1997, McNab described several cases of resolution with eyelid flaccidity in OSAHS patients due to the therapy with positive airway pressure [5]. That means, that treatment of comorbidities can directly improve FES-related discomfort. In addition to ophthalmic treatment, patients with FES should be evaluated and treated for obesity and OSAHS to reduce overall morbidity and systemic mortality.

CONCLUSIONS

FES is a relatively common ocular condition. Unfortunately, the entity of this disease is insufficiently understood. Because of that, it can be misdiagnosed or inadequate diagnosed due to the lack of unambiguous criteria for its confirmation. An important challenge for the clinical tasks should be to set up the diagnostic algorithms and make a clear definition and the criteria for the FES diagnosis. Early and accurate identification will make it possible to undertake proper treatment of floppy eyelids.

FES should be classified in clinical practice not only as an ophthalmological disease, but also taking it into account with the concomitant systemic diseases. The presence of floppy eyelids in a group of obese patients with associated OSAHS can be an important symptom, helping to direct patients to appropriate diagnostic and therapeutic pathways. Due to the FES association with obesity and OSAHS, its diagnosis is crucial to prevent severe general diseases as well as serious conditions that threaten vision and life. FES is a disease bordering on various medical specialties and that is why it is important to cover patients with multidisciplinary medical care. Obesity, which is one of the main risk factors for both FES and OSAHS, is common worldwide, and that is why its diagnostics and treatment entity is a critical issue in the ophthalmologists’ clinical practice.

Figures: from the author’s own materials.

CORRESPONDENCE

Dominika Białas, MD

Ophthalmology Clinic, Military Institute of Aviation Medicine
01-755 Warszawa, ul. Zygmunta Krasińskiego 54/56
e-mail: dominikabialas01@gmail.com

ORCID

Paulina Szabelska – ID – <http://orcid.org/0000-0002-6216-0646>

Wacław Ofman – ID – <http://orcid.org/0000-0002-6547-3429>

Dominika Białas – ID – <http://orcid.org/0000-0002-0082-9105>

Joanna Gołębiowska – ID – <http://orcid.org/0000-0002-3013-4363>

Radosław Różycki – ID – <http://orcid.org/0000-0001-7040-026X>

References

1. Culbertson WW, Ostler HB. The floppy eyelid syndrome. *Am J Ophthalmol.* 1981; 92(4): 568-75. [http://doi.org/10.1016/0002-9394\(81\)90652-8](http://doi.org/10.1016/0002-9394(81)90652-8).
2. Karger RA, White WA, Park WC et al. Prevalence of floppy eyelid syndrome in obstructive sleep apnea-hypopnea syndrome. *Ophthalmology.* 2006; 113(9): 1669-74. <http://doi.org/10.1016/j.ophtha.2006.02.053>.
3. Fowler AM, Dutton JJ. Floppy eyelid syndrome as a subset of lax eyelid conditions: relationships and clinical relevance (an ASOPRS thesis). *Ophthalmic Plast Reconstr Surg.* 2010; 26(3): 195-204. <http://doi.org/10.1097/IOP.0b013e3181b9e37e>.
4. Parunović A. Floppy eyelid syndrome. *Br J Ophthalmol.* 1983; 67(4): 264-6. <http://doi.org/10.1136/bjo.67.4.264>.
5. McNab AA. Floppy eyelid syndrome and obstructive sleep apnea. *Ophthalmic Plast Reconstr Surg.* 1997; 13(2): 98-114. <http://doi.org/10.1097/00002341-199706000-00005>.
6. Sleep-related breathing disorders in adults: recommendations for syndrome definition and measurement techniques in clinical research. The Report of an American Academy of Sleep Medicine Task Force. *Sleep.* 1999; 22(5): 667-89.
7. Cho JH, Choi JH, Suh JD et al. Comparison of Anthropometric Data Between Asian and Caucasian Patients With Obstructive Sleep Apnea: A Meta-Analysis. *Clin Exp Otorhinolaryngol.* 2016; 9(1): 1-7. <http://doi.org/10.21053/ceo.2016.9.1.1>.
8. De Gregorio A, Cerini A, Scala A et al. Floppy eyelid, an under-diagnosed syndrome: a review of demographics, pathogenesis, and treatment. *Ther Adv Ophthalmol.* 2021; 13: 25158414211059247. <http://doi.org/10.1177/25158414211059247>.
9. Garvey JF, Pengo MF, Drakatos P et al. Epidemiological aspects of obstructive sleep apnea. *J Thorac Dis.* 2015; 7(5): 920-9. <http://doi.org/10.3978/j.issn.2072-1439.2015.04.52>.
10. Pedrotti E, Demasi CL, Bruni E et al. Prevalence and risk factors of eye diseases in adult patients with obstructive sleep apnoea: results from the SLE.E.PY cohort study. *BMJ Open.* 2017; 7(10): e016142. <http://doi.org/10.1136/bmjopen-2017-016142>.
11. Srijithesh PR, Aghoram R, Goel A et al. Positional therapy for obstructive sleep apnoea. *Cochrane Database Syst Rev.* 2019; 5(5): CD010990. <http://doi.org/10.1002/14651858.CD010990.pub2>.
12. Brown MD, Potter JW. Floppy eyelid syndrome: a case report and clinical review. *J Am Optom Assoc.* 1992; 63(5): 309-14.
13. Lauer SA. Floppy Eyelid Syndrome. *American Academy of Ophthalmology, EyeWiki.* <https://www.aaopt.org/oculoplastics-center/floppy-eyelid-syndrome-4>. (access: 30.10.2022).
14. Sward M, Kirk C, Kumar S et al. Lax eyelid syndrome (LES), obstructive sleep apnea (OSA), and ocular surface inflammation. *Ocul Surf.* 2018; 16(3): 331-6. <http://doi.org/10.1016/j.jtos.2018.04.003>. Epub 2018.
15. De Gregorio A, Pedrotti E, Stevan G et al. Floppy eyelid syndrome and ectropion improvement after 1 month of 0.03% Bimatoprost topical therapy. *Am J Ophthalmol Case Rep.* 2020; 20: 100938. <http://doi.org/10.1016/j.ajoc.2020.100938>.
16. Dutton JJ. Surgical management of floppy eyelid syndrome. *Am J Ophthalmol.* 1985; 99(5): 557-60. [http://doi.org/10.1016/s0002-9394\(14\)77957-7](http://doi.org/10.1016/s0002-9394(14)77957-7).
17. Waldie AM, Francis IC, Coroneo MT et al. Floppy eyelid syndrome “plasty” procedure: Employment of a periosteal transposition flap for surgery of floppy eyelid syndrome. *Clin Exp Ophthalmol.* 2019; 47(7): 864-70. <http://doi.org/10.1111/ceo.13560>.

Authors' contributions:

Paulina Szabelska: 60%; Waclaw Ofman: 5%; Dominika Białas: 20%; Radosław Różycki: 5%; Joanna Gołębiowska: 10%.

Conflict of interest:

None.

Financial support:

None.

Ethics:

The content presented in the article complies with the principles of the Helsinki Declaration, EU directives and harmonized requirements for biomedical journals.