

Bilateral anterior lenticonus in the course of Alport syndrome – a case report



Ada Pandey¹, Justyna Gugnowska¹, Angelika Kruszyńska¹,
Oliwia Cwalina¹, Kinga Czarnacka¹, Małgorzata Gawlak¹,
Alicja Chmura¹, Maciej Kozak^{1,2}, Katarzyna Sajak-Hydzyk^{1,2},
Ilona Pawlicka^{1,2}

¹ Faculty of Medicine and Health Sciences, Andrzej Frycz Modrzewski Academy in Krakow
Dean: prof. Filip Gołkowski, MD, PhD

² Clinical Ophthalmology Department, Provincial Ophthalmological Hospital in Krakow
Director: Katarzyna Sajak-Hydzyk, MD, PhD

HIGHLIGHTS

Progressive deteriorating eyesight and the ineffectiveness of eyeglass treatment may be a reason to start diagnosing a genetic disease, such as Alport's syndrome, and change the treatment method.

ABSTRACT

Alport syndrome is a genetic disease that leads not only to chronic kidney disease but also to loss of hearing and vision. The article presents a case of a 34-year-old with anterior lenticonus in Alport syndrome. Due to the progressive deterioration of vision and the ineffectiveness of the selection of glasses, he was qualified for the surgery – the phacoemulsification for immature cataract of distorted lenses.

Key words: Alport syndrome, genetic disease, anterior lenticonus

INTRODUCTION

Alport syndrome is a genetically determined disease. Its occurrence is caused by a mutation in the *COL4A5* gene, encoding one of the collagen chains of type IV [1]. It is a rare condition and occurs in about 1/10,000 of live babies. Nevertheless, it is the most common of congenital nephropathies. Men get sick much more often (the form associated with the X chromosome) and more severely. Initially, it does not cause any symptoms. With the progression of the disease, symptoms from the urinary system are noticeable, and most often the first abnormality is noticed during the examination of general urine. A characteristic result is hematuria (occurring periodically and stopping automatically) and proteinuria. Over time, kidney failure occurs and other complications of chronic kidney disease appear – usually hypertension, anemia, edema.

In the course of Alport syndrome, progressive hearing loss also occurs, and hearing problems often begin in adolescent boys. Severe hearing loss generally occurs even before the onset of renal failure requiring renal replacement therapy. A common symptom of the disease is a gradually increasing deterioration of vision, which requires wearing corrective lenses and changing them more than once, because the progressive distortion of the lens causes refractive disorders. When the changes affect the retina, there may be problems with central vision [2]. The most common ophthalmic disorders occurring in the course of this syndrome are: anterior lenticonus (pathognomonic lesion), posterior polymorphic Duchenne dystrophy, recurrent corneal erosions, central or perimacular spotted retinopathy, peripheral *dot-and-fleck* retinopathy, temporal thinning of the retina and cataract [3]. There is no possibility of causal treatment of Alport syndrome, and patient care is based on the treatment of local and systemic complications. The paper will present the clinical case of the patient along with his qualification for ophthalmic surgery.

CASE STUDY

A 38-year-old man with a deterioration of visual acuity and initial cataract was admitted to the ophthalmology clinic of the Provincial Ophthalmology Hospital in Krakow.

In the anamnesis, amblyopia of the right eye and hyperopia of both eyes. A patient examined for more than a year by ophthalmologists and optometrists with frequent changes of spectacle lenses without a beneficial effect. In addition, in the interview twice transplanted the right kidney. In addition, without significant systemic or ophthalmic diseases in the family.

The patient was referred to the ophthalmology department for a comprehensive physical examination. In the opto-

metric examination, best-corrected distance visual acuity (BCVA) on the Snellen table of the right eye was 0.2 (in correction: sph +5.75/cyl -2.00 axis 15) and the left eye: -0.5 (with correction: sph +5.00/cyl -1.25 axis 173) which indicates hyperopia, while the autorefractometer examination indicated for right eye: sph -7.00/cyl -3.75 axis 14, and left eye: sph -5.25/cyl -6.50 axis 78, that is myopia. The patient did not take myopic correction and visual acuity was improved only by hyperopia correction. In the physical examination of the anterior segment of the eye, no abnormalities were found except for the visible initial posterior polar eclipses (fig. 1, 2) and the anterior lenticonus.

FIGURE 1

Biomicroscope photograph of the anterior segment of the right eye.

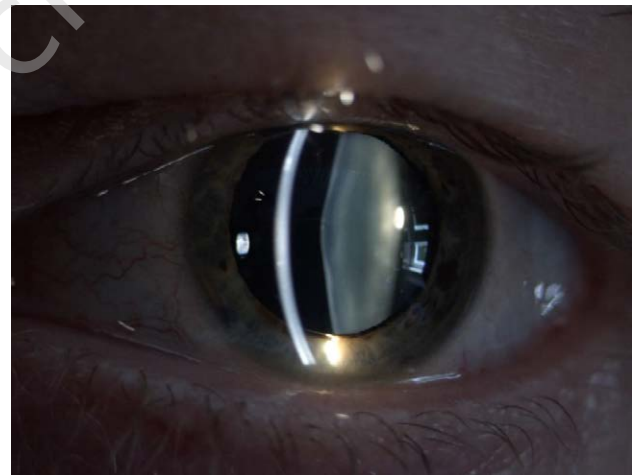
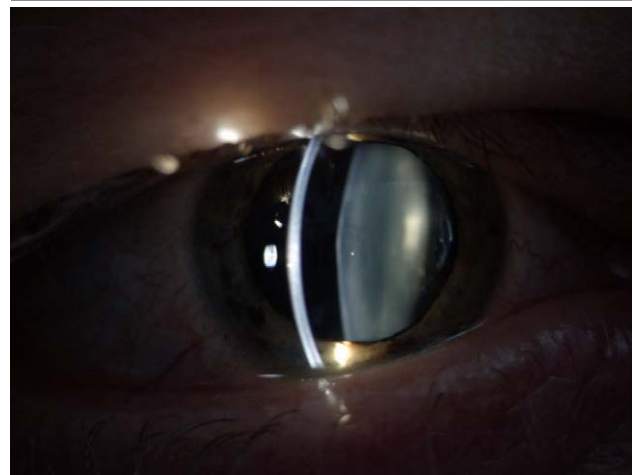

FIGURE 2

Biomicroscope photograph of the anterior segment of the left eye.



It has been confirmed by biometric examination – the characteristic bulging of the lens (fig. 3, 4), optical coherent tomography (OCT) – visible thinner temporal retina (fig. 5, 6) and the aberrometric test showing the high toxicity of spherical aberrations (fig. 7, 8). The cornea was excluded as a source of aberration by topographic examination of both eyes (fig. 9, 10).

Initially cataracted lenses were removed in a classic way – phacoemulsification. The procedure removed the anterior lenticonus located in the anterior capsulorection zone.

The operations were carried out with a monthly interval, and during the control the results of the autorefractometer examination were as follows: for the right eye – sph +0.75/cyl -0.75 axis 170, and for the left eye: sph +0.50/cyl -0.75

FIGURE 3

Biometric analysis of the right eye.

OD: Axial length of right eye: 21.61 mm. - Note: short eye.

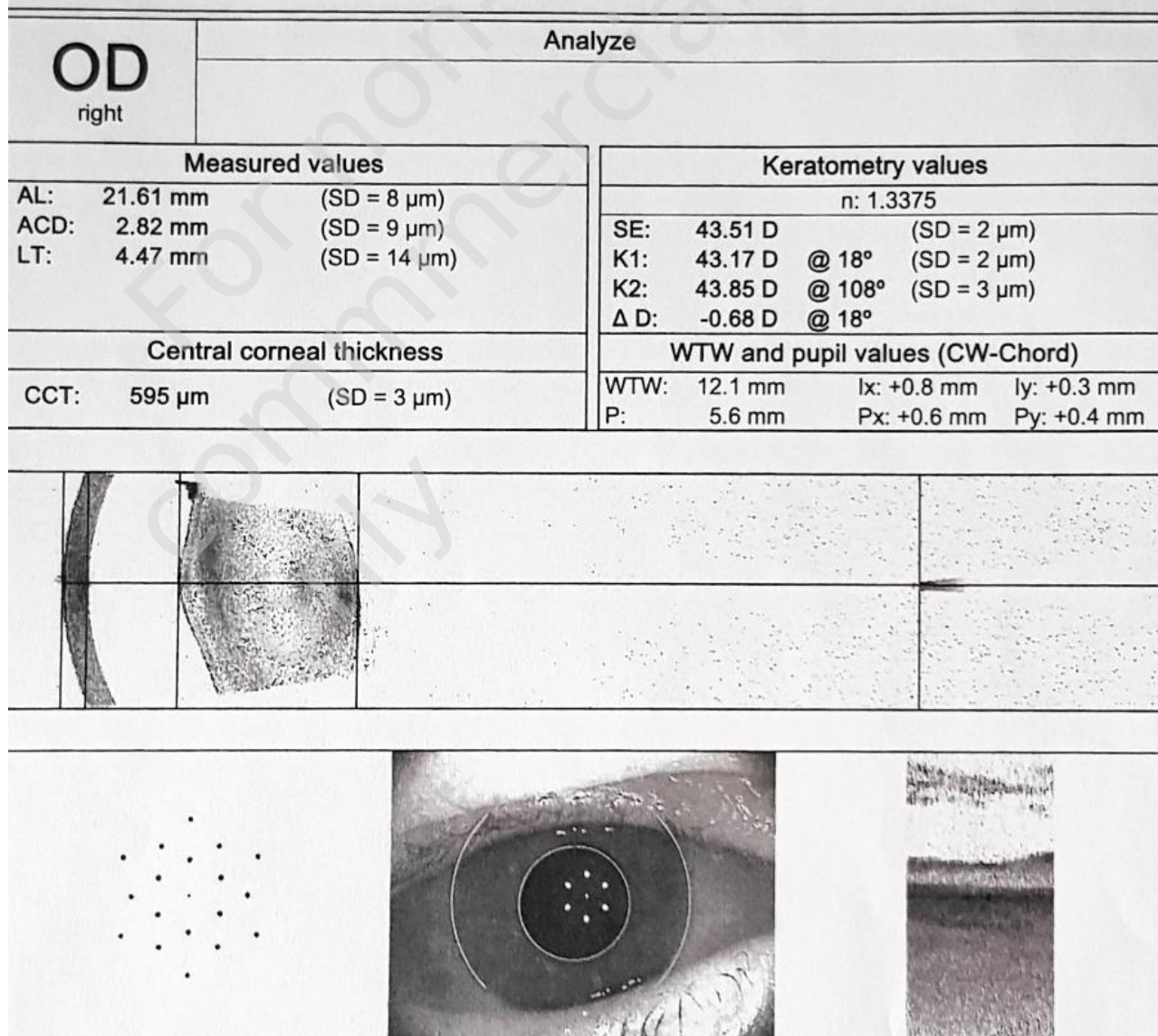


FIGURE 4

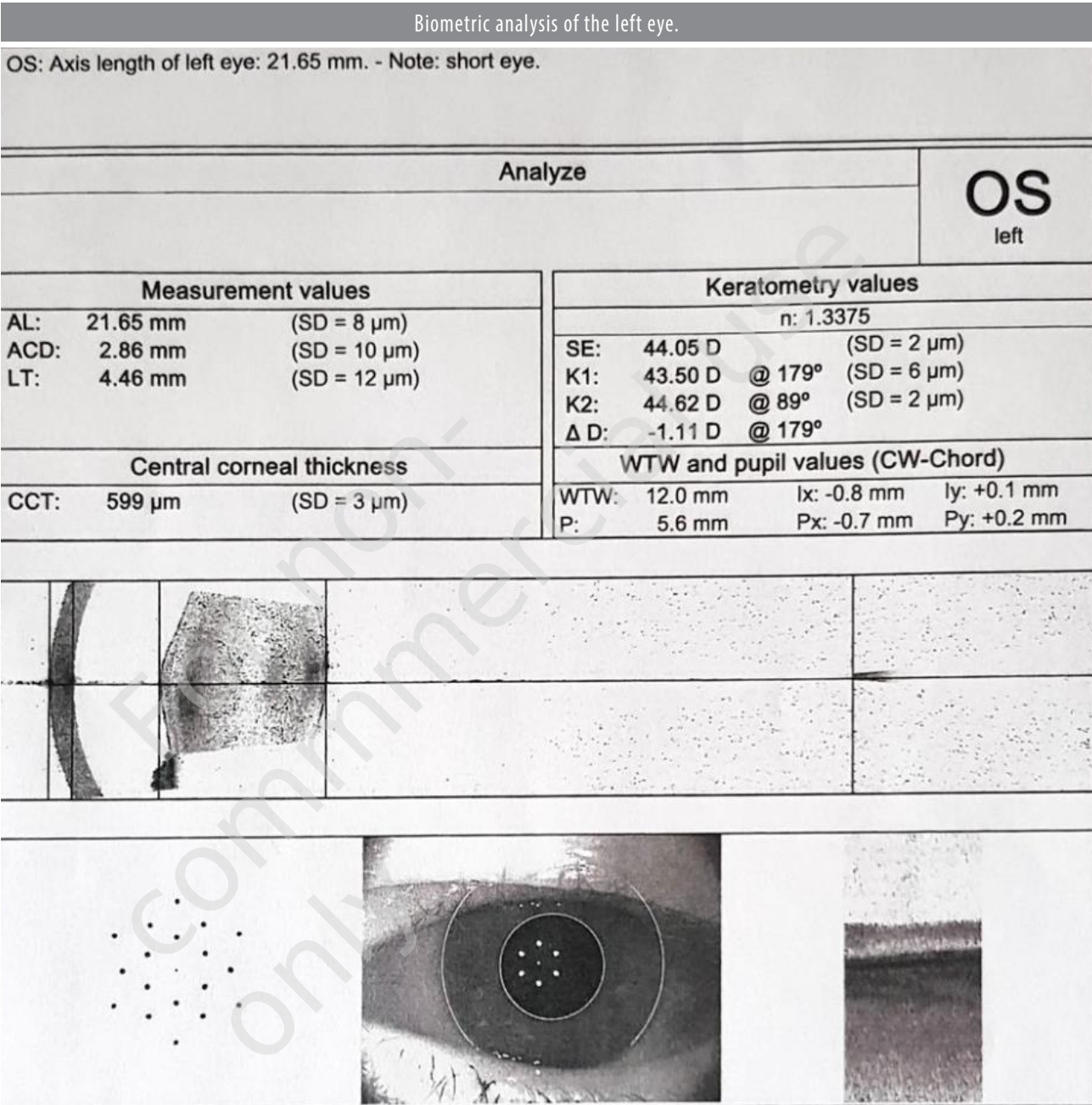


FIGURE 5

OCT of the right eye macula.

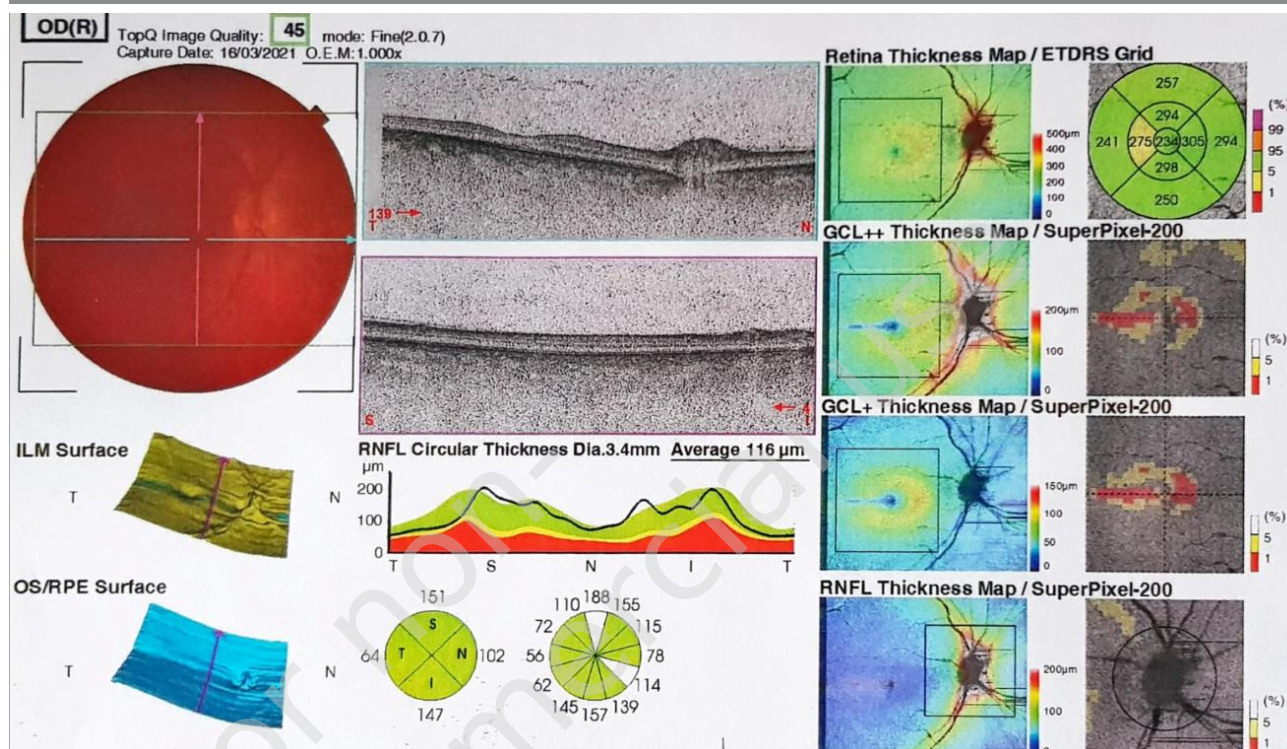


FIGURE 6

OCT of the left eye macula.

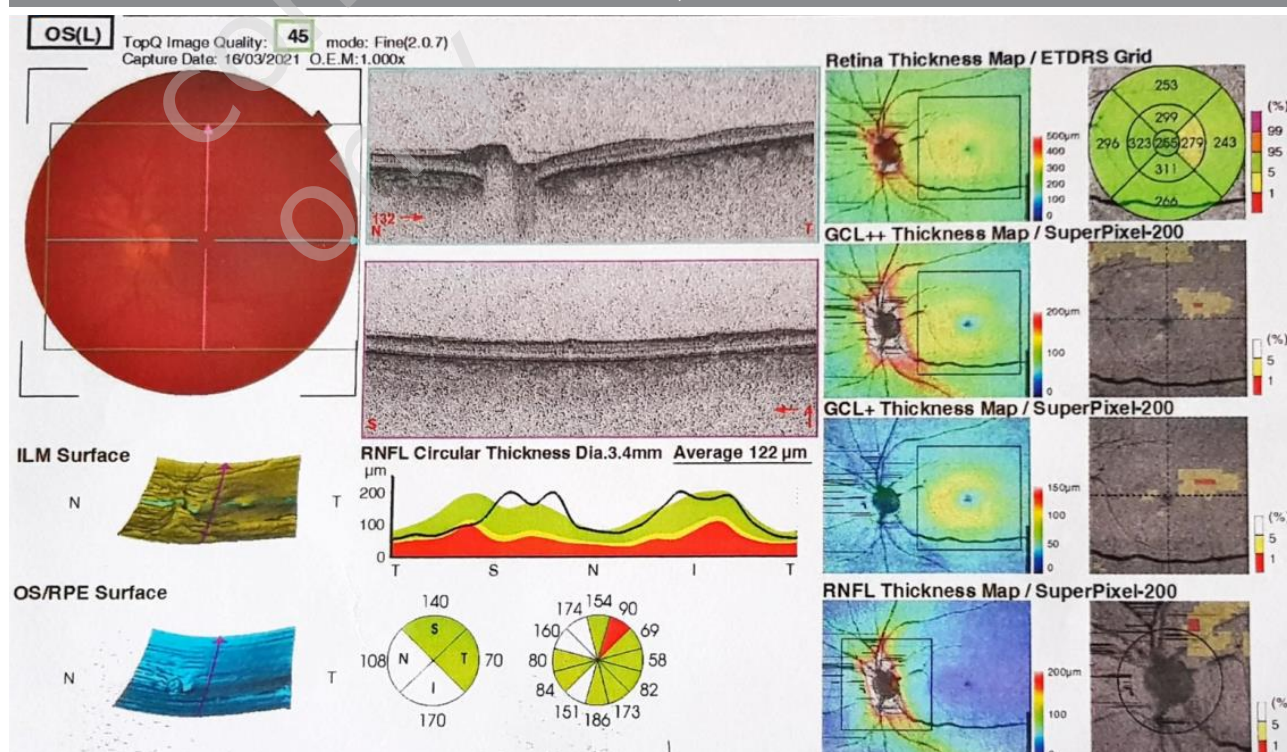


FIGURE 7

Right eye aberrometry.

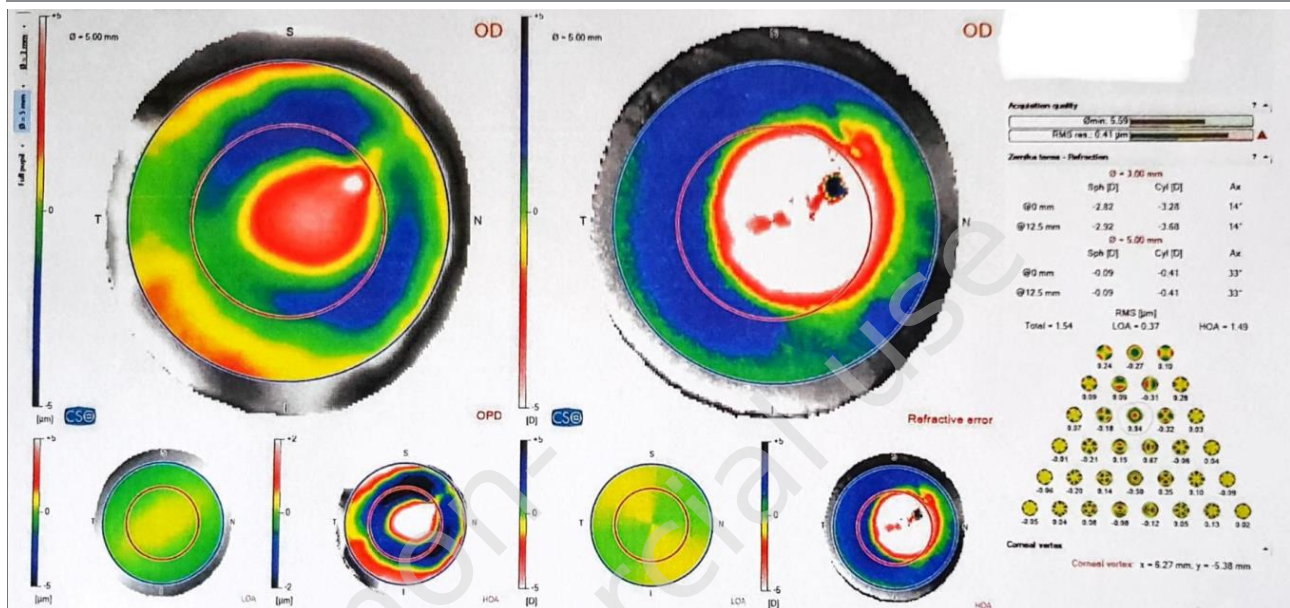


FIGURE 8

Left eye aberrometry.

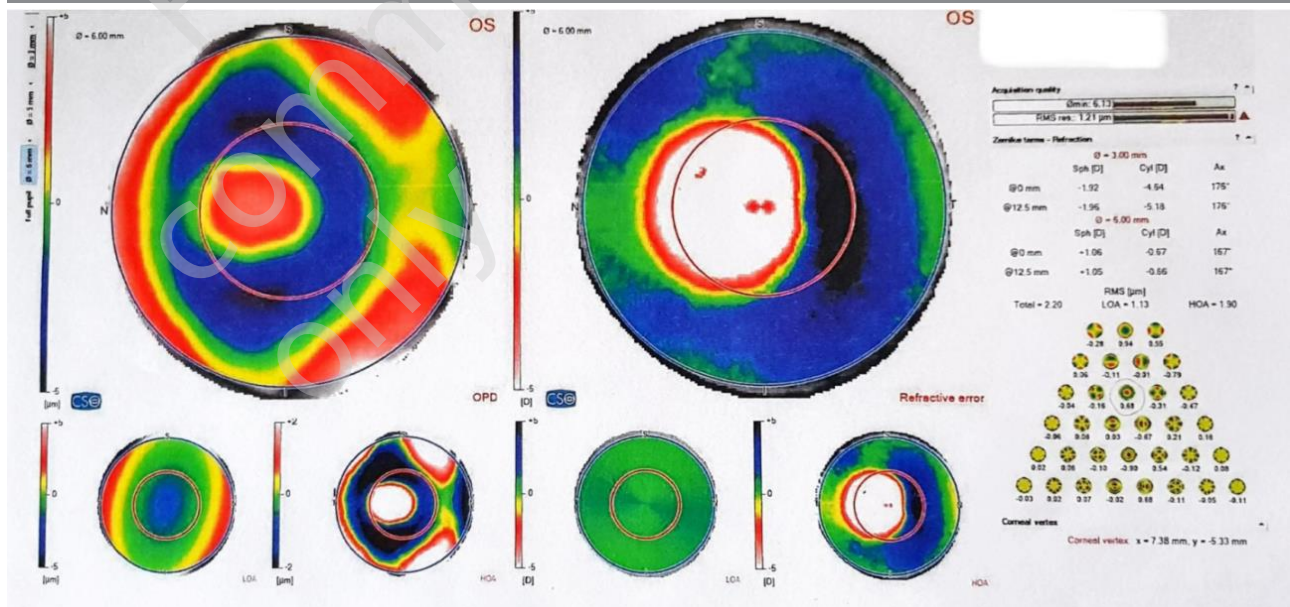


FIGURE 9

Right eye topography.

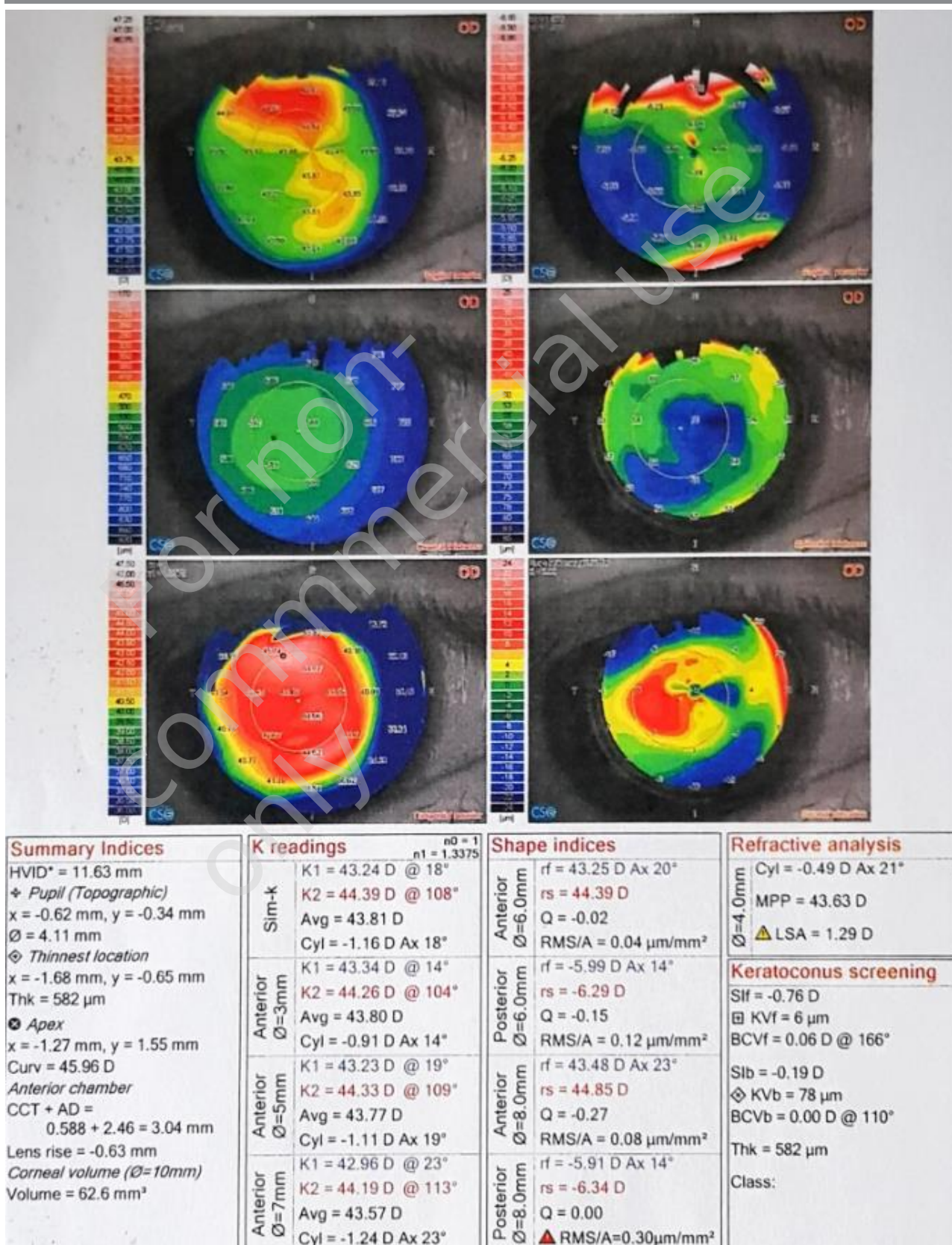
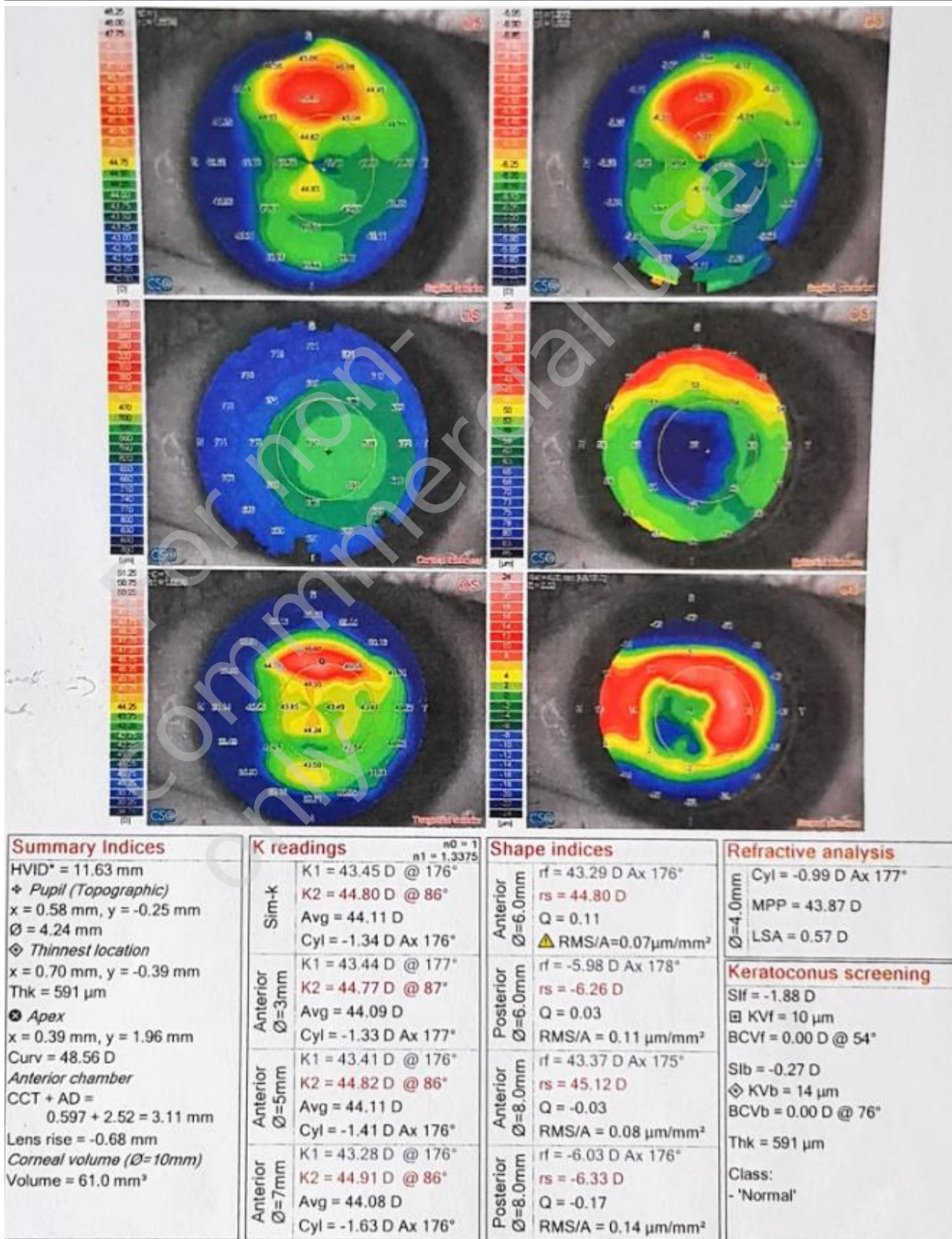


FIGURE 10

Left eye topography.



axis 175. Visual acuity test on Snellen's table (V right eye): 0.5 without correction (visually impaired eye) and (V left eye) 1.0 without correction. Examination of near visual acuity for the right eye was (Snellen table): 0.75 (with correction of sph +3.00 D) and for the left eye: 0.5 (with correction of +3.0 D). Right eye intraocular pressure: 13 mmHg and left eye: 15 mmHg. Postoperative physical examination of both eyes showed no abnormalities and healing was carried out properly.

DISCUSSION

The pathognomonic ophthalmic change for Alport syndrome is anterior lenticonus. Collagen disorders occurring in this syndrome cause the formation of gaps in the lens capsule, which then spontaneously or under the influence of injury break. This results in the lens being emphasized forward [4]. The anterior lenticonus is recognized by the presence of the symptom of an "oil drop" in the examination of the anterior segment of the eye in the slit lamp. In patients with anterior lenticonus and refractive defects, corrective lens therapy may initially be used, however, the basis for the treatment of the anterior lenticonus is the removal of the affected lens. Such a procedure was carried out in the described patient. Due to the properties of the lens capsule present in this syndrome, the most difficult stage of this procedure is anterior capsulorhexis [5]. In order to avoid peripheral captions during the procedure, it is recommended to use a viscoelastic agent with a high mo-

lecular weight, while to reduce the incidence of secondary turbidity of the posterior capsule, it is recommended to implant a retractable hydrophobic acrylic lens. Recommendations and postoperative rehabilitation is the same as after phacoemulsification carried out for senile cataracts [6].

The phacoemulsification procedure carried out in the described patient went without complications. The only difficulty was an unusual, more delicate pouch, which was characterized by less stability during capsulorhexis. However, it was possible to obtain a continuous, round and correct shape capsulorhexia using 2% cohesive viscoelastic. Subsequently, aspherical lenses with a UV filter and blue light were implanted. Subsequent postoperative examinations indicate a significant improvement in the quality of vision.

CONCLUSION

A patient diagnosed with anterior lenticonus and progressive, high myopia that cannot be corrected is potentially a person with Alport syndrome. Early diagnosis allows for satisfactory supply of the patient both nephrologically, otolaryngologically and ophthalmologically, improving his quality of life. The described clinical case proves that phacoemulsification with implantation of an artificial lens is both a safe and effective method in patients suffering from anterior lenticonus in the course of Alport syndrome.

Figures: from the authors' own materials.

CORRESPONDENCE

stud. Ada Pandey

31-510 Kraków, ul. Rakowicka 20B/36

tel.: 531 53 15 68

e-mail: adapandey.ap@gmail.com

ORCID

Ada Pandey – ID – <http://orcid.org/0000-0001-9467-1005>

Justyna Gugnowska – ID – <http://orcid.org/0000-0002-2649-3531>

Angelika Kruszyńska – ID – <http://orcid.org/0000-0003-3567-9079>

Kinga Czarnacka – ID – <http://orcid.org/0000-0002-6889-6507>

Małgorzata Gawlak – ID – <http://orcid.org/0000-0003-4573-1379>

Oliwia Cwalina – ID – <http://orcid.org/0000-0002-7071-0273>

Alicja Chmura – ID – <http://orcid.org/0000-0003-0733-1542>

Maciej Kozak – ID – <http://orcid.org/0000-0001-7993-2588>

Katarzyna Sajak-Hydzyk – ID – <http://orcid.org/0000-0002-1973-2717>

Ilona Pawlicka – ID – <http://orcid.org/0000-0003-1556-7678>

References

1. Grzybowski A. Okulistyka. Edra Urban & Partner, Poznań 2018: 309.
2. Drabczyk R. Zespół Alporta. <https://www.mp.pl/pacjent/nefrologia/choroby/chorobyudoroslych/166697,zespol-alporta> (access: 18.04.2022).
3. Ostrowska-Spaleniak A, Krix-Jachym K, Rękas M. Ocular manifestation and surgical treatment outcomes in Alport syndrome – case series. *Klinika Oczna/Acta Ophthalmologica Polonica*. 2017; 119(2): 116-9. <http://doi.org/10.5114/ko.2017.71782>.
4. Sonarkhan S, Ramappa M, Chaurasia S et al. Bilateral anterior lenticonus in a case of Alport syndrome: A clinical and histopathological correlation after successful clear lens extraction. *BMJ Case Rep*. 2014; 2014: bcr2013202036. <http://doi.org/10.1136/bcr-2013-202036>.
5. Kashtan C. Multidisciplinary Management of Alport Syndrome: Current Perspectives. *J Multidiscip Healthc*. 2021; 14: 1169-80.
6. Brymerski J, Wietrzykowska K, Olszewski M. Obustronny stożek przedni soczewki u pacjenta chorującego na zespół Alporta – opis przypadku. *Klin Oczna*. 2018; 120(1): 42-5.

Authors' contributions:

All authors have equal contribution to the paper.

Conflict of interest:

None.

Financial support:

None.

Ethics:

The content presented in the article complies with the principles of the Helsinki Declaration, EU directives and harmonized requirements for biomedical journals.