

# Contact lens-related combined *Pseudomonas aeruginosa*, *Acanthamoeba* and *Candida* keratitis among adolescents girls

Marta Świerczyńska<sup>1,2</sup>, Agnieszka Tronina<sup>3,4</sup>, Michał Bogocz<sup>2</sup>,  
Ewa Mrukwa-Kominek<sup>1,2</sup>, Erita Filipek<sup>3,4</sup>

<sup>1</sup> Department of Ophthalmology, Faculty of Medical Sciences in Katowice, Medical University of Silesia, Katowice, Poland

<sup>2</sup> Department of Ophthalmology, Kornel Gibiński University Clinical Center, Medical University of Silesia, Katowice, Poland  
Head of Department: prof. Ewa Mrukwa-Kominek, MD, PhD

<sup>3</sup> Department of Pediatric Ophthalmology, Faculty of Medical Sciences in Katowice, Medical University of Silesia, Katowice, Poland

<sup>4</sup> Department of Pediatric Ophthalmology, Kornel Gibiński University Clinical Center, Medical University of Silesia, Katowice, Poland  
Head of Department: Erita Filipek, MD, PhD



## HIGHLIGHTS

With the increasing popularity of contact lens wear, contact lens-related keratitis is becoming more prevalent. It is essential to inform patients and their parents/guardians about possible complications. This case report highlights the importance of considering the possibility of coinfection.

## ABSTRACT

**Background:** We present a case of combined *Pseudomonas aeruginosa*, *Acanthamoeba* and *Candida* keratitis and clinical course of treatment in two adolescents girls who did not follow the rules of proper use of soft contact lenses.

**Case reports:** Two teenage contact lens users sought medical attention, reporting visual impairment, redness and pain of the eye. Slit lamp examination showed unilateral corneal ulcer. Confocal microscopy revealed images compatible with amoebic cysts and yeasts cells, whereas the results of conjunctival swabs confirmed the presence of *Pseudomonas aeruginosa*. After topical and general treatment in the first patient, the corneal defect was healed, and visual acuity improved. The girl remains under the constant supervision of an ophthalmological clinic. The medications were gradually reduced, but with time she developed crystalline keratopathy. Regrettably, the second patient, despite the applied treatment had recurrent inflammation and progressive corneal thinning, which required amniotic membrane transplantation to prevent perforation.

**Conclusion:** The early identification of the pathogen as well as adequate treatment is crucial, as contact lens-associated keratitis are potentially sight threatening. Patient and caregiver education, adequate contact lens hygiene and consistent follow-up are important to prevent serious complications.

**Key words:** infectious keratitis, contact lenses, *Candida*, *Acanthamoeba*, *Pseudomonas aeruginosa*

## INTRODUCTION

In the past decade, there has been a growing interest in the use of contact lenses among children and adolescents. They found application in management of refractive errors that cannot be addressed by spectacles, such as aphakia, keratoconus, irregular cornea or high anisometropia. In addition, they can be used to correct simple refractive errors as alternatives to spectacles. Contact lenses have improved the quality of life not only by correcting refractive errors but also by improving self-esteem regarding appearance and reducing restriction in activities [1].

Unfortunately, contact lenses can cause complications, such as: discomfort, dry eye, pinguecula, mucin ball, giant papillary conjunctivitis, allergy aggravation, corneal edema, staining or neovascularization, superior epithelial arcuate lesions, deep stromal opacity, contact lens-related peripheral ulcer, microbial keratitis, herpes reactivation or ptosis. Contact lens-related keratitis requires prompt diagnosis and appropriate treatment. Otherwise, this condition may cause serious corneal damage, including descemetocele formation, corneal perforation, glaucoma, cataract, endophthalmitis which can ultimately lead to loss of vision [1, 2].

## CASE REPORTS

### Case 1.

A 16-year-old girl presented to the emergency department with complaints of visual impairment, watering and progressive pain in the right eye (RE) for the past 2 days. She had been wearing soft contact lens to correct myopia and sometimes slept with her lenses on. There was no history of ocular trauma. At presentation, the best corrected visual acuity (BCVA) was hand motions in the RE and 5/5 with a correction of -2,25 diopters (D) sph in the left eye (LE). Slit-lamp examination of the RE revealed conjunctival hyperemia with excessive purulent secretion, dense anterior stromal grey-white infiltrate with fluffy edges and an overlying epithelial defect accompanied by stromal edema, hypopyon, anterior chamber demonstrated inflammation (fig. 1A, 2A). In the LE, corneal subepithelial haze was visible, suggesting a history of viral keratitis. Intraocular pressure (IOP) was 12 mmHg in both eyes (OU). B-scan ultrasonography was normal OU. The patient was admitted to hospital for intensive treatment. Standard swabs were taken from the OU conjunctival sac. The patient wore artificial nails which were about 5 cm long and showed signs of neglect of hygiene (fig. 3A, B). Also, the contact lens storage container was filthy (fig. 3 C). Therefore, swabs were collected from the underside of the artificial nails, contact lenses and contact lens storage for culture testing. Confocal microscopy revealed images compatible with amoebic cysts and yeast cells (fig. 4A, B). Aerobic culture

of the conjunctival sac showed the growth of *Pseudomonas aeruginosa* and *Staphylococcus epidermidis*, whereas culture of the swab taken from under the nails showed the presence of *Enterobacter cloacae*. A mixed infection consisting

FIGURE 1

(A) Slit-lamp examination of the RE on presentation. Conjunctival hyperemia with purulent secretion, dense anterior stromal grey-white infiltrate with fluffy edges and an overlying epithelial defect accompanied by stromal edema, hypopyon are visible.  
(B) The appearance of the RE cornea on the day of discharge from the hospital, (C) crystalline keratopathy 3 months after the start of treatment.

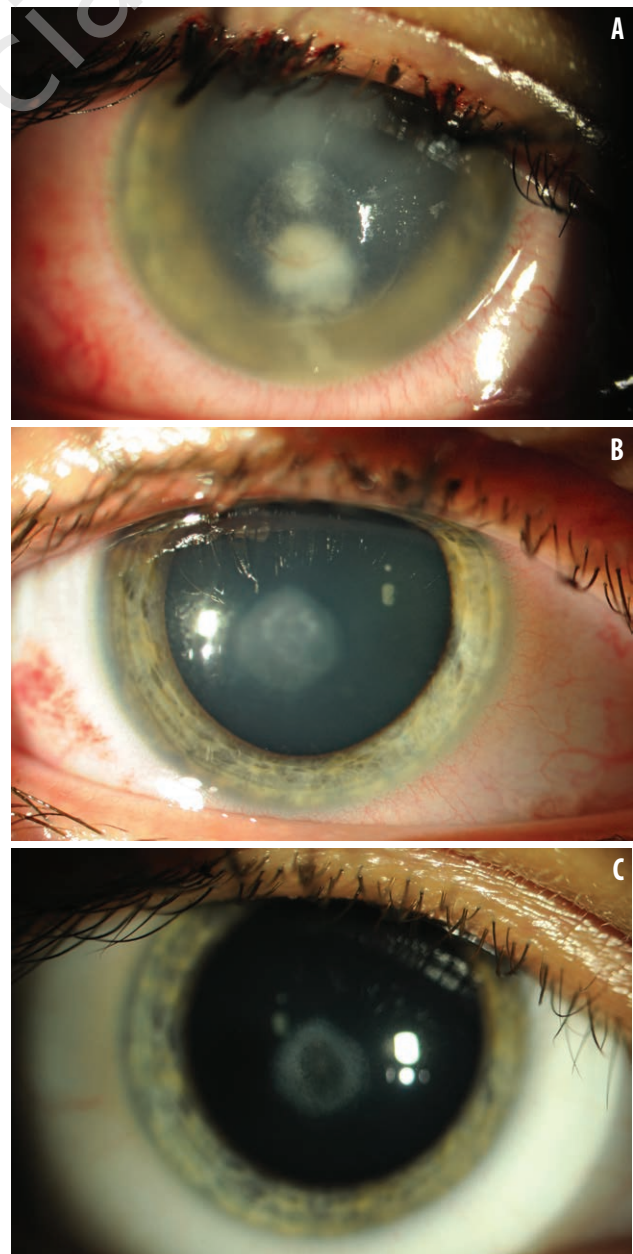
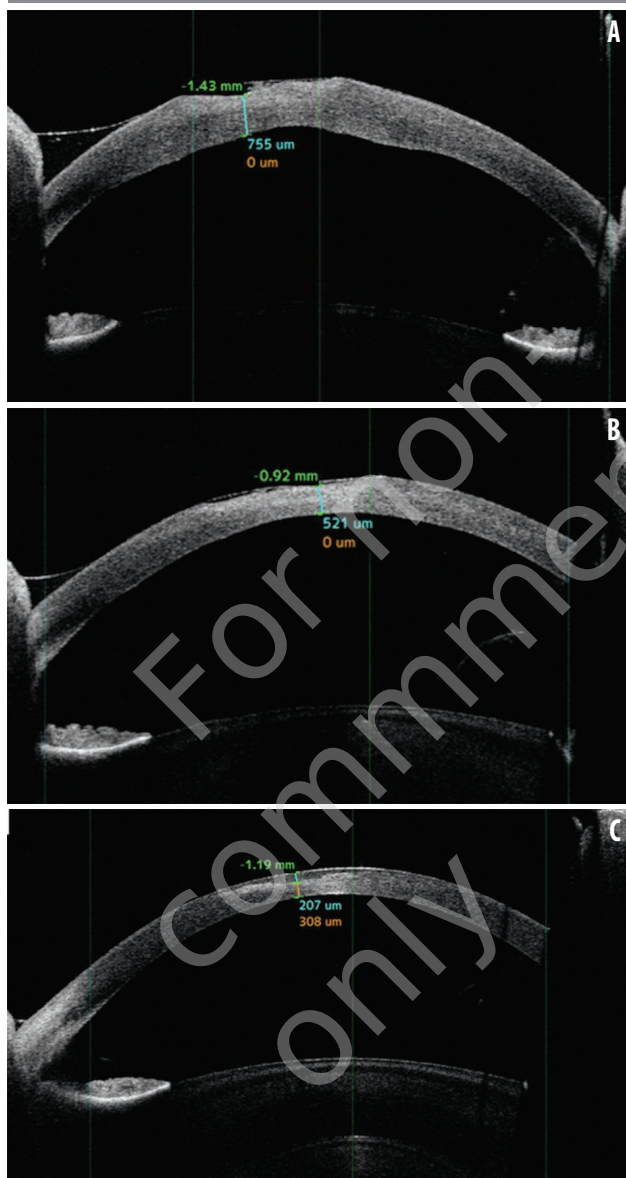


FIGURE 2

Anterior segment-optical coherence tomography (AS-OCT) of the RE cornea (A) on the day of admission, (B) on the day of discharge and (C) 10 months after discharge from the hospital.



of *Acanthamoeba*, *Candida* and Gram-negative bacteria was assumed to be present. Injection of lincomycin, dexamethasone, atropine (LDA) was applied subconjunctivally once a day for the first 3 days of treatment. Moreover, the treatment consisted of topical 0.1% propamidine isethionate (a drop/h), levofloxacin (a drop/h), neomycin sulfate (ointment, 3 × 1), fluconazole (5 × 1), 1% atropine (2 × 1) as well as fluconazole (1 × 200 mg), sulfamethoxazole with trimethoprim (2 × 960 mg), cefuroxime (3 × 750 mg) taken orally; dexamethasone (1 × 6 mg for 3 days, and then 1 × 4 mg) intravenously. The hypopyon disappeared within

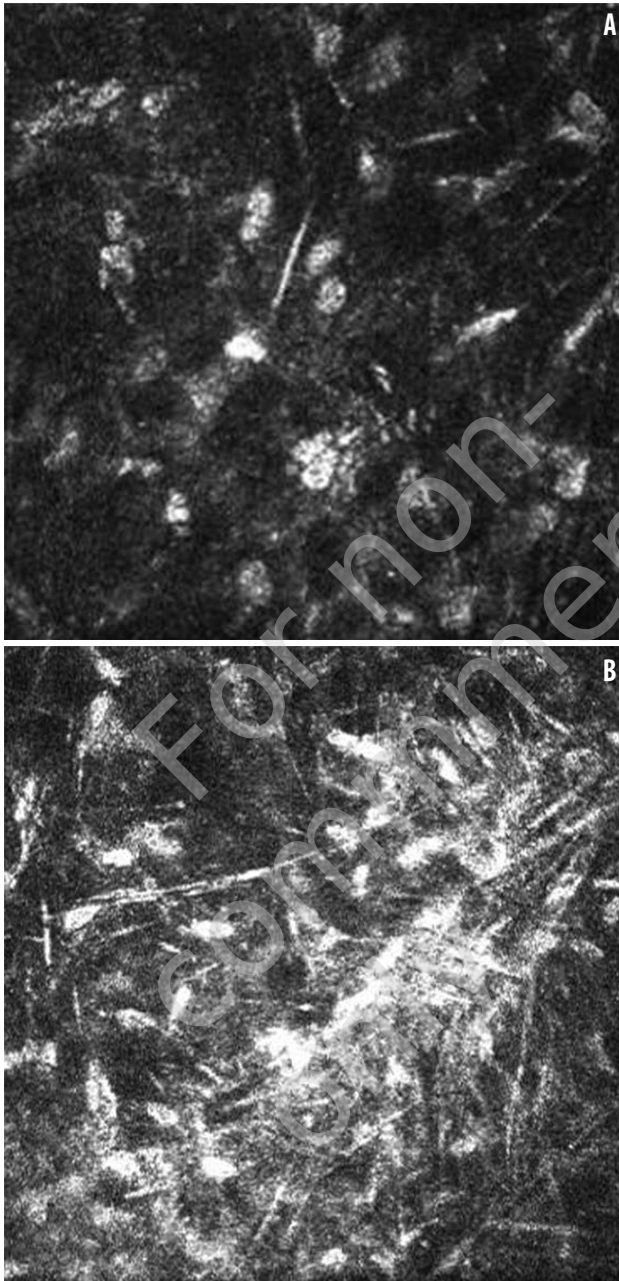
FIGURE 3

(A, B) The patient's artificial fingernails, showing features of negligent hygiene.  
(C) Contaminated containers for storing contact lenses.

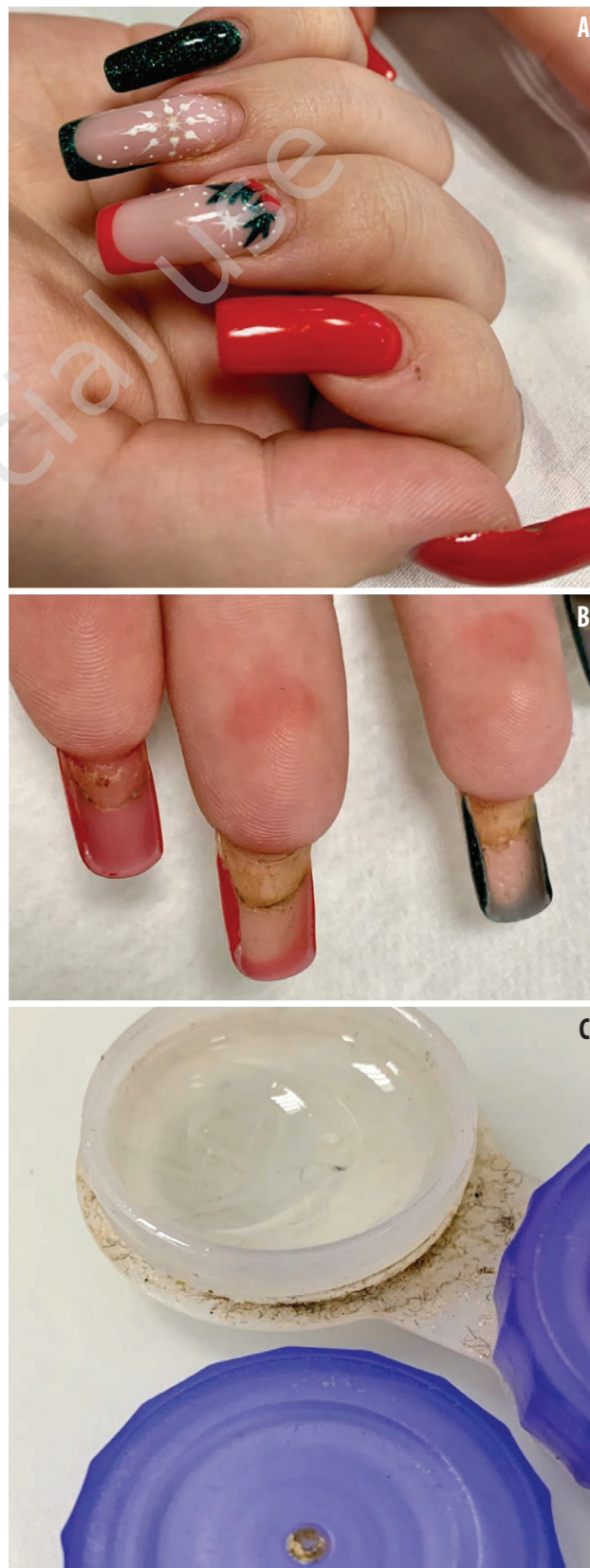

FIGURE 4

Confocal microscopy showed images compatible with (A) amoebic cysts and (B) yeasts cells.

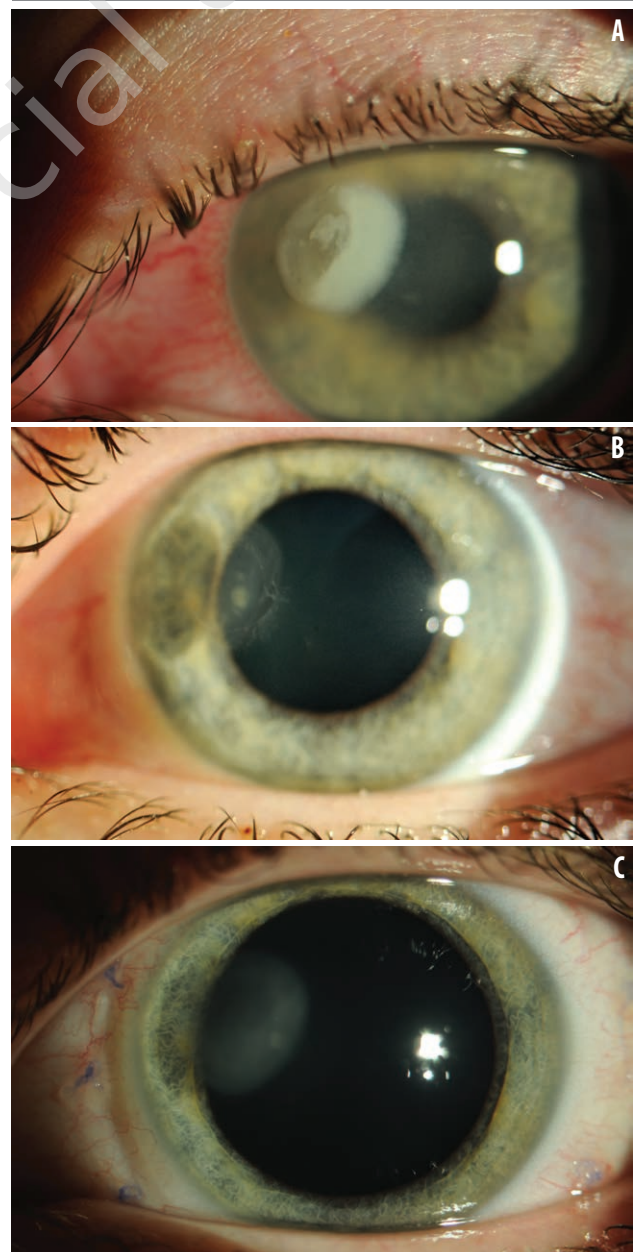


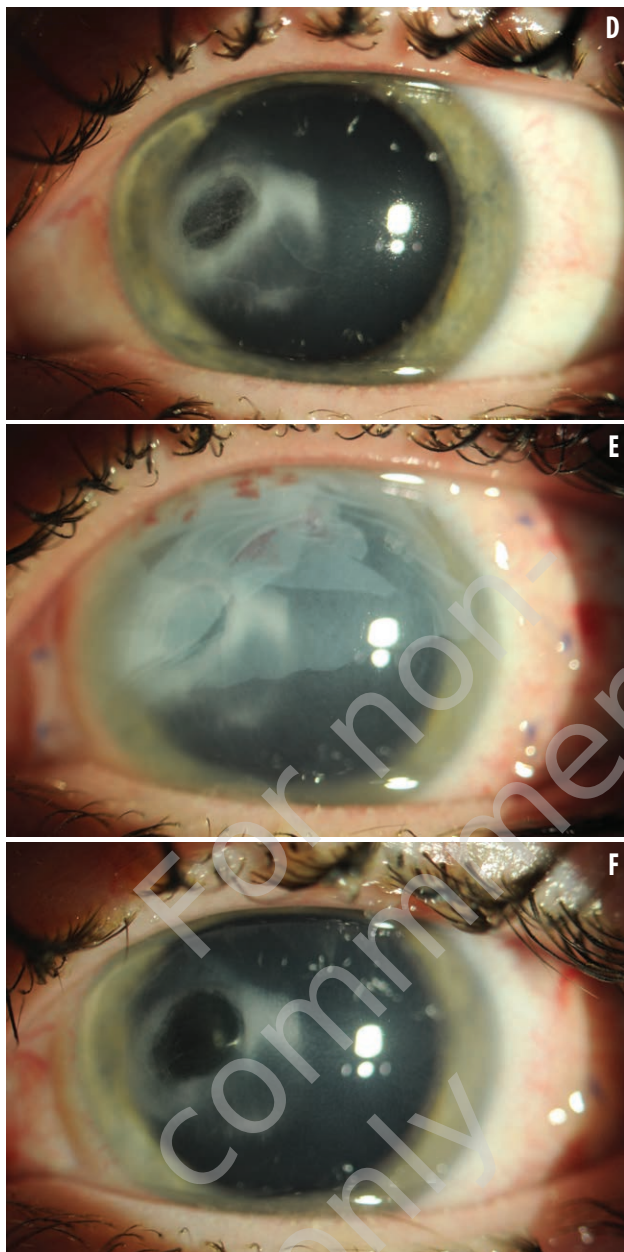
3 days. Once the defect had epithelialized topical dexamethasone ( $3 \times 1$ ) was added. By day 11, patient was discharged and BCVA was 5/10 with -2,25 Dsph in the RE (fig. 1B, 2B). The patient was forbidden to wear contact lenses until the end of treatment.

At a follow-up visit 3 months later, confocal microscopy showed a high degree of polymorphism and polymegathism of endothelial cells, numerous crystal structures indicative of the formation of crystalline keratopathy. During the eight months after discharge, there was gradual reduction

FIGURE 5

Slit-lamp examination of the LE (A) on presentation: upper eyelid edema, marked ciliary injection, corneal ulcer with surrounding corneal oedema can be noticed. (B) Thinning of the cornea at the ulceration site a month after discharge from the hospital. (C) Status post suturing the amniotic membrane (AM) over the LE cornea, AM absorbed, conjunctival sutures maintained. (D) Corneal thinning, active inflammatory process visible at the edges, (E) sutured two layers AM over the LE cornea. (F) The appearance of the LE cornea 10 months after start of treatment: AM absorbed, ulcer with less inflammatory infiltrate, more connective tissue at the bottom of the ulcer.





in the frequency of administration of the anti-amoebic and anti-fungal medications as well as steroid therapy under regular follow-ups. Final BCVA was 5/10 cc -2,25 Dsph in the RE, a diffuse subepithelial scar remained and there was no recurrence (fig. 1C, 2C).

## Case 2.

A 17-year-old girl had a 4-day history of diminution of vision, photophobia, severe pain, and redness in the LE. She was pre-diagnosed with conjunctivitis by a pediatrician and topical fludrocortisone and neomycin twice a day were prescribed. Her symptoms worsened and she was referred to our university hospital for further treatment. The patient had been wearing soft contact lenses to correct hyperopia OU sporadically (mostly spectacle correction). The patient admitted that she sometimes did not take off her

lenses during sleeping or showering. There was no history of preceding trauma. Her medical history was significant for seasonal allergy, whereas the ophthalmological history included RE amblyopia due to anisometropia. On examination, BCVA 5/10 with correction +2,0 Dsph +0,5 Dcyl ax 120° in the RE; 5/10 with a pinhole in the LE. IOP was 15 mmHg and 18 mmHg in the RE and LE, respectively. Slit-lamp examination revealed conjunctival injection and corneal scar in the RE. There was a left upper eyelid edema, marked ciliary injection, infectious corneal ulcer with surrounding corneal oedema in the LE (fig. 5A). Posterior segment examination was unremarkable OU.

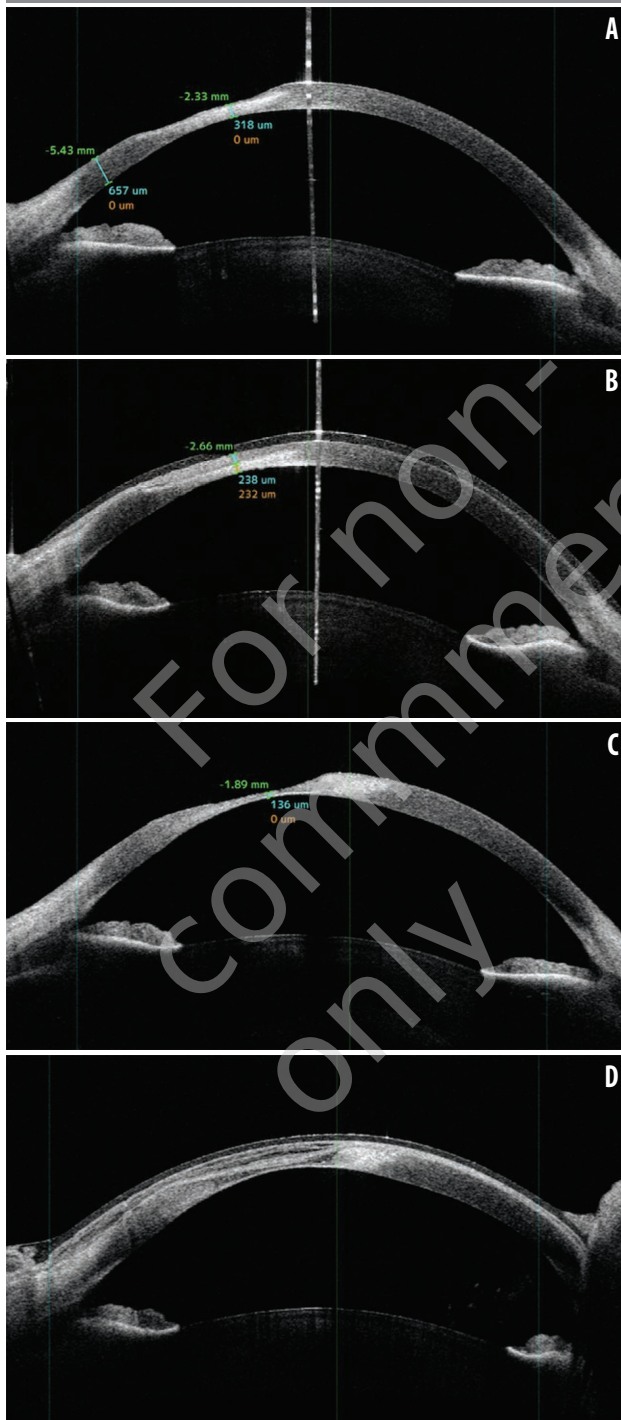
Corneal scraping was performed and sent for direct microscopy (Gram stain, potassium hydroxide [KOH] wet mount) and cultures (blood agar, chocolate agar, *Escherichia coli* plated non-nutrient agar and Sabouraud dextrose agar), with negative results. Microbiological cultures obtained from the conjunctival sac of the LE and contact lenses were positive for *Pseudomonas aeruginosa*. The objective signs of *Acanthamoeba* and *Candida* were seen at confocal microscopic examination, and the following treatment was started – RE: levofloxacin (5 × 1); LE: subconjunctival injection of LDA (once a day for the first three days of treatment), topical 0.1% propamidine isethionate (a drop/h), levofloxacin (a drop/h), neomycin sulfate (ointment, 3 × 1), fluconazole (5 × 1), 1% atropine (2 × 1) as well as fluconazole (1 × 200 mg), sulfamethoxazole with trimethoprim (2 × 960 mg) taken orally; dexamethasone (4 mg for 3 days, and then 3 mg) intravenously. The ulcer resolved gradually. On the 9<sup>th</sup> day on discharge BCVA was 5/8 with correction of +4.5 Dsph +0.75 Dcyl ax 20° in the LE (fig. 6A).

One month later BCVA was 5/8, but due to corneal thinning and the risk of corneal perforation, amniotic membrane transplantation (AMT) was performed on the LE cornea (fig. 5B, C, 6B). In the following month, BCVA was 5/6 with correction, but the teenager was re-admitted to the ophthalmology department due to corneal thinning at the site of ulceration. Moreover, an active inflammatory process was visible at the edges of the ulceration (fig. 5D). The confocal microscopy examination confirmed the persistent presence of protozoan cysts and yeast cells. The AM was re-sutured on the LE cornea and the anti-amoebic and anti-fungal treatment was intensified by adding topical 1% voriconazole (every 2 h, and then 8 × 1) and 0.02% chlorhexidine (3 × 1); doxycycline (2 × 100 mg), voriconazole (2 × 200 mg) taken orally obtaining a partial improvement of the local condition.

Within 10 months, due to the descemetocoele, AM was sutured 10 times on the LE cornea, including 3 times in two layers (fig. 5E; 6C, D). However, in the patient's case, the AM disintegrated several times a few days after suturing and had no chance to have a therapeutic effect and be absorbed spontaneously. At a later stage, ozone-based eye drops

FIGURE 6

AC-OCT of the LE (A) on the day of discharge from the hospital, (B) corneal thinning up to 232  $\mu\text{m}$  and sutured AM, (C) corneal thinning up to 136  $\mu\text{m}$ , (D) sutured double A.



(3  $\times$  1) were added to the treatment. During the course of therapy, the patient developed elevated IOP in the LE; for this reason, dorzolamide treatment was started 3 times a day. Due to recurrent fungal infection, the patient was diagnosed for infectious diseases and immune disorders, but

no abnormalities were found. Currently, the patient remains under the constant supervision of an ophthalmic clinic, the recently sutured amniotic membrane covers the thinning site and treatment is gradually tapered (fig. 5F).

## DISCUSSION

Predisposing factors for contact lens related-keratitis can be divided into contact lens dependent (overnight use, improper handling, lens material and design, contaminated lens cleanser) and personal (hygiene problem, immunosuppressive state, allergy, chronic dry eye) [3, 4]. The above-described patients reported occasional lens wear while sleeping. Studies have shown that overnight use of contact lens increases the risk for microbial keratitis even eight-fold. During sleep with contact lens the oxygen delivery to the cornea as well as the flow of tears are impaired causing hypoxia and hypercapnia of the corneal epithelium. Moreover, prolonged time of pathogens remaining on the ocular surface facilitates adherence and penetration through the impaired epithelial barrier [4]. Furthermore, contact lenses users often fail to follow proper hygiene measures, improperly store their lenses, rinse them with tap water, bathe or shower while wearing contact lenses, as demonstrated by the patients described above. In patient number 1, the results of swabs from beneath the nail showed the presence of *Enterobacter cloacae* that is commensal organism of the gastrointestinal tract, which indicates poor toilet hygiene and inadequate hand washing.

Early diagnosis and targeted therapy prevent rapid destruction of eye. Corneal scrapping to obtain epithelial samples or confocal microscopy is mandatory in all suspected corneal infection. *Pseudomonas aeruginosa* is the most common causative agent of contact lens-related keratitis and is associated with significantly worse VA outcome than in other bacterial infections [5]. *P. aeruginosa* can damage the cornea due to excessive proteolytic activity mediated by its toxins and enzymes. The course of inflammation in this case may be fulminant, and perforation of the cornea may occur within the first 72 h of infection [6]. Moreover, this Gram-negative pathogen regularly forms biofilms during infections, which contributes to increasing resistance to antibiotics [7]. Isolation of the bacteria allows an antibiogram to be established, but topical fluoroquinolone remains first-line treatment [8].

Amoebic keratitis (AK) is rare entity and approximately 90% of cases are associated with contact lenses [9]. Their use can cause microtrauma in the corneal epithelium, and when combined with contaminated surface of contact lenses it becomes a major risk factor. Tu et al. [10] described 5 levels of AK severity: epitheliitis, epitheliitis with radial neuritis, anterior stromal disease, deep stromal keratitis, or ring infiltrate (which occurs in approximately 50% of

patients). In the early stage, AK may lead to a dendriform ulceration, that can be misdiagnosed with *Herpes simplex* keratitis. Pain is often inappropriate to state of corneal damage, usually due to cluster of trophozoites around the corneal nerves [11]. *Acanthamoeba* release multiple proteases and toxins allowing the organism to penetrate deep into the stroma, resulting in ulceration, descemetocoele formation and possible perforation as the disease progresses. Trophozoites are sensitive to a number of available medications, but cysts may lead to prolonged or treatment resistant infection. The diamidines (propamidines isethionate and hexamidine) and biguanides (polyhexamethylene biguanide – PHMB and chlorhexidine) are the most effective agents and show synergistic effect. Unfortunately, propamide and hexamidine are not available in all countries. Moreover, aminoglycosides (i.e. neomycin) have also been used with a great success as an adjuvant treatment [12]. The prevalence of fungal keratitis is low compared to bacterial keratitis. One of the most common mechanisms for *Candida albicans* keratitis to develop is traumatic introduction of the fungus, particularly those related to contact lens wear. Clinical features that are specific for fungal infections concern infiltrates with feathery margins, satellite lesions, whereas patients usually report less pain than observed in infections of bacterial etiology. If this type of pathogen is unequivocally diagnosed it is essential to discontinue previously introduced, topical steroids as their immunosuppressive effect might accelerate the infection [13]. Qiao et al. [14] support the use of fluconazole as a first-line treatment in *Candida* keratitis. Moreover, topical voriconazole therapy has good safety profile and broad spectrum of antifungal activity. Additionally, it is less toxic than topical amphotericin B, with better corneal penetration. Oral voriconazole is relatively safe and has demonstrated excellent intraocular penetration over other systemic antifungal agents; however, its use may carry possible adverse effects (i.e. increased levels of liver enzymes) [13, 15]. The difficulties in the management of combined fungal and *Acanthamoeba* infections are due to resistance to initial empirical antimicrobial agents. Moreover, AK is known to progress more rapidly because the fungi serve *Acanthamoeba* as nutrients. It had been demonstrated that when cells of *Acanthamoeba* spp. were incubated together with *P. aeruginosa*, increased pathogens binding to corneal surface was present [16]. What is more, *Acanthamoeba* cysts are resistant to extreme conditions and an activation of dormant cysts can lead to relapse of keratitis. Also, prema-

ture cessation of antifungal treatment usually leads to frequently observed recrudescence. For this reasons therapy should be continued for at least 3–4 months to eradicate viable cysts or fungi in the deep corneal stroma [17].

AMT is an effective method which can be used to treat inflammatory descemetocoele. AM is rich in biologically active factors, exhibits anti-inflammatory, anti-fibrotic, anti-angiogenic, anti-microbial features and supports cornea epithelialization. Mohammadpour et al. [18] concluded that double layered AMT results in acceptable anatomical outcomes in patients with advanced *Pseudomonas* keratitis with descemetocoele and can eliminate the necessity for urgent corneal transplantation. Although some studies have proposed that multilayered AM may act as a barrier and decrease antibiotic penetration, other authors believe that AM can act as a slow releasing drug reservoir [19, 20].

The CLAY Study [21] showed that the incidence of corneal infiltrative events in children wearing soft contact lenses is no higher than in adults. In the youngest group, the rate of adverse events was the lowest, probably due to greater parental supervision. It is worth noticing that about half of these infections have occurred during the first two years of using contact lenses. Cessation of overnight contact lenses use and compliance with proper hygiene can reduce the risk of infection by 60–70%. Therefore, patient education remains the most important aspect of contact lens-related keratitis prevention. Lens users should be instructed to remove their contact lenses if they experience any distressing symptoms and seek proper ophthalmological aid.

## CONCLUSIONS

With the increasing popularity of contact lens wear, contact lens-related keratitis is becoming more prevalent. It is essential to inform patients and their parents/guardians about possible complications resulting from contact lenses wear. They have to be educated on their appropriate use, storage and adequate hygiene.

The etiology of corneal inflammatory lesions is wide ranging although initial symptoms are often similar. The case of polymicrobial keratitis presented above highlights the importance of considering the possibility of coinfection, especially in the case of contact lens-related keratitis. It should be noted that *Acanthamoeba* spp. as well as *Candida* infections require careful and regular follow-ups.

*Figures: from the author's own materials.*

## CORRESPONDENCE

**Marta Świerczyńska, MD**

Department of Ophthalmology,  
Kornel Gibiński University Clinical Center,  
Medical University of Silesia, Katowice, Poland  
35 Ceglana Street, 40-514 Katowice, Poland  
phone: +48 697314696  
e-mail: m.swierczynska93@gmail.com

## ORCID

Marta Świerczyńska – ID – <http://orcid.org/0000-0001-5734-2456>  
Agnieszka Tronina – ID – <http://orcid.org/0000-0002-3651-4017>  
Michał Bogocz – ID – <http://orcid.org/0000-0003-0434-4399>  
Ewa Mrukwa-Kominek – ID – <http://orcid.org/0000-0002-1541-4666>  
Erita Filipek – ID – <http://orcid.org/0000-0002-4227-1349>

## References

1. Bullimore MA. The Safety of Soft Contact Lenses in Children. *Optom Vis Sci.* 2017; 94(6): 638-46. <http://doi.org/10.1097/OPX.0000000000001078>.
2. Alipour F, Khareshi S, Soleimanzadeh M et al. Contact Lens-related Complications: A Review. *J Ophthalmic Vis Res.* 2017; 12(2): 193-204. [http://doi.org/10.4103/jovr.jovr\\_159\\_16](http://doi.org/10.4103/jovr.jovr_159_16).
3. Dart JK, Radford CF, Minassian D et al. Risk factors for microbial keratitis with contemporary contact lenses: a case-control study. *Ophthalmology.* 2008; 115(10): 1647-54, 1654.e1-3. <http://doi.org/10.1016/j.ophtha.2008.05.003>.
4. Stapleton F, Edwards K, Keay L et al. Risk factors for moderate and severe microbial keratitis in daily wear contact lens users. *Ophthalmology.* 2012; 119(8): 1516-21. <http://doi.org/10.1016/j.ophtha.2012.01.052>.
5. Sy A, Srinivasan M, Mascarenhas J et al. *Pseudomonas aeruginosa* keratitis: outcomes and response to corticosteroid treatment. *Invest Ophthalmol Vis Sci.* 2012; 53(1): 267-72. <http://doi.org/10.1167/iovs.11-7840>.
6. Twining SS, Davis SD, Hyndiuk RA. Relationship between proteases and descemetocyte formation in experimental *Pseudomonas* keratitis. *Curr Eye Res.* 1986; 5(7): 503-10. <http://doi.org/10.3109/02713688608996372>.
7. Stewart PS, Costerton JW. Antibiotic resistance of bacteria in biofilms. *Lancet.* 2001; 358(9276): 135-8. [http://doi.org/10.1016/S0140-6736\(01\)05321-1](http://doi.org/10.1016/S0140-6736(01)05321-1).
8. Hilliam Y, Kaye S, Winstanley C. *Pseudomonas aeruginosa* and microbial keratitis. *J Med Microbiol.* 2020; 69(1): 3-13. <http://doi.org/10.1099/jmm.0.001110>.
9. Lakhundi S, Siddiqui R, Khan NA. Pathogenesis of microbial keratitis. *Microb Pathog.* 2017; 104: 97-109. <http://doi.org/10.1016/j.micpath.2016.12.013>.
10. Tu EY, Joslin CE, Sugar J et al. Prognostic factors affecting visual outcome in *Acanthamoeba* keratitis. *Ophthalmology.* 2008; 115(11): 1998-2003. <http://doi.org/10.1016/j.ophtha.2008.04.038>.
11. Clarke DW, Niederkorn JY. The pathophysiology of *Acanthamoeba* keratitis. *Trends Parasitol.* 2006; 22(4): 175-80. <http://doi.org/10.1016/j.pt.2006.02.004>.
12. Maycock NJ, Jayaswal R. Update on *Acanthamoeba* Keratitis: Diagnosis, Treatment, and Outcomes. *Cornea.* 2016; 35(5): 713-20. <http://doi.org/10.1097/ICO.0000000000000804>.
13. Al-Badriyeh D, Leung L, Davies GE et al. Successful Use of Topical Voriconazole 1% Alone as First-Line Antifungal Therapy Against *Candida albicans* Keratitis. *Ann Pharmacother.* 2009; 43(12): 2103-2107. <http://doi.org/10.1345/apn.1M318>.
14. Qiao GL, Ling J, Wong T et al. *Candida* Keratitis: Epidemiology, Management, and Clinical Outcomes. *Cornea.* 2020; 39(7): 801-5. <http://doi.org/10.1097/ICO.0000000000002306>.
15. Jurkunas UV, Langston DP, Colby K. Use of voriconazole in the treatment of fungal keratitis. *Int Ophthalmol Clin.* 2007; 47(2): 47-59. <http://doi.org/10.1097/IIO.0b013e318036bd47>.
16. Gorlin AI, Gabriel MM, Wilson LA et al. Effect of adhered bacteria on the binding of *Acanthamoeba* to hydrogel lenses. *Arch Ophthalmol.* 1996; 114(5): 576-80. <http://doi.org/10.1001/archophth.1996.01100130568013>.
17. O'Day DM, Head WS. Advances in the management of keratomycosis and *Acanthamoeba* keratitis. *Cornea.* 2000; 19(5): 681-7. <http://doi.org/10.1097/00003226-200009000-00013>.
18. Mohammadpour M, Sabet FA. Long-term Outcomes of Amniotic Membrane Transplantation in Contact Lens-Induced *Pseudomonas* Keratitis with Impending Corneal Perforation. *J Ophthalmic Vis Res.* 2016; 11(1): 37-41. <http://doi.org/10.4103/2008-322X.180712>.
19. Resch MD, Resch BE, Cszimazia E et al. Permeability of human amniotic membrane to ofloxacin in vitro. *Invest Ophthalmol Vis Sci.* 2010; 51(2): 1024-7. <http://doi.org/10.1167/iovs.09-4254>.
20. Resch MD, Resch BE, Cszimazia E et al. Drug reservoir function of human amniotic membrane. *J Ocul Pharmacol Ther.* 2011; 27(4): 323-6. <http://doi.org/10.1089/jop.2011.0007>.

21. Chalmers RL, Wagner H, Mitchell GL et al. Age and other risk factors for corneal infiltrative and inflammatory events in young soft contact lens wearers from the Contact Lens Assessment in Youth (CLAY) study. Invest Ophthalmol Vis Sci. 2011; 52(9): 6690-6. <http://doi.org/10.1167/iops.10-7018>.

For non-commercial use only

**Authors' contributions:**

Marta Świerczyńska: conceptualization, writing – original draft preparation, writing – review and editing; Agnieszka Tronina: conceptualization, resources, writing – original draft preparation, writing – review and editing; Michał Bogocz: resources, writing – review and editing; Ewa Mrukwa-Kominek: resources, supervision; Erita Filipek: resources, writing – review and editing, supervision.

All authors have read and agreed to the published version of the manuscript.

**Conflict of interest:**

None.

**Financial support:**

None.

**Ethics:**

The content presented in the article complies with the principles of the Helsinki Declaration, EU directives and harmonized requirements for biomedical journals.