

# Discriminating capabilities of neural and vascular parameters of optical coherent tomography in glaucoma

Joanna Wierzbowska<sup>1,2</sup>

<sup>1</sup> Department of Ophthalmology, Central Clinical Hospital of the Ministry of National Defense, Military Medical Institute in Warsaw  
Head of Department: Prof. Marek Rękas, MD, PhD

<sup>2</sup> Optegra Eye Hospital in Warsaw  
Head: Jolanta Oficjalska, MD, PhD



## HIGHLIGHTS

OCT pRNFL analysis provides the highest sensitivity in the inferior quadrants. OCTA parameters measured within the macular region in eyes with late-stage glaucoma are a better biomarker than OCT parameters due to the later manifestation of the “floor effect”.

## ABSTRACT

Optical coherent tomography (OCT) of the retina and optic nerve disc is the gold standard for imaging in the diagnosis and monitoring of glaucoma and optical coherence tomography angiography (OCTA) is an imaging technique with great scientific and clinical potential in patients with glaucomatous neuropathy. The main advantages of OCT and OCTA are non-invasiveness, speed, repeatability and availability of the procedure. In the article, on the basis of recent meta-analyses, the discriminating abilities of the peripapillary retinal nerve fiber layer (pRNFL) and macular parameters as measured with spectral domain (SD) and swept source (SS) OCT, in all glaucoma patients and in different glaucoma subpopulations were discussed. In addition, the results of the most important research on OCTA in the diagnosis and monitoring of glaucoma and the limitations of this method are listed.

**Key words:** glaucomatous optic neuropathy, diagnosis, optical coherent tomography, optic nerve head, nerve fibers

## INTRODUCTION

Glaucoma is a chronic optic neuropathy which is characterized by progressive loss of retinal ganglion cells (RGCs) and their axons and glial tissue, which leads to characteristic structural damage to the optic nerve head (ONH), retinal nerve fiber layer (RNFL) and visual field (VF) defects. Glaucoma is an incurable disease, however, early diagnosis and appropriate treatment allow to control the course of neuropathy and maintain a useful vision in many patients. For a long time of duration glaucoma is asymptomatic. Visual field defects can be detected with standard automated perimetry (SAP) when approximately 40% of RGCs are lost [1]. Therefore, structural evaluation of the ONH and surrounding RNFL are of particular importance in early glaucoma and allow to detect a loss of the nervous tissue even several years before VF defects occur.

## OPTICAL COHERENT TOMOGRAPHY

Optical coherent tomography (OCT) is a non-invasive, highly reproducible imaging technique that provides high resolution, colored linear scans of ocular tissues. In glaucoma diagnosis, OCT enables in vivo quantitative assessment of peripapillary RNFL (pRNFL), ONH and macula indices. Some pRNFL and macula thickness parameters can be also monitored over time. OCT, since it was launched in 2002, has evolved over the past decade. The spectral technique (SD-OCT), that was introduced in 2006 and replaced time-domain imaging (TD-OCT) as well as the swept source device (SS-OCT) enables high-speed data acquisition and better visualization of the anatomy of posterior vitreous structures, retina and choroid [2].

The human retina contains approximately 1.2 million RGCs, 50% of which are located in the central 8 degrees of the foveola [3]. Numerous studies have confirmed the relevance of macular ganglion cell complex (GCC) thickness, which comprises three innermost layers of the retina: RNFL, ganglion cell layer (GCL) and inner plexiform layer (IPL) in diagnosis of early glaucoma [4, 5]. Macular region is characterized by less anatomical variability and better reproducibility of measurements as compared to pRNFL and ONH. In some OCT devices, the GCL plus IPL algorithm (GCIPL) is also available, which eliminates the RNFL parameter from the analysis. It was assumed that the GCIPL algorithm, examining the area twice lower than the GCC algorithm can provide parameters with higher diagnostic sensitivity (like minimum GCIPL) than GCC, particularly in the early stages of glaucoma. In order to increase the diagnostic accuracy of the GCC algorithm, focal loss (FLV) and global loss of GCC volume (GLV) analyses were implemented in the software of some SD-OCT devices.

OCT possess also some limitations and traps, responsible for false-positive results. Interpretation of SD-OCT exami-

nations requires a rigorous technique and comparison with data of the clinical examination. A number of conditions, such as variability of normal optic discs, anomalies associated with myopia, limitations of the normative database or artifacts (blink, saccades, media opacities, segmentation errors) may produce confounding outcomes, which, without being verified by clinical examination, may lead to incorrect classifications and/or incorrect therapeutic decisions towards for both healthy and sick eyes [6]. Also “floor effect” observed in OCT scans of eyes with late-stage glaucoma makes the follow-up of the structural changes in pRNFL below the 45–55  $\mu\text{m}$  threshold no longer possible. Interpretation of the isolated deterioration of macular OCT indices should be based on correlation of local indices with pRNFL analysis and fundus findings. Technological differences that occur between different OCT platforms or generations of the same devices cause that the results obtained on them should not be quantitatively compared.

The main objective of the meta-analysis of Kansal et al. [7] that was published in 2018, was to compare the glaucoma diagnostic accuracy of pRNFL and macular parameters obtained by five most commonly used OCT devices. 150 clinical trials involving 16 104 eyes with glaucoma and comparative group of 11 543 healthy eyes were included. Areas under the receiver operating characteristic (ROC) curve (AUROCs) of following variables were compared: pRNFL thickness (average and of individual sectors), GCC thickness (average, in superior and inferior hemispheres), focal loss volume (FLV) and total GCC loss (global loss volume, GLV), GCIPL thickness (average, in individual sectors and minimal) and total thickness of the macula (the last variable related to TD-OCT technology). Pooled AUROCs of pRNFL and macular OCT parameters for all glaucoma patients and for different glaucoma subpopulations are reported in table 1.

The meta-analysis revealed that in the population of all glaucoma patients, AUROC was the highest for the average pRNFL thickness (0.897), then for the pRNFL thickness in the inferior (0.895) and superior (0.855) sectors. In the same population, the diagnostic accuracy of the GCIPL model was highest for the minimum thickness (AUROC 0.898) followed by the thicknesses: in the inferotemporal (0.877), inferior (0.860), average (0.858) and superotemporal (0.825) sectors. The AUROCs in the GCC model were the highest for the average thicknesses of GCC and FLV (both 0.885), then for the GCC thicknesses in the inferior hemisphere (0.875) and GLV (0.868). In this analysis, no statistical differences were found in the diagnostic accuracy of average thicknesses of pRNFL, GCC and GCIPL as glaucoma classifiers (AUROCs 0.897, 0.885 and 0.858, respectively).

The pRNFL, GCC and GCIPL parameters had also similar diagnostic accuracy in differentiating between perimetric

TABLE 1

Pooled AUROCs of pRNFL and macular OCT parameters in all glaucoma patients and in different glaucoma subpopulations.

OCT parameters	AUROC pRNFL			AUROC Macula – GCC					AUROC Macula – GCIPL			
	Ave	Inf	Sup	Ave	Inf	Sup	GLV	FLV	Ave	Inf	Sup	Min
All glaucoma	0.897	0.895	0.855	0.885	0.875	0.812	0.868	0.885	0.858	0.860	0.797	0.898
Perimetric	0.905	0.907	0.870	0.895	0.883	0.817	0.895	0.874	0.864	0.861	0.787	0.904
Pre-perimetric	0.831	0.828	0.774	0.797	0.803	0.755	0.824	0.769	0.762	0.756	0.739	-
Mild	0.907	0.897	0.854	0.861	0.850	0.789	-	-	-	-	-	-
Moderate to advanced	0.964	0.953	0.914	0.938	0.911	0.852	0.926	0.927	-	-	-	-
Myopic	0.917	0.937	0.880	0.953	0.939	0.913	0.924	0.898	0.905	0.918	0.851	-

OCT – optical coherent tomography; AUROC – area under the receiver operating characteristic curve; pRNFL – peripapillary retinal nerve fiber layer; GCC – ganglion cell complex; GCIPL – ganglion cell layer plus inner plexiform layer; Ave – average; Inf – inferior; Sup – superior; GLV – global loss volume; FLV – focal loss volume; Min – minimum.

glaucoma and healthy eyes; the AUROCs of these markers did not differ significantly, although their values were higher than those for general population of glaucoma (AUROCs 0.905, 0.895 and 0.864, respectively).

In the eyes with pre-perimetric glaucoma, the diagnostic accuracy of average pRNFL thickness was significantly higher than that of GCC and GCIPL (AUROCs 0.831, 0.797 and 0.762, respectively). Of the pRNFL parameters, the average thickness and thickness in the inferior and superior quadrants had a statistically higher AUROCs compared to the AUROCs of the other indices (AUROCs 0.831, 0.828 and 0.774, respectively) [7].

Higher diagnostic accuracy of pRNFL parameters than the macular ones may be due to the fact that primary damage in glaucoma refers to nerve fibers and precedes the loss of RGCs. It is assumed that neuronal degeneration of the neuron is starting from the synapses and is progressing backwards towards its soma in the mechanism of “dye-back” [8]. Sequential, slow injury and death of RGCs may last several years at the “subthreshold”, quantitatively undetectable level, even in the area of macula.

However, when interpreting numerical values for global, sectorial and meridian mean pRNFL in eyes suspected of glaucoma it should be taking into account that there are interindividual variations of average pRNFL thickness, ranging between 89 and 113  $\mu$ m in healthy eyes. According to Hood [9], in the presence of a paracentral scotoma, projection of GCC defect visualized on the OCT deviation map of probability of changes onto the 10-2 VF examination provides more precise comparative analysis than considering the numerical parameters of the OCT.

It was shown in Kansal [7] study that the pRNFL and GCC OCT parameters had similar diagnostic accuracy at distinguishing between eyes with moderate to severe glaucomatous eyes and those without glaucoma. In eyes with advanced glaucoma GCC or GCIPL analysis can be used

to monitor glaucoma progression when analysis of pRNFL is no longer reliable because of the floor threshold.

The diagnosis of glaucoma in moderate or high myopic eyes remains a challenge due to the numerous anatomical variants accompanying myopia which generate a high false-positive rate. According to the data from Kansal study [7], in myopic eyes with glaucoma, the diagnostic accuracy of average thicknesses of RNFL, GCC and GCIPL were similar (AUROCs 0.917, 0.905 and 0.953, respectively). The nasal RNFL thickness was demonstrated to have the lowest diagnostic value as a glaucoma classifier in myopic eyes (AUROC 0.617). In clinical practice, analysis of the GCC is very reproducible in eyes with high myopia and is a very reliable marker in myopic eyes with accompanying severe peripapillary atrophy.

It was demonstrated by Lin et al. [10] that the best parameters distinguishing eyes with early normal tension glaucoma (NTG) from those without glaucoma are: average pRNFL thickness (AUROC 0.896), pRNFL thickness in the superior-temporal sector (AUROC 0.882) and GCC thickness in the superior outer sector (AUROC 0.820).

The basis of another review, made by Oddone et al. [11] in 2016, were 34 studies in which the SD-OCT analysis of 5026 eyes were subjected. The study showed similar or slightly lower diagnostic accuracy of macular parameters compared to pRNFL parameters in glaucoma. The authors found that the thickness of pRNFL in the inferior sectors and the minimum thickness of GCIPL were the best SD-OCT markers, distinguishing the eyes with perimetric glaucoma from healthy eyes.

Glaucoma is a disease of the optic nerve and the presence of documented glaucoma changes within the ONH is the reference standard for the diagnosis of glaucoma. However, measurements within ONH with OCT are less relevant than pRNFL and GCC/GCIPL analysis due to the multiple anatomical variants of healthy optic discs, ONH anoma-

lies (tilted disc syndrome, drusen, high myopia) and frequent presence of PPA. The clinical interpretation of ONH morphology should always take into account disc size and clinical appearance of the optic disc. Asymmetrical ONH lesions are always a warning sign. It was shown by Xu et al. [12] that rim area was the most discriminant ONH parameter (AUROC 0.861). However, rim area was a significantly weaker glaucoma classifier than the average thickness of RNFL and the minimum thickness of GCL-IPL (AUROCs 0.904 and 0.892, respectively). New algorithms of the detection of the extremities of Bruch's membrane (minimum rim width, MRW) such as mean global MRW, inferior temporal MRW and BMO-MRW index) precise an ONH lesion [13].

### OPTICAL COHERENT TOMOGRAPHY ANGIOGRAPHY

Optical coherent tomography angiography (OCTA) is a non-invasive, static technique, in which red blood cells play role as a natural contrast agent to create three-dimensional images of microvascular networks at a given time. The beginning of the OCTA era dates back to 2007, when the Doppler technique was successfully combined with the spectral domain. In the following years, various algorithms (OMAG, SSADA, OCTARA and speckle variance) for the analysis of changes in the reflection signals were introduced.

In macula region the OCTA software automatically visualizes blood vessels in four segments:

1. the superficial vascular plexus (a regular network around the foveal avascular zone [FAZ]) formed by the branches of the central retinal artery)
2. the deep vascular plexus (formed by the vessels of the inner nucleated and outer plexus layers)
3. at the level of the outer layers of retina (where vessels are absent)
4. in choriocapillaries.

The analysis may concern the whole en face image, the parafoveal and the perifoveal regions; 6 mm × 6 mm scans are best used for testing.

In the optic disc region, the OCTA examination shows four layers:

1. vessels at the vitreous level (visible only in the neovascularization on the ONH)
2. vessels on the surface of the retina and the ONH, i.e. central retinal artery and vein with their branches
3. radial peripapillary capillaries (RPC) located in the RNFL
4. vessels at the level of the retinal pigment epithelium (absent in healthy eyes).

To test the blood flow in the optic disc region, 4.5 mm × 4.5 mm scans are best used and the analysis may concern:

the whole *en face* image, the papillary region, the peripapillary region and area within the disc.

The OCTA software measures the various parameters:

1. vessel density (VD), defined as the percentage area occupied by vessels in the tested region
2. disc flow index (DFI), flow index (FI) or blood flow index (BFI)
3. the peripapillary deep-layer microvascular dropout (MvD)
4. area and diameters of FAZ.

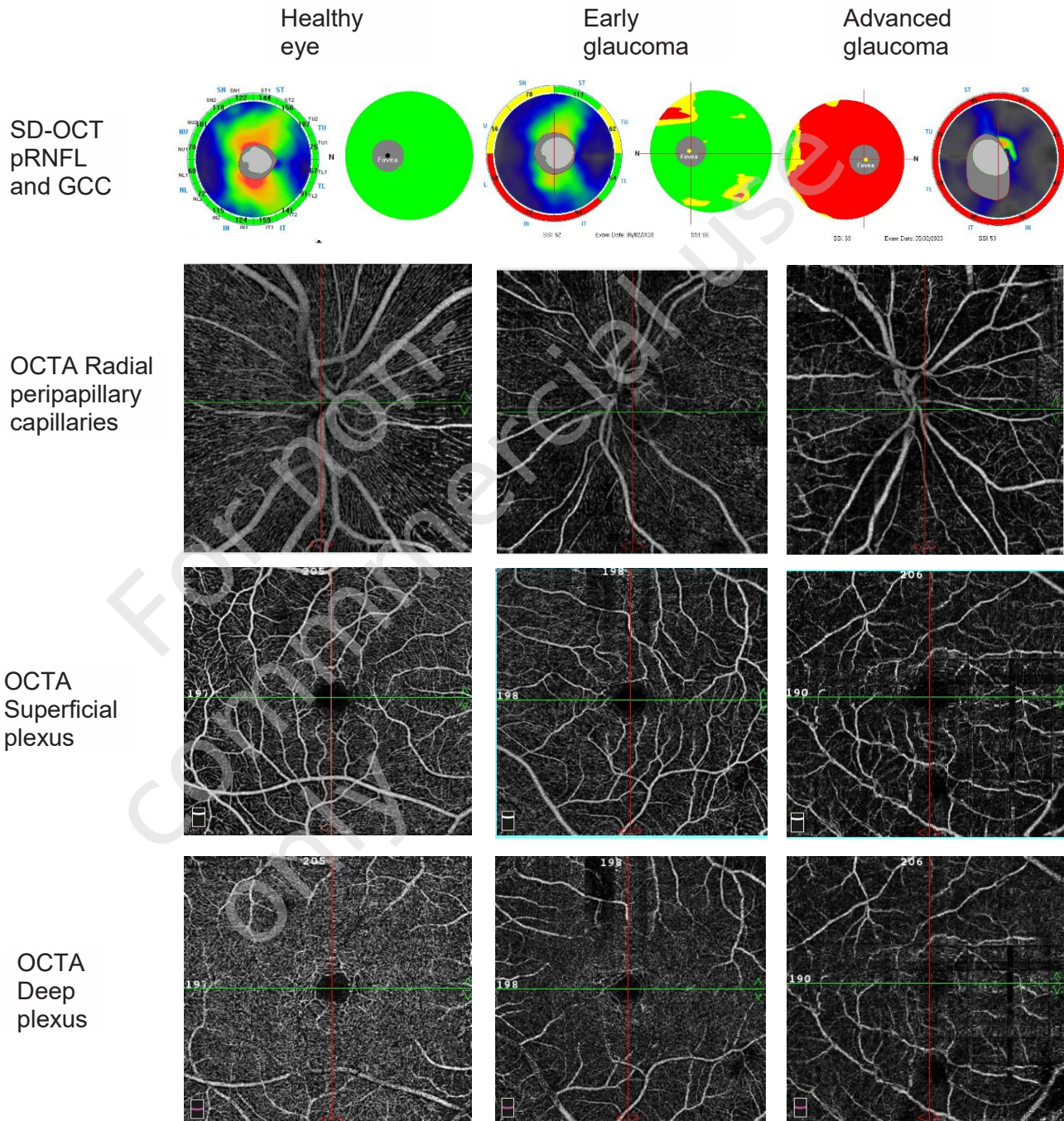
In OCTA, glaucoma eyes demonstrate areas with an atrophic network of RPCs, superficial and deep vascular plexus, often corresponding to a focal thinning of the RNFL (fig. 1). The greatest differences in the parameters of OCTA in the peripapillary region between patients with glaucoma and healthy patients were found in the inferior-temporal and superior-temporal sectors [14–16]. The area in the macular region that is most susceptible to damage in glaucoma is the inferior-temporal region [17, 18]. Kuryшева et al. [19] showed that in the differentiation between early glaucoma eyes and healthy eyes, the diagnostic accuracy of the whole en face macula image density of the superficial vascular plexus was significantly higher than that of the peripapillary region and the optic disc. On the other hand, in the differentiation of eyes with moderate and advanced glaucoma and eyes with early glaucoma, the highest value as the OCTA classifier was demonstrated for the RPC density in the inferior-temporal sector (whole en face ONH image) [19].

In the study by van Melkebeke et al. [20], published in 2018, the value of OCTA in patients with various types of glaucoma, on the basis of 54 full-text articles was analyzed. The analysis showed that OCTA is a test with high repeatability and reproducibility both in healthy and glaucoma eyes (coefficient of repeatability, CR < 7%). OCTA parameters were significantly decreased in glaucoma eyes and had diagnostic accuracy similar to SD-OCT structural parameters. The highest diagnostic accuracy, measured as the AUROC was demonstrated by the parameters – VD and FI in the peripapillary region and in the 6 mm × 6 mm macular region. OCTA vessel density was significantly reduced in eyes with normal tension glaucoma (NTG), ocular hypertension, preperimetric glaucoma and in eyes suspected of glaucoma. It was shown by Köse et al. [21], that the whole en face macula image density of the superficial vascular plexus was significantly lower in eyes with pseudoexfoliation glaucoma than in eyes with primary open-angle glaucoma (POAG). Zivkovic et al. [22] have found that horizontal, vertical and maximum diameters as well as the area of FAZ was significantly increased in eyes with NTG as compared to the healthy eyes. In eyes with angle-closure glaucoma, OCTA parameters appear to be a less accurate diagnostic param-



FIGURE 1

Thickness maps of the peripapillary retinal nerve fiber layer, angiograms of radial peripapillary capillaries, angiograms of macular superficial and deep vascular plexus in the healthy eye, in the eye with early glaucoma and in the eye with advanced glaucoma.



OCTA – optical coherent tomography angiography; SD-OCT – spectral-domain optical coherent tomography.

eter than OCT structural parameters, presumably due to less frequent perfusion abnormalities compared to the eyes with POAG.

The analysis also showed that OCTA hemodynamic parameters correlated with SD-OCT structural parameters and functional SAP or microperimetry indices. Moreover,

some authors [23] have found that the correlation between the mean retinal sensitivity as measured by microperimetry and the mean superficial plexus density of the whole macula is greater than the correlation between mean defect (MD) SAP and mean RNFL thickness in the peripapillary area. They showed also that the hemodynamic parameters

of OCTA and structural parameters of SD-OCT have comparable diagnostic sensitivity [23].

It was also demonstrated that the parameters of OCTA measured within the macular region in eyes with late-stage glaucoma are more sensitive biomarkers of the damage than the structural parameters of OCT. It has been also shown that the density of superficial vascular plexus of the macular region has a much lower threshold level than pRNFL and allows the monitoring of structural changes in the late stages of very advanced glaucoma up to the MD level of -25 decibels (dB) [24].

The studies published so far have provided preliminary data on the usefulness of OCTA technology in monitoring glaucoma progression. It has been shown by Moghimi et al. [25] in a 2-year prospective study, that lower baseline mean superficial vascular plexus density of the whole macula (< 50.4%) and lower mean RPC density of the whole ONH (< 52.5%) are associated with greater progression in perimetric glaucoma eyes.

OCTA possess also considerable limitations such as the lack of a normative basis and the influence of pupil width, haze of optical structures, saccades and unstable fixation

of the patient on the strength of the reflection signal and examination artifacts. Vascular density (VD) measured by OCTA is a more variable parameter than pRNFL thickness, which may be influenced during the measurement by such factors as: intraocular pressure fluctuations, systemic circulation, vascular dysregulation, oxygenation in the retina or hypercapnia.

## CONCLUSION

Considerable progress which have been made in OCT and OCTA technology during last two decades resulted in increasing precision in the structural analysis of various regions and tissues affected by glaucoma. However, OCT findings need to be analyzed in detail and must be interpreted in the light of clinical findings and visual field examination. OCTA is an imaging technique with great scientific and clinical potential, which may contribute to increase the knowledge about the pathogenesis of glaucoma. Further research is needed to determine the usefulness of OCTA technology in monitoring the progression of glaucoma.

*Figures: from the author's own materials.*

## CORRESPONDENCE

**Joanna Wierzbowska, MD, PhD, Assoc. Prof.**

Department of Ophthalmology,  
Central Clinical Hospital of the Ministry of National Defense,  
Military Institute of Medicine  
04-141 Warszawa, ul. Szaserów 128  
e-mail: jwierzbowska@wim.mil.pl

## ORCID

Joanna Wierzbowska – ID – <http://orcid.org/0000-0002-6993-7518>

## References

1. Quigley HA, Dunkelberger GR, Green WR. Retinal ganglion cell atrophy correlated with automated perimetry in human eyes with glaucoma. *Am J Ophthalmol.* 1989; 107: 453-64.
2. Park HY, Shin HY, Park CK. Imaging the posterior segment of the eye using swept-source optical coherence tomography in myopic glaucoma eyes: comparison with enhanced-depth imaging. *Am J Ophthalmol.* 2014; 157: 550-7.
3. Agudo-Barriuso M, Villegas-Pérez MP, de Imperial JM et al. Anatomical and functional damage in experimental glaucoma. *Curr Opin Pharmacol.* 2013; 13: 5-11.
4. Lee SY, Lee EK, Park KH et al. Asymmetry Analysis of Macular Inner Retinal Layers for Glaucoma Diagnosis: Swept-Source Optical Coherence Tomography Study. *PLoS One.* 2016; 11: e0164866.
5. Chen MJ, Yang HY, Chang YF et al. Diagnostic ability of macular ganglion cell asymmetry in Preperimetric Glaucoma. *BMC Ophthalmol.* 2019; 19: 12.
6. Asrani S, Essaid L, Alder BD et al. Artifacts in spectral-domain optical coherence tomography measurements in glaucoma. *JAMA Ophthalmol.* 2014; 132: 396-402.
7. Kansal V, Armstrong JJ, Pintwala R et al. Optical coherence tomography for glaucoma diagnosis: An evidence based meta-analysis. *PLoS One.* 2018; 13: e0190621.
8. Nickells RW. Retinal ganglion cell death in glaucoma: the how, the why, and the maybe. *J Glaucoma.* 1996; 5: 345-56.

9. Hood DC. Improving our understanding, and detection, of glaucomatous damage: An approach based upon optical coherence tomography (OCT). *Prog Retin Eye Res.* 2017; 57: 46-75.
10. Lin JP, Lin PW, Lai IC et al. Segmental inner macular layer analysis with spectral-domain optical coherence tomography for early detection of normal tension glaucoma. *PLoS One.* 2019; 14: e0210215.
11. Oddone F, Lucenteforte E, Michelessi M et al. Macular versus Retinal Nerve Fiber Layer Parameters for Diagnosing Manifest Glaucoma: A Systematic Review of Diagnostic Accuracy Studies. *Ophthalmology.* 2016; 123: 939-49.
12. Xu X, Xiao H, Guo X et al. Diagnostic ability of macular ganglion cell-inner plexiform layer thickness in glaucoma suspects. *Medicine (Baltimore).* 2017; 96: e9182.
13. Torres LA, Jarrar F, Sharpe GP et al. Clinical relevance of protruded retinal layers in minimum rim width measurement of the optic nerve head. *Br J Ophthalmol.* 2018 pii: bjophthalmol-2018-313070. <http://doi.org/10.1136/bjophthalmol-2018-313070>.
14. Chen HS-L, Liu C-H, Wu W-C et al. Optical coherence tomography angiography of the superficial microvasculature in the macular and peripapillary areas in glaucomatous and healthy eyes. *Invest Ophthalmol Vis Sci.* 2017; 58: 3637-45.
15. Yarmohammadi A, Zangwill LM, Diniz-Filho A et al. Optical coherence tomography angiography vessel density in healthy, glaucoma suspect and glaucoma eyes. *Invest Ophthalmol Vis Sci.* 2016; 57: OCT451-OCT459.
16. Rao HL, Pradhan ZS, Weinreb RN et al. Relationship of optic nerve structure and function to peripapillary vessel density measurements of optical coherence tomography angiography in glaucoma. *J Glaucoma.* 2017; 26: 548-54.
17. Triolo G, Rabiolo A, Galasso M et al. Assessment of peripapillary and macular vessel density estimated with OCT-angiography in glaucoma suspects and glaucoma patients. *Invest Ophthalmol Vis Sci.* 2017; 58: 715.
18. Silva L, Suwan Y, Jarukasetphon R et al. Retinal ganglion cell layer by Fourier-domain optical coherence tomography and microvasculature by optical coherence tomography angiography at the macular region in glaucoma. *Invest Ophthalmol Vis Sci.* 2017; 58: 712.
19. Kuryshva NI, Maslova EV, Zolnikova IV et al. A Comparative Study of Structural, Functional and Circulatory Parameters in Glaucoma Diagnostics. *PLoS One.* 2018; 13: e0201599. <http://doi.org/10.1371/journal.pone.0201599>.
20. Van Melkebeke L, Barbosa-Breda J, Huygens M et al. Optical Coherence Tomography Angiography in Glaucoma: A Review. *Ophthalmic Res.* 2018; 60: 139-51.
21. Köse HC, Tekeli O. Optical coherence tomography angiography of the peripapillary region and macula in normal, primary open angle glaucoma, pseudoexfoliation glaucoma and ocular hypertension eyes. *Int J Ophthalmol.* 2020; 13: 744-54.
22. Zivkovic M, Dayanir V, Kocaturk T et al. Foveal Avascular Zone in Normal Tension Glaucoma Measured by Optical Coherence Tomography Angiography. *Biomed Res Int.* 2017; 2017: 3079141.
23. Zabel K, Zabel P, Kaluzna M et al. Correlation of retinal sensitivity in microperimetry with vascular density in optical coherence tomography angiography in primary open-angle glaucoma. *PLoS One.* 2020; 15: e0235571.
24. Moghimi S, Bowd C, Zangwill LM et al. Measurement Floors and Dynamic Ranges of OCT and OCT Angiography in Glaucoma. *Ophthalmology.* 2019; 126: 980-8.
25. Moghimi S, Zangwill LM, Pentead RC et al. Macular and Optic Nerve Head Vessel Density and Progressive Retinal Nerve Fiber Layer Loss in Glaucoma. *Ophthalmology.* 2018; 125: 1720-8.

**Conflict of interest:**

None.

**Financial support:**

None.

**Ethics:**

The content presented in the article complies with the principles of the Helsinki Declaration, EU directives and harmonized requirements for biomedical journals.