

Ptosis – diagnostics and treatment

Mateusz Jacuński, Dominika Białas, Radosław Różycki

Military Institute of Aviation Medicine, Warsaw
Head of Clinic: Radosław Różycki, MD, PhD



HIGHLIGHTS

The low position of the upper eyelid affects a lots of patients.

Effective ptosis correction, which enables the improvement of the appearance of the eyes and visual acuity, is a complex process. The most important parts of this process are thorough diagnostics and selection of the right treatment method.

ABSTRACT

It is estimated that the low position of the upper eyelid affects over 1 million patients in Poland. Ptosis limits the visual field, causes compensatory head positions and the feeling of visual deterioration. The unaesthetic appearance of the eyes additionally contributes to low self-esteem. The aim of this article is to review modern diagnostic algorithms used in the case of a dropped eyelid. The paper also discusses the surgical techniques that are used in the case of ptosis and the guidelines for the correct qualification of the patient to a given surgical method.

Key words: ptosis, surgical techniques, müllerectomy, levator advancement, frontalis sling eyelid suspension

INTRODUCTION

Ptosis (from the Greek *ptosis* – I fall) is a term that refers to an incorrectly low position of the eyelid edge. In case of the upper eyelid, the main criterion of clinical diagnosis of ptosis is the lowering of the free edge by 1–2 mm in relation to the upper edge of the corneal limbus in the original gaze direction (straight ahead). Drooping eyelids are one of the most common disorders in ophthalmic practice, but data from large-population studies are limited. Estimates of the incidence of ptosis depending on the region vary between 4.7% and 13.5% in the adult population and confirm the universal nature of the disease. Women suffer more often (13.2% compared to 9.0% of men) [1, 2]. In the UK, ptosis affects 11.5% of the adult population over the age of 50. With age, the frequency of this disease increases – in individual age groups and amounts to, respectively: 50–59 years: 2.4%, 60–69 years: 8.9%, 70–79 years: 12.5%, and in the group of ≥ 80 years: 42.9% [1]. Ptosis is not only a cosmetic defect, but mainly a functional one, limiting the visual field in the upper part. Due to the reduced amount of light entering the eye, it reduces visual acuity, especially at night. Patients with ptosis report difficulty reading as the drooping eyelid worsens when looking down. There are neck pains resulting from the compensatory head positioning. The lowering of the edge of the upper eyelids also has social consequences. It has been shown that people with ptosis are perceived as less attractive, sad, depressive [1], which often leads to anxiety and alienation. In children, untreated ptosis can lead to amblyopia as well as have adverse psychological effects. Ptosis can be congenital (diagnosed up to the first year of life) or acquired (manifesting itself after the first year of life). Among acquired ptosis, the isolated form is distinguished – not related to systemic diseases, and the non-isolated form, which is at least one of the symptoms of systemic diseases. The most common type of isolated ptosis is involutional ptosis resulting from disturbed activity or position of the levator aponeurosis. We divide the acquired non-isolated ptosis into:

- neurogenic (resulting from paralysis of the oculomotor nerve, Horner's syndrome or, less frequently, defects of the central nervous system)
- neuromuscular (included in the autoimmune diseases such as myasthenia gravis)
- neurotoxic (caused by paralysis of neuromuscular connections, e.g. after bites by snakes, arachnids, or after incorrect administration of botulinum toxin)
- myopathic disease (caused by a disorder of the levator eyelid muscle)
- mechanical (in the course of local growth within the eyelid, such as chalazion, tumors, cysts or neurofibromas, making the eyelid too heavy for the levator muscle)
- traumatic (resulting from direct injury to the eyelid muscles).

Drooping of the upper eyelids should not be confused with dermatochalasis of the upper eyelids, which in most cases is only an aesthetic problem.

PTOSIS DIAGNOSTICS

The examination of a patient with ptosis consists of a thorough ophthalmological and general medical history, physical examination with measurements of the protective apparatus of the eye and additional diagnostic tests.

The examination begins as soon as the patient enters the office. The ophthalmologist should pay attention to the position of the patient's head. The chin is raised to compensate for the upper visual field defect. As a result, patients often complain of pain in the cervical spine. Also, the position of the eyebrows and the number of forehead wrinkles can be a clue in the diagnostic process. Drooping of the upper eyelids is accompanied by hyperfunction of the frontal muscle, which patients try to correct the position of the drooping eyelids. Patients with ptosis may report a feeling of heaviness in the eyelids, a "tired" appearance of the face, headaches associated with an overactive frontal muscle, but most of all a limitation of the visual field in the upper quadrants, which makes it difficult to read, drive a car, reach for objects and many other daily activities. In the ophthalmological history, it is important to ask about the dynamics of ptosis progression and the occurrence of its daily fluctuations. The ptosis that worsens in the evening may indicate myasthenia gravis, especially if there is additionally diplopia. Sudden ptosis may suggest the presence of posterior communicating artery aneurysm [3]. The patient should be asked about the history of ophthalmologic procedures, injuries, use of contact lenses, habitual rubbing of the eyes, smoking, medications used (these are risk factors for ptosis), but also to deepen the internal medical history by asking about metabolic diseases such as diabetes or thyroid diseases.

During the ophthalmic physical examination visual acuity, pupillary responses to light (attention to Horner's syndrome, 3rd paralysis), and globe mobility (disturbed in chronic progressive external ophthalmoplegia, myasthenia gravis, III nerve paralysis) is assessed. The eyelids and bone margins of orbita should be palpated. It is important to assess the protective mechanisms of the eyeball – Bell's reflex, the condition of the surface of the eyeball and the sensation of the cornea – needed after the repair of ptosis. If these mechanisms fail, the risk of exposure keratopathy increases significantly. In doubtful situations, such as exophthalmia or enophthalmia, a Hertel exophthalmometer should be used, excluding pseudoptosis. Other causes of apparent ptosis are retraction of the eyelid on the other side, hypotrophy, and ptosis. It should also be mentioned the excess skin of the eyelids (dermatochalasis), which apparently re-

sembles ptosis and is not the same medical indication for the procedure [3].

Important measures in the evaluation of ptosis include:

- MRD1 (margin reflex distance 1) – the distance of the upper eyelid edge from the corneal reflex measured in the primary position straight ahead, the correct value is 4–5 mm. The relationship between MRD1 and the severity of ptosis is presented in figure 1.
- MRD2 (margin reflex distance 2) – the distance of the lower eyelid edge from the corneal reflex measured in the primary position straight ahead, the correct value is 5–5.5 mm. Figure 2 shows how MRD1 and MRD2 are assessed.
- The function of the levator palpebrae superioris muscle – it is measured when the frontal muscle is eliminated (by pressing it with the thumb) (fig. 3). The range of movement of the upper eyelid is assessed by measuring with a ruler the distance that the edge of the eyelid travels from the maximum looking down position to the maximum looking up position. The correct value of the levator muscle activity is > 12 mm. According to Berk's classification: very good when the levator function is ≥ 13 mm, good when 8–12 mm, medium when 5–7 mm, poor when < 4 mm [2].
- MCD (margin crease distance) – the vertical distance of the upper eyelid crease from the upper eyelid edge measured looking downwards in the center of the eye-

FIGURE 1

The relationship between the MRD1 value and the severity of ptosis (own drawing).

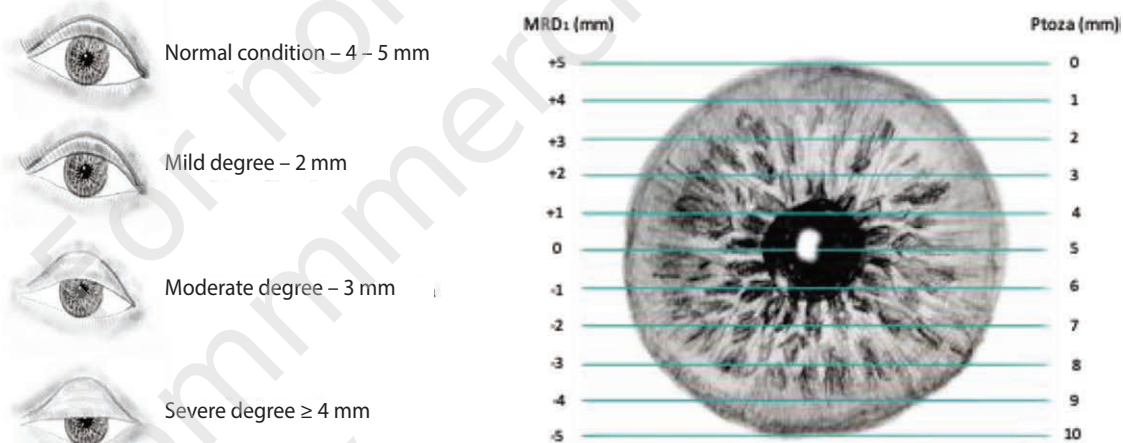
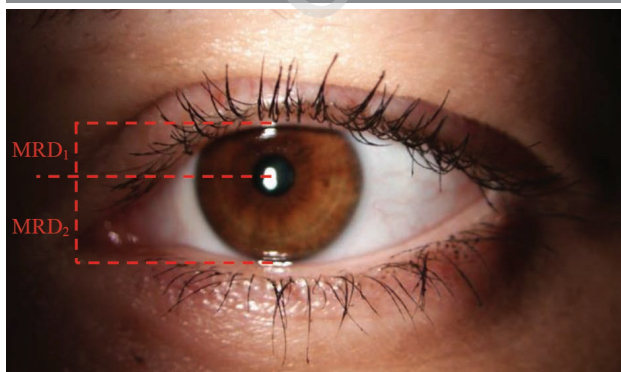


FIGURE 2

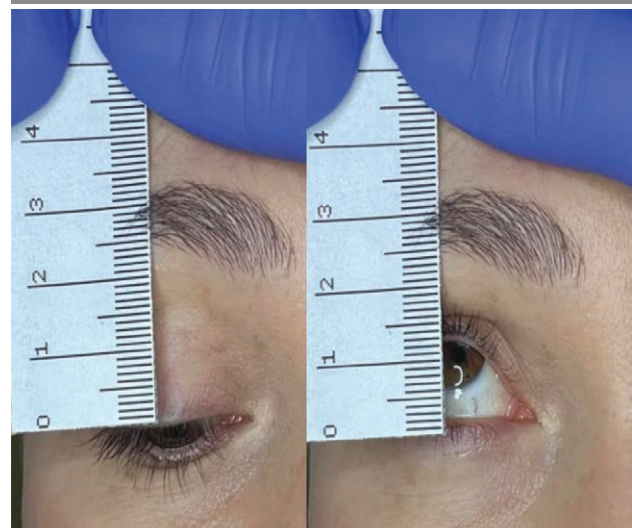
Assessment of MRD1 and MRD2 (own material).



- Palpebral fissure height – is the vertical distance in the pupil axis between the edge of the upper and lower eyelids. The sum of MRD1 and MRD2 gives the value of the palpebral fissure.

FIGURE 3

Assessment of the activity of the levator palpebrae superioris muscle.



lid. Normal values are 9–10 mm in women and 7–8 mm in men. It should be noted that the absence of a crease indicates a congenital etiology of ptosis. Increased MCD may indicate damage to the levator tendon [4–6].

The tests used in the diagnosis of ptosis are:

- **Phenylephrine test** – it is based on MRD1 assessment before administration and 5 minutes after administration of 10% phenylephrine (some authors use 2.5%). Phenylephrine as an adrenergic factor stimulates α receptors in the sympathetically innervated Müller muscle. The test is considered positive if the eyelid margin rises to a clinically significant extent, or otherwise if the MRD1 increases by 2–3 mm. In this case, it is recommended to perform a Müller muscle transconjunctival resection (müllerectomy). If the test result is negative, it is recommended to perform a repair surgery on the levator aponeurosis. However, there are exceptions to this rule - recent reports indicate the possibility of modifying a classic müllerectomy (e.g. in combination with a tarsectomy, according to nomograms other than that proposed by Dresner).
- **Fatigue test** – consists in measuring MRD1 in the original position, then the patient looks maximally up for two minutes, trying to blink as rarely as possible. After this time, MRD1 is re-measured. A decrease in MRD1 value on one or both sides indicates myasthenia gravis, but also acquired aponeurotic ptosis.
- **Ice test** – a glove filled with ice (or other clean cold object) is placed over the closed eyelid with ptosis for 2 minutes. Low temperature reduces the activity of acetylcholinesterase, thereby increasing the concentration of acetylcholine in the neuromuscular junction. The re-

duction in ptosis observed immediately after ice removal supports the diagnosis of myasthenia gravis. The test is characterized by a sensitivity of 77–89% and a high specificity of approx. 98–100% [7, 8].

- **Tensilon test** – is performed when myasthenia gravis is suspected. It consists in a slow (approx. 30 s) intravenous administration of 2 mg of edrophonium (a reversible acetylcholinesterase inhibitor). A 1 minute later, another 8 mg is administered. If the edges of the eyelids rise, then myasthenia gravis is diagnosed [6].

TREATMENT

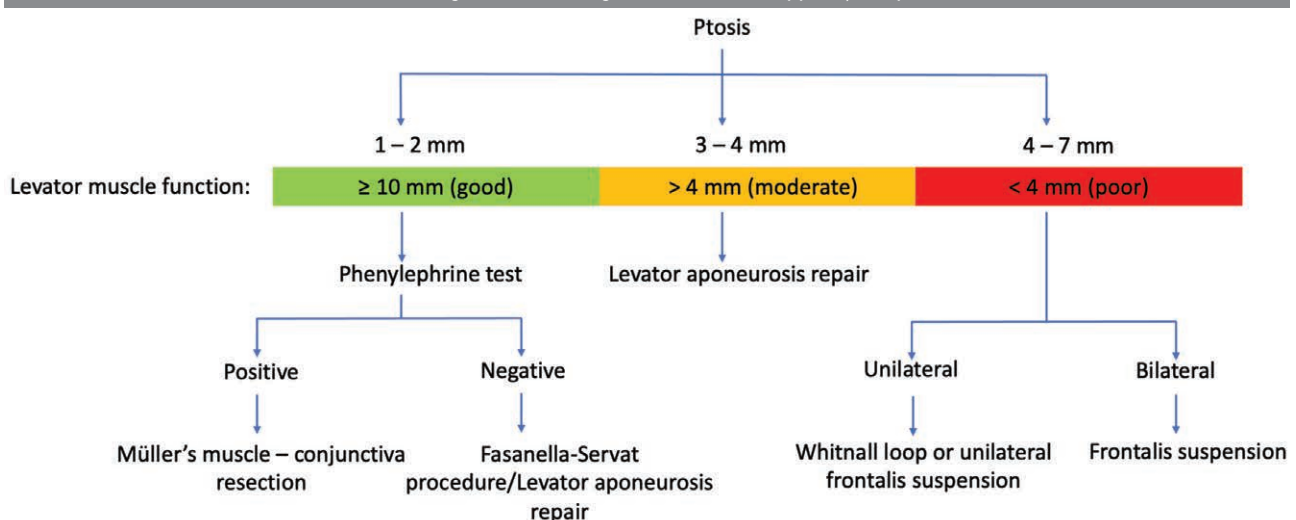
Treatment of ptosis depends on the etiology of the disease. Effective therapy includes the correct diagnosis of the causes of the disorder and the planning of an appropriate surgical method for a given patient. The severity and type of eyelid droop, as well as the degree of preservation of the levator eyelid muscle function, are the main factors influencing the choice of the operating procedure.

Depending on its severity, ptosis is divided into: minimal (1–2 mm), moderate (3–4 mm) and severe (> 4 mm) (fig. 4). Due to the existence of three upper eyelid retractors (levator palpebrae superioris muscle, the Müller muscle, the frontal muscle) and depending on the severity of ptosis, the surgical methods of correction of ptosis are generally divided into three categories:

- external/percutaneous repair of the levator palpebrae superioris muscle complex
- internal/transconjunctival repair of the levator palpebrae superioris muscle complex/Müller muscle/Müller muscle and the tarsus
- eyelid suspension on the frontal muscle.

FIGURE 4

Decision diagram for the surgical treatment of upper eyelid ptosis.



There is controversy about their relative indications, advantages and disadvantages, and the occurrence of new surgical techniques and modifications has further complicated the traditional algorithms that lead the surgeon to select a method. In patients with good levator function, surgical repair can be performed from both the posterior and anterior surgical approaches. Patients who want to obtain a more aesthetic and younger appearance (cosmetic indications) as well as patients who require improved comfort of functioning – widening visual field (medical indications) are eligible for ptosis correction.

Surgical correction of ptosis has been performed for centuries, with reports dating back to ancient Arabia and ancient Rome. Since then, hundreds of surgical techniques and their modifications have been described. The most significant changes in eyelid ptosis repair techniques come from a better understanding of eyelid anatomy and physiology. The key moment was the 1970s, when the proponents of anterior access techniques (such as Jones, Anderson and Dixon) gained the advantage [9, 10]. It was the so-called “The Age of Aponeurotic Awareness”, in which the repair of the levator aponeurosis “from the outside” was recommended to the majority of patients with ptosis while maintaining the levator muscle function [11]. In recent years, posterior approach techniques have experienced a renaissance, such as müllerectomy, and they are characterized by shorter procedure times, shorter convalescence, no scar visibility, better predictability of the effects and a lower degree of difficulty in performing the procedure compared to levator muscle procedures [12, 13].

The approach to surgical techniques of ptosis from a posterior approach has evolved over the past 60 years. The oldest technique, which was the starting point for later ones, was described by Fasanella and Servat in 1961 [14] and involved the use of two pairs of curved forceps to secure the upper 3 mm of the tarsus and 3 mm of the conjunctiva and the Müller muscle on the inverted upper eyelid [3]. In 1966, Beard popularized this method by adding to it the use of a zigzag catgut suture with an outward knot [15]. Another modification of the method was carried out by Putterman in 1972. The Putterman brace, also called clamp, in addition to ensuring haemostasis, improves the post-operative shape of the tarsus [16]. In 1973, Crawford introduced the Desmarres lid retractor in order to better visualize the levator eyelid complex and the Müller muscle [17]. In 1975, Putterman and Urist proposed a prototype of the now well-known classic Müller muscle-conjunctival resection (MMCR) [18]. It should be noted, however, that improvements to this surgical method, such as the use of tension sutures, other suturing techniques, and the development of nomograms, took place in the following years. Over time, the indications for müllerectomy have also been extended. Currently, these are: acquired involutional ptosis (changes

related to with age, chronic use of contact lenses or epi-protheses), Horner’s syndrome, survived ptosis after anterior approach surgery, congenital ptosis with good levator muscle function. In patients with mild (0.5–1.5 mm) and moderate (2–3 mm) ptosis, with good function of the levator eyelid muscle (> 10 mm), müllerectomy is the procedure of choice [12]. However, classical müllerectomy is not recommended in the case of: myogenic ptosis, ptosis with a negative phenylephrine test (although there are exceptions), ptosis with poor levator muscle function (< 10 mm) and ptosis with sudden appearance [13].

The most popular algorithm determining the scope of Müller muscle resection is a semi-linear nomogram developed in 1991 by Dresner, which makes the scope of resection dependent on the degree of eyelid droop and the degree of eyelid lift (in mm) in response to 10% phenylephrine administered to the conjunctival sac (some authors use it at a concentration of 2.5% or alternatively 0.5% apraclonidine) [8]. If the free edge of the upper eyelid rises by ≥ 2 mm after 5 minutes, the test is considered positive (phenylephrine is an agonist of the α -adrenergic receptor, and the Müller muscle is sympathetic). According to Dresner’s algorithm, for the 1 mm eyelid edge lift, 4 mm of the Müller muscle and the conjunctiva are excised. In order to obtain the desired eyelid elevation by 1.5 mm, 2 mm and 3 mm, 6 mm, 8 mm and 10 mm of the Müller muscle and the conjunctiva should be cut analogously [13] (tab. 1). It is not recommended to correct ptosis larger than 3 mm with this method.

In the external – percutaneous repair of the levator muscle complex of the upper eyelid, plastic surgery of the aponeurosis and the so-called “Whitnall loop” (with modifications). The use of these methods is recommended in patients with levator muscle function > 4 mm, with a minimal and moderate degree of advancement of ptosis. In patients with ptosis of 3–4 mm, it is the method of choice, also when müllerectomy is not indicated, eg when the phenylephrine test is negative. The individual stages of the levator aponeurosis repair surgery are as follows: linear incision in the area

TABLE 1

Nomogram for transconjunctival Müller’s muscle – conjunctiva resection according to Dresner [13].

Desired amount of eyelid lift (mm)	Scope of the müllerectomy
1.0 mm	4.0 mm
1.5 mm	6.0 mm
2.0 mm	8.0 mm
3.0 mm	10 mm

of the eyelid sulcus, dissection and opening of the orbital septum, removal of the preseptal fat in order to visualize the levator muscle aponeurosis, cutting the aponeurosis from the tarsus and separation from the Müller's muscle, suturing the aponeurosis (or a reduction of its certain height depending on the degree of ptosis). After the eyelid is positioned at the desired height, which is performed after the patient is seated on the operating table, the sutures are tied. The procedure ends with suturing the skin wound with the formation of an eyelid crease [6].

The Whitnall Loop is a procedure for maximum forward advancement of the levator tendon in which the aponeurosis is cut to the height of the Whitnall ligament and the tarsus is sutured directly to the ligament. One of the main indications of this procedure is congenital ptosis with a levator function of 4–5 mm. The limitations of the above methods are too low or too high eyelid positioning, exposure keratopathy, irregular eyelid margin, and asymmetry in the position of the eyelid crease [6]. Compared to müllerectomy, anterior approach methods are more difficult to perform, more time-consuming, may leave not aesthetic scar, and the recovery period takes longer [12].


The frontal muscle suspension is used in patients with poor levator muscle function (< 4 mm) and good frontal muscle function. The indication for the use of this method is congenital, neurogenic and myopathic ptosis, including mitochondrial diseases. The method involves the use of strips of fascia (e.g. wide thigh or temporal), silicone, gore-tex (or other non-autogenous materials) and inserting them with a needle or guide into the pre-septal space of the eyelid, and then through the eyebrows to the end point on the frontal muscle. Two incisions are made in the upper eyelid and eyebrow, and one in the area of the frontal muscle (the place where the stripes are bonded), thanks to which the strips hanging the eyelid form a characteristic pentagon (fox pentagon, see fig. 5). The limitations of the method are the risk of infection, erosion of non-autogenous materials, granuloma, lagophthalmos [6].

CONCLUSION

The frequency of occurrence and the wide clinical and functional consequences of acquired ptosis make early and accurate diagnosis and appropriate treatment extremely important issues in the daily practice of ophthalmologists. Acquired ptosis is most often caused by age-related changes in the upper eyelid retractor muscles, however, causes vary and many practices and interventions common in ophthalmology today, such as wearing contact lenses and cataract and glaucoma treatments, may also be the cause. Along with the other etiologies discussed in this article, they all require full investigation and evaluation of treatment options. Surgery is an effective treatment option for

FIGURE 5

On the left, Wright's fascia needle with a threaded silicone strap. On the right, a silicone strip arranged in a pentagonal shape, reflecting its position after the operation of suspending the upper eyelid on the frontal muscle (source: own materials).



ptosis, while non-surgical approaches are extremely limited in both number and efficiency. Since surgical treatment is limited and effective only in some patients, finding ways to introduce novel non-surgical therapeutic options into practice makes it possible to treat a much wider group of patients. Evidence of a newly approved pharmacological agent for the treatment of acquired eyelid ptosis – 0.1% oxymetazoline hydrochloride is encouraging and provide the opportunity to offer patients effective non-surgical treatment. For ophthalmologists, the availability of an approved pharmacological option can help them move from a detection-and-referral approach to a diagnosis-and-treatment approach, with referral to surgery when appropriate. Moreover, expanding treatment options may improve the patient's focus on treatment by allowing both surgical and nonsurgical approaches, depending on the underlying cause of ptosis, its severity, and the patient's preferences. While advances in the treatment of ptosis are encouraging, they remain only part of the clinical equation. In order to successfully treat ptosis, prompt and correct diagnosis is essential.

In particular, a comprehensive clinical examination and differential diagnosis is critical to understanding whether drooping eyelid is due to a primary pathology of the eyelid retractor muscles – and therefore can be effectively treated with surgical or pharmacological measures targeting the

upper eyelid, or whether an underlying cause at the root of the disease is, for example, a serious underlying neurological disease that requires other, often urgent, intervention. While in many cases ptosis can only be assessed and treated when its onset is sudden or severe, upper eyelid examination for mild to moderate or progressive cases can

be relatively easily included in a comprehensive eye examination. With a focus on awareness and diagnosis, clinical evidence-based targeted surgical or nonsurgical treatment offers hope to improve ptosis treatment for more patients.

Figures: from the author's own materials.

CORRESPONDENCE

Mateusz Jacuński, MD

Ophthalmology Clinic, Military Institute of Aviation Medicine
01-755 Warszawa, ul. Krasińskiego 54/56
e-mail: mateusz.jacunski@gmail.com

ORCID

Mateusz Jacuński – ID – <http://orcid.org/0000-0002-5554-6161>

References

- Richards HS, Jenkinson E, Rumsey N et al. The psychological well-being and appearance concerns of patients presenting with ptosis. *Eye*. 2014; 28: 296-302.
- Forman WM, Leatherbarrow B, Sridharan GV et al. A community survey of ptosis of the eyelid and pupil size of elderly people. *Age Ageing*. 1995; 24: 21-4.
- Farber SE, Codner MA. Evaluation and management of acquired ptosis. *Plast Aesthet Res*. 2020; 7: 20.
- Potemkin VV, Goltsman EV. Algorithm of objective examination of a patient with blepharoptosis. *Ophthal J*. 2019; 12(1): 45-51.
- Grob SR, Cypen SG, Tao JP. Acquired Ptosis. Springer Nature Switzerland AG 2020.
- Pauly M, Sruthi R. Ptosis: Evaluation and management. *Kerala J Ophthalmol*. 2019; 31: 11-6.
- Nair AG, Patil-Chhablani P, Venkatramani D et al. Ocular myasthenia gravis: A review. *Indian J Ophthalmol*. 2014; 62(10): 985-91.
- Monsul NT, Patwa HS, Knorr AM et al. The effects of prednisone on the progression from ocular to generalized myasthenia gravis. *J Neurol Sci*. 2004; 217: 131-3.
- Jones LT, Quickert MH, Wobig JL. The cure of ptosis by aponeurotic repair. *Arch Ophthalmol*. 1975; 93: 629-34.
- Anderson RL, Dixon RS. Aponeurotic ptosis surgery. *Arch Ophthalmol*. 1979; 97: 1123-8.
- Laplant JF, Kang JY, Cockerham KP. Ptosis repair: external levator advancement vs. Muller's muscle-conjunctiva resection – techniques and modifications. *Plast Aesthet Res*. 2020; 7: 60.
- Liao SL, Chuang AY. Various Modifications on Müller's Muscle-Conjunctival Resection for Ptosis Repair. *Arch Aesthetic Plast Surg*. 2015; 21(2): 31-6.
- Shubhra G, Cat Nguyen B. Expert Techniques in Ophthalmic Surgery; Chapter-61 Ptosis Repair: Müllerectomy 2019.
- Fasanella RM, Servat J. Levator resection for minimal ptosis: another simplified operation. *Arch Ophthalmol*. 1961; 65: 493-6.
- Beard C. The surgical treatment of blepharoptosis: a quantitative approach. *Trans Am Ophthalmol Soc*. 1966; 64: 401-5.
- Putterman AM, Urist MJ. Müller's muscle-conjunctival resection. *Arch Ophthalmol*. 1975; 93(8): 619-23.
- Crawford JS. Repair of blepharoptosis with a modification of the Fasanella-Servat operation. *Can J Ophthalmol*. 1973; 8: 19-23.
- Patel RM, Aakalu VK, Setabutr P et al. Efficacy of Muller's Muscle and Conjunctiva Resection With or Without Tarsectomy for the Treatment of Severe Involutional Blepharoptosis. *Ophthalmic Plast Reconstr Surg*. 2017; 33(4): 273-8.

For non-
commercial use
only

Authors' contributions:

Mateusz Jacuński: 50%; Dominika Białas: 30%; Radosław Różycki: 20%.

Conflict of interest:

None.

Financial support:

None.

Ethics:

The content presented in the article complies with the principles of the Helsinki Declaration, EU directives and harmonized requirements for biomedical journals.