

# Dry eye syndrome triggered by wearing gas permable contact lens in keratoconus

Karolina Stanienda-Sokół<sup>1,2</sup>, Marzena Wysocka-Kosmulska<sup>1,2</sup>,  
Jakub Słoka<sup>1</sup>, Olga Łach-Wojnarowicz<sup>1</sup>, Dariusz Dobrowolski<sup>1,2,3</sup>,  
Edward Wylęgała<sup>2,3</sup>

<sup>1</sup>Department of Ophthalmology, St. Barbara Hospital, Trauma Centre  
Head of the Department: Dariusz Dobrowolski, MD, PhD

<sup>2</sup>Chair and Clinical Department of Ophthalmology, School of Medical Science in Zabrze,  
Medical University of Silesia in Katowice  
Head of the Department: Prof. Edward Wylęgała, MD, PhD

<sup>3</sup>Department of Ophthalmology, District Railway Hospital  
Head of the Department: Prof. Edward Wylęgała, MD, PhD



## HIGHLIGHTS

As soon as an inflammatory reaction caused by wearing contact lenses appears, it is recommended to stop using the contact lenses and to implement an anti-inflammatory therapy. Steroid therapy in the early stages of treatment is crucial in suppressing inflammation. Artificial tears and moisturizing gel drops are also essential.

## ABSTRACT

A 48-year-old woman suffering from keratoconus of both eyes sought medical attention at the ophthalmology clinic with her left eye having been painful for prior 3 weeks, as well as increased sensitivity to light, foreign body sensation, stinging and watering eye. Her left eye was diagnosed with the dry eye syndrome, in addition to being treated with gas permable contact lens. Physical examination revealed corneal punctate epithelial erosions that stained positively with fluorescein in the left eye. The patient was ultimately diagnosed with dry eye disease of the left eye caused by gas permable contact lens usage.

**Key words:** dry eye disease, keratoconus, gas permable contact lens, corneal punctate epithelial erosions, tear film break-up time

## INTRODUCTION

Dry eye disease (DED) is one of the most common reasons for patients to seek ophthalmic care. There is a wide array of causes for DED that can induce an alteration of the ocular surface system and determine the chronicity of the disease, including low blink rates (eg. computer use), systemic and topical drugs, autoimmune diseases, contact lens wear, and cataract and refractive surgery. Patients with dry eye experience numerous symptoms that can reduce their productivity and overall quality of life [1, 2].

This article presents the case of a 48-year-old woman with keratoconus and dry eye symptoms caused by a gas permeable contact lens. Dry eye disease is a multifactorial disease of the tears and ocular surface that causes discomfort, visual disturbance, and tear instability with potential damage to the ocular surface. It is accompanied by increased osmolarity of the tear film and inflammation of the ocular surface. In table 1 the most common symptoms of the syndrome are presented. There are numerous causes of dry eye, which are generally subdivided into the categories of aqueous-deficiency and evaporative. Several causative factors can contribute to DED, such as topical and systemic drugs, lacrimal duct obstruction, and lacrimal deficiency. Cataract and refractive surgery can also induce dry eye syndrome or, at least, dry eye-like symptoms.

TABLE 1

Causes.
aging (> 40)
external environment (windy weather, low humidity, air conditioning)
contact lenses
low frequency of blink
eye diseases (conjunctivitis, Meibomian gland dysfunction)
general diseases (Sjogren's syndrome, xerophthalmia, allergies)
pregnancy
drugs (eye drops with BAK, antihistamines, $\beta$ -blockers, antidepressants)
ophthalmic surgery (LASIK)

BAK – benzalkonium chloride; LASIK – laser-assisted in situ keratomileusis.

In table 2 the common causes of dry eye are presented.

TABLE 2

Common dry eye symptoms.
foreign body sensation (sensation of "sand in the eye")
irritation
burning
stinging
itching
pain
blurred vision, poor vision
red eye
wet eye
higher sensitivity to the bright light
soreness, sticky eyes
intolerance to windy conditions & air conditioned
intolerance to contact lenses

## CASE PRESENTATION WITH ILLUSTRATIONS AND FIGURES

A 48-year-old woman sought medical attention at the ophthalmology clinic with her left eye having been painful for prior 3 weeks. Her other symptoms were: increased sensitivity to light, foreign body sensation, stinging and watering eye.

The patient suffered from keratoconus of both eyes. She had undergone a keratoplasty of her right eye three years before. Her left eye was being treated with gas permeable contact lens. Patient did not suffer from any other diseases and did not take other medications. She worked as an accountant with long hours spent in front of a computer, which exacerbated her symptoms.

She was diagnosed with the dry eye syndrome of her left eye. She received a treatment including an antibiotic (amikacin) and artificial tears, one drop four times a day each. Despite the treatment, the symptoms started to progressively get more severe.

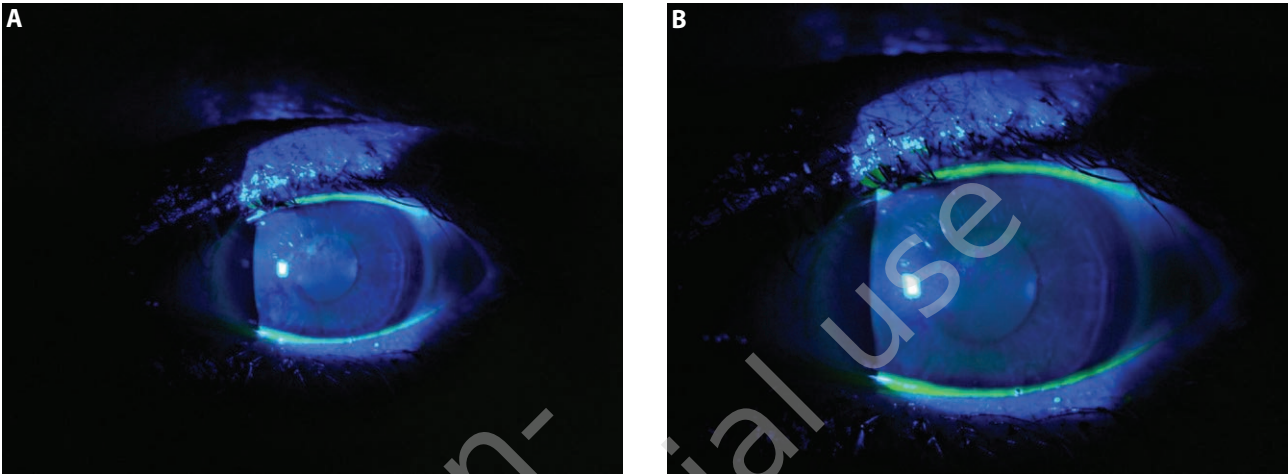
On examination, the visual acuity and intraocular pressure in the left eye of the patient were 1/50 without correction and 17 mmHg after the aforementioned treatment, while the results for the other eye were 5/5 (BCVA, best-corrected visual acuity) and 18 mmHg, respectively.

Physical examination revealed corneal punctate epithelial erosions (PEE) that stained positively with fluorescein in the left eye. Corneal graft in the right eye was transparent without fluorescein staining. The results of fundoscopic examination of both eyes were normal.

The tear film break-up time (TBUT) test was performed. The break-up time recorded of only 5 seconds was recorded for the left eye of the patient, while in the other eye the time of 14 seconds was recorded (fig. 1)

FIGURE 1

The results of the tear film break-up time test. A. The break-up time for the left eye of the patient was 5 seconds. B. The break-up time for the right eye of the patient was 14 seconds.



Based on these results, the patient was ultimately diagnosed with dry eye disease of the left eye caused by gas permeable contact lens usage.

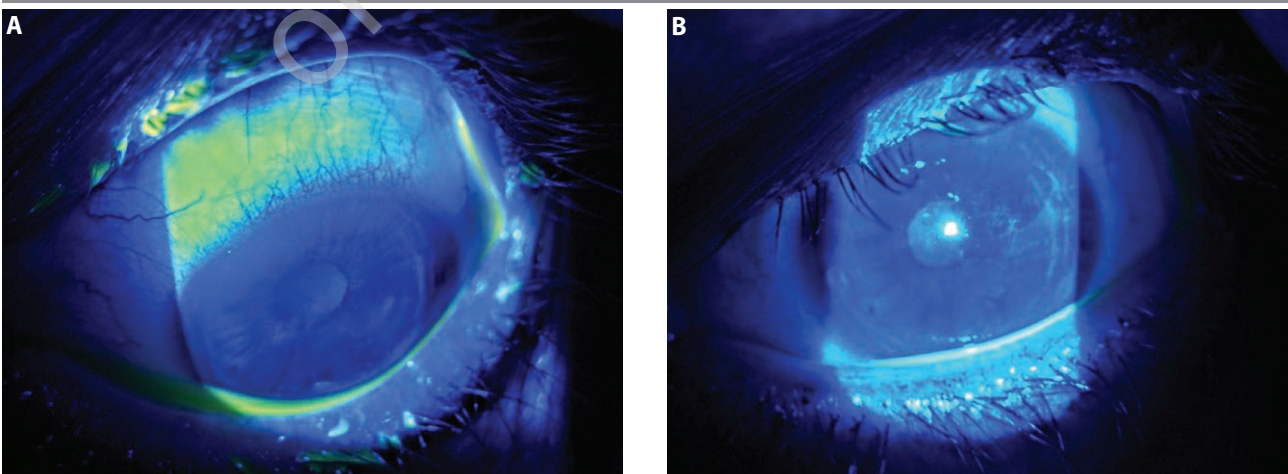
Appropriate treatment was introduced with steroidal eye drops (hydrocortisone, one drop four times a day), artificial tears (one drop every hour) and gel eye drops (one drop seven times a day). The patient was restricted from wearing gas permeable contact lenses.

The first inspection visit after 7 days revealed good response to the treatment and a reduction of symptoms

(fig. 2). Nevertheless, foreign-object sensation in the left eye lid of the patient and a subtle stinging sensation remained. On physical examination, punctate corneal epithelial damage were less severe in comparison to the last visit. TBUT of 8 seconds was recorded. The recommendation for the patient of not using the gas permeable contact lens was maintained. Dosage of hydrocortisone drops was lowered to three times a day and of gel eye drops to six times a day. The dosage of artificial tears was kept unchanged at one drop every hour.

FIGURE 2

The results of the tear film break-up time test. A. The break-up time for the left eye of the patient was 5 seconds. B. The break-up time for the right eye of the patient was 14 seconds.

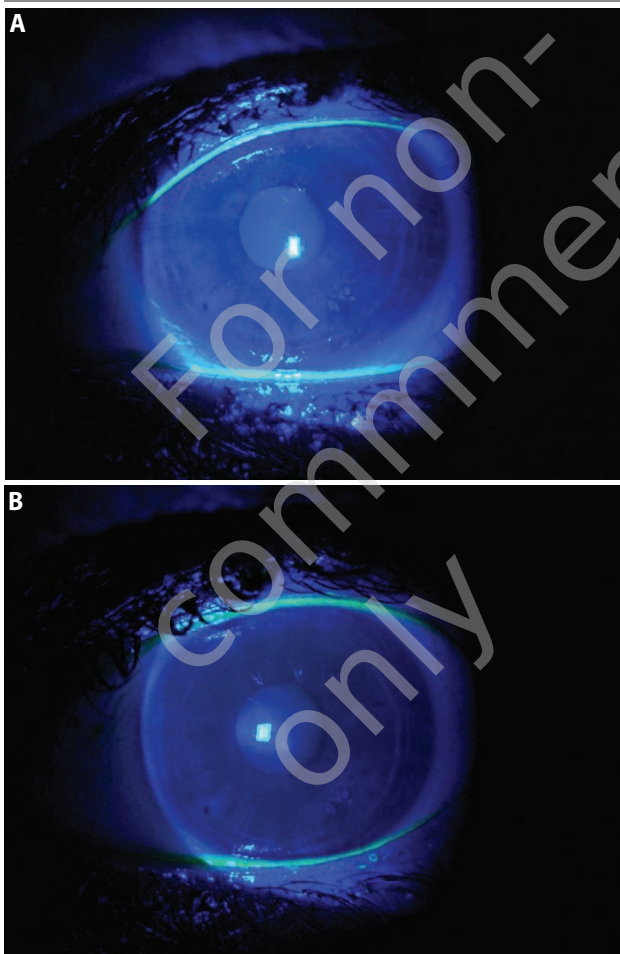




After next 10 days, the condition of the left eye improved significantly and the local symptoms resolved. Corneal epithelium stained negatively with fluorescein and TBUT increased to 11 seconds (fig. 3). Despite this, the recommendation for the patient of not using the gas permeable contact lens was maintained. Dosage of hydrocortisone drops was lowered to 1 drop a day and eye gel to 4 times a day. Artificial tears dosage was kept unchanged at one drop every hour.

FIGURE 3

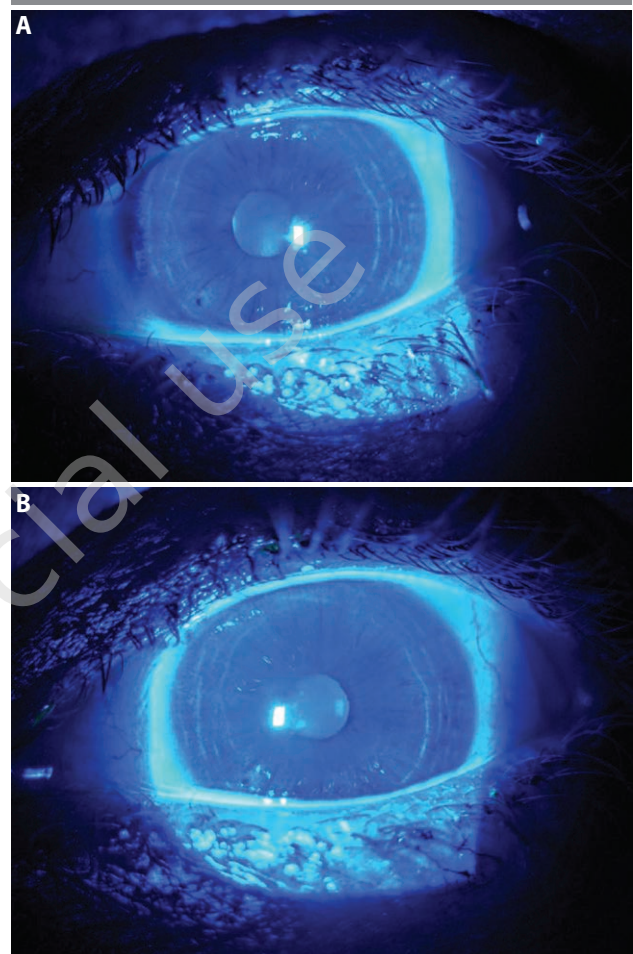
Next 10 days follow up appointment. Considerable improvement of the condition of the left eye. TBUT increased to 11 seconds.



Eventually, after 3 weeks, the implemented treatment resulted in complete recovery (fig. 4). The recommendation of not using the gas permeable contact lens was lifted. To maintain the recovery, the patient was recommended to keep applying artificial tears (one drop 7 times daily) and gel drops (one drop two times daily), as well as apply weak topical corticosteroid with dosage of one drop 2 or 3 times a week.

FIGURE 4

3 weeks follow up appointment. Complete recovery.



## DISCUSSION

Dry eye disease is a condition that causes a severe discomfort within surface of the eye. As a result, DED decreases the patient's quality of life and affects well-being, emotional state and acuity of sight. We can also detect slight astigmatism among those patients [1].

DED has many causes. Some of them revealed themselves in the described patient: age over 40 (here: 48) and low blinking frequency (here: caused by working at a computer). As per [1, 3], the age of over 40 is also a risk factor for instability of the tear film.

Usage of contact lenses seems to be one of the most frequent reason of DED due to mechanical irritation and disintegration of tear film regular density [4–6]. This hypothesis is not clearly determined and is still under intense research. According to some publications, wearing gas permeable contact lenses can even be beneficial to the DED treatment due to restraining tear evaporation and creating a protective barrier within cornea and irregular surface of eyelid conjunctiva [7]. Moreover, in medical literature there are also described specific, diagnostic contact lenses that

are used for precise measurements of tear secretion and ion content in tear film [8] and may in future replace Schirmer's test because of their superior sensitivity.

Due to DED's multi-factor etiology, it is important to diagnose each patient individually and select their treatment in regard to their individual medical history and examination results. It is essential to determine factors that influence DED etiopathogenesis [1]. The patient described in the paper had been diagnosed with keratoconus. It has been proven that keratoconus also increases discomfort, irritation and deterioration of vision itself due to progressing stage of primal disease.

Keratoconus patients have a strong predisposition to develop DED symptoms, especially when using contact lenses [4]. This disorder is described as the most frequent non-inflammatory corneal ectasia. Wearing contact lenses is associated with increased risk of inflammatory state, as they disrupt normal tear physiology through thinning and break-up of the tear film, interruption of tear film, and reformation and rupturing of the lipid layer with consequent increases in tear film evaporation. Because of expression and production of IL-1 $\beta$ , TNF- $\alpha$  and MMP-9, proinflammatory effects appear [4, 9].

Thus, as weak topical corticosteroides efficiently reduce inflammation in the front surface of the eye [10, 2, 11], they are highly effective for treatment of DED associated with keratoconus. The patient described in the paper suffered from bilateral keratoconus. The right eye had underwent a keratoplasty, while the left eye was treated with gas permeable contact lens. It should be noted that the right eye was free from DED symptoms, while the left eye, constantly irritated by contact lens, was found to have shortened TBUT and an apparent defect of corneal epithelium manifesting itself with fluorescein retention.

## CONCLUSION

Prolonged wearing of gas permeable contact lenses increases the risk of disorders of the eye surface and is associated with the risk of local corneal complications in the long term.

The goal of the therapy is intensive protection of the eye surface, both in terms of the tear film surface stabilization and anti-inflammatory effect.

Steroid therapy in the early stages of treatment is crucial in suppressing inflammation. Artificial tears and moisturizing gel drops are also essential. It should also be considered that patients with keratoconus are predisposed to the occurrence of DED when wearing gas permeable contact lenses more frequent than those without corneal ectasia.

As soon as an inflammatory reaction caused by wearing contact lenses appears, it is recommended to stop using the contact lenses and to implement an anti-inflammatory therapy. Only when the symptoms of irritation disappear, the patient can continue wearing the lenses. Nevertheless, the anti-inflammatory treatment should be maintained in minimal dosage e.g. at least one drop of weak corticosteroid twice a week.

Topical corticosteroids have a clearly beneficial effect both on the subjective and objective clinical parameters of moderate-to-severe dry eye patients. These effects can be associated with the reduction of inflammation markers of conjunctival epithelial cells.

Symptoms of DED disproportionately seriously affect the comfort of patient's everyday life, and often disallow normal functioning at home and work. For this reason, it is extremely important to correctly diagnose the syndrome and treat it in a way that prioritizes the elimination of cause of symptoms, contact lens in this case. It is also important to educate the patient to use moisturizing drops as often as possible and, if necessary, report for ophthalmological control. It should also be remembered that the treatment of dry eye syndrome is long-term and requires perseverance on the part of both the patient and the doctor.

*Figures: from the author's own materials.*

## CORRESPONDENCE

**Karolina Stanienda-Sokół, MD**

Medical University of Silesia in Katowice  
40-760 Katowice, ul. Panewnicka 65  
faks: +48 32 605 35 93  
e-mail: karolina.sta@gmail.com

## ORCID

Karolina Stanienda-Sokół – ID – <http://orcid.org/0000-0002-3710-6955>  
Marzena Wysocka – ID – <http://orcid.org/0000-0002-0540-9599>  
Jakub Słoka – ID – <http://orcid.org/0000-0003-1225-6102>  
Olga Łach-Wojnarowicz – ID – <http://orcid.org/0000-0003-1323-8440>  
Dariusz Dobrowolski – ID – <http://orcid.org/0000-0002-8768-1691>  
Edward Wylęgała – ID – <http://orcid.org/0000-0002-6707-5790>

## References

1. Barabino S, Labetoulle M, Rolando M et al. Understanding Symptoms and Quality of Life in Patients With Dry Eye Syndrome. *Ocul Surf.* 2016; 14(3): 365-75.
2. Horwath-Winter J, Berghold A, Schmuy O et al. Evaluation of the Clinical Course of Dry Eye Syndrome. *Arch Ophthalmol.* 2003; 121: 1364-8.
3. Uchino M, Kawashima M, Uchino Y et al. Association between tear film break up time and blink interval in visual display terminal users. *Int J Ophthalmol.* 2018; 11(10): 1691-7.
4. McMonnies CW. Inflammation and Keratoconus. *Optom Vis Sci.* 2015; 92(2): e35-41.
5. Molina K, Graham AD, Yeh T et al. Not All Dry Eye in Contact Lens Wear Is Contact Lens-Induced. *Eye Contact Lens.* 2020; 46: 214-22.
6. Wang MTM, Craig JP. Natural history of dry eye disease: Perspectives from inter-ethnic comparison studies. *Ocul Surf.* 2019; 17(3): 424-33.
7. Carracedo G, Blanco MS, Martin-Gil A et al. Short-term Effect of Scleral Lens on the Dry Eye Biomarkers in Keratoconus. *Optom Vis Sci.* 2016; 93(2): 150-7.
8. Badugu R, Jeng BH, Reece EA et al. Contact Lens to Measure Individual Ion Concentrations in Tears and Applications to Dry Eye Disease. *Anal Biochem.* 2018; 542: 84-94.
9. Lidich N, Garti-Levt S, Aserin A et al. Potentiality of microemulsion systems in treatment of ophthalmic disorders: Keratoconus and dry eye syndrome – In vivo study. *Colloids and Surfaces B: Biointerfaces.* 2019; 173: 226-32.
10. Avunduk AM, Avunduk MC, Varnell ED et al. The Comparison of Efficacies of Topical Corticosteroids and Nonsteroidal Anti-inflammatory Drops on Dry Eye Patients: A Clinical and Immunocytochemical Study. *Am J Ophthalmol.* 2003; 136(4): 593-602.
11. Yamaguchi T. Inflammatory Response in Dry Eye. *Invest Ophthalmol Vis Sci.* 2018; 59(14): DES192-9.

### Authors' contributions:

Karolina Stanienda-Sokół: conceptualization, data curation, formal analysis, investigation, methodology, project administration, resources, roles/writing – original draft; Marzena Wysocka-Kosmulska: conceptualization, data curation; Jakub Słoka: conceptualization, data curation; Olga Łach-Wojnarowicz: conceptualization, data curation; Dariusz Dobrowolski: supervision, validation, visualization, funding acquisition, writing – review and editing; Edward Wylęgała: supervision, validation, visualization, funding acquisition, writing – review and editing.

### Conflict of interest:

None.

### Financial support:

None.

### Ethics:

The content presented in the article complies with the principles of the Helsinki Declaration, EU directives and harmonized requirements for biomedical journals.