

# An unusual presentation of corneal intraepithelial neoplasia

**Paula Marticorena Álvarez, Guadalupe Garrido Ceca,  
Diego Asensio Celdrán Vivancos**

Department of Ophthalmology, Hospital Universitario La Princesa, Madrid, Spain  
Head of the Clinic: prof. Juan Jacobo González-Guijarro, MD, PhD



## HIGHLIGHTS

There are intraepithelial neoplasms with exclusive corneal involvement presented as a raised, well-demarcated grey plaque.

## ABSTRACT

**Introduction:** Conjunctival/corneal intraepithelial neoplasms are premalignant lesions usually showing conjunctival or limbal involvement. We report the rare case of an isolated corneal intraepithelial lesion.

**Clinical case:** An 80-year-old woman with an elevated, avascular, well-demarcated grey corneal plaque. After epitheliectomy and alcohol, the excised lesion was identified as a high-grade epithelial neoplasia. Treatment was topical interferon  $\alpha$ -2b for 1 month without recurrences.

**Conclusions:** A well-defined greyish corneal opacity should always raise suspicion of an intraepithelial neoplasia. In the present case, epitheliectomy and topical recombinant interferon proved successful.

**Key words:** cornea, intraepithelial, neoplasia, epitheliectomy, interferon

## INTRODUCTION

Corneal or conjunctival intraepithelial neoplasia (CIN) is a slowly progressing preinvasive lesion containing atypical epithelial cells that does not affect the full thickness of the epithelium nor extend beyond the basement membrane [1]. The most common form of presentation is a lesion in the limbus that extends towards the cornea. Here we describe an unusual case of isolated corneal presentation of CIN.

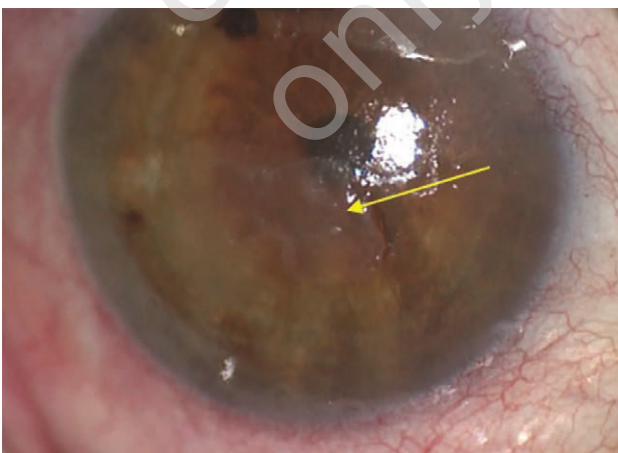
## CLINICAL CASE

An 80-year-old woman was referred to our department because of foreign body sensation and corneal opacity in the left eye. Her ophthalmologic history included cataract surgery and inactive diabetic retinopathy treated by pan-retinal photocoagulation in both eyes along with significant macular atrophy in the left eye.

Visual acuity was 20/32 in the right eye and counting fingers at 50 cm in the left. On biomicroscopy of the left eye, an anterior corneal opacity with microbullae located in the paracentral inferior region was detected along with signs of Meibomian gland dysfunction in both eyes. Following treatment with eyelid wipes and artificial tears, symptoms partly improved. After 1.5 years of follow up, a change in the lesion was noted, which now appeared as a raised, well-defined grey plaque with no signs of vascular invasion or fluorescein staining (fig. 1).

FIGURE 1

Left eye with a paracentral inferior anterior corneal opacity (yellow arrow). The lesion is a raised, well-defined grey plaque with no signs of vascular invasion.



At the time, anterior segment optical coherence tomography (AS-OCT) was unavailable at our centre. The decision was made to surgically excise the lesion for diagnostic and therapeutic purposes. Epitheliectomy was conducted through the “no-touch” method and the residual defect treated with

absolute alcohol before covering with amniotic membrane. In the pathological report, the excised lesion was described as a high-grade CIN (fig. 2). Treatment was started with interferon  $\alpha$ -2b (1 million IU/ml) 4 times daily for 1 month which was well tolerated. Over 3 years of follow up, the patient showed no visible or tomographic signs of residual disease or recurrence (fig. 3).

FIGURE 2

Image showing a slightly thickened epithelium which is disorganized and lacks normal maturation. Dysplasia may be seen in all its layers and its surface layer shows hyperkeratosis. The lesion visible is an intraepithelial neoplasia. Note the basement membrane is intact.

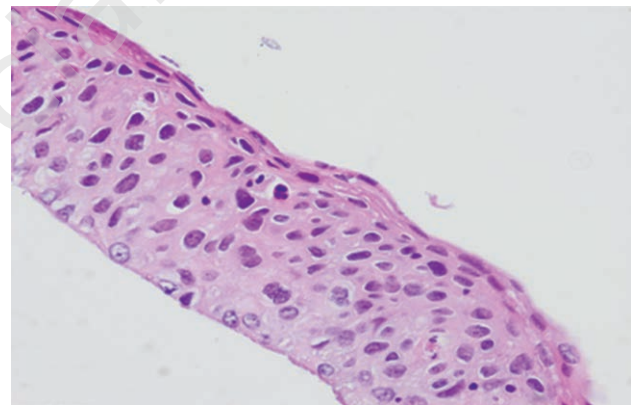
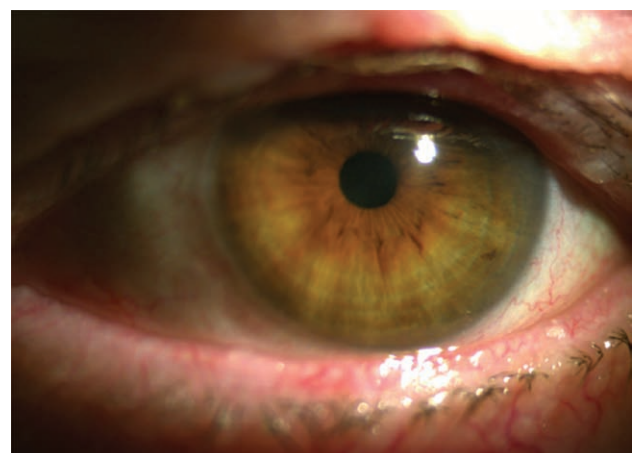


FIGURE 3

Patient's left eye without signs of residual disease or recurrence after 3 years.



## DISCUSSION

Isolated corneal CIN should be suspected in cases of a greyish corneal opacity with well-demarcated margins that is generally avascular. Sometimes the appearance may be gelatinous. Symptoms are irritation and vision loss

[1, 2]. Lesions are slowly progressive and show a low malignant potential (3%) [3].

AS-OCT and confocal microscopy are useful for the diagnosis and follow up of CIN. Upon AS-OCT, the epithelium appears thickened and hyperreflective with a sharp transition between the abnormal and healthy epithelium. Some have described a clear hyporeflexive plane of separation contrasting with the basement membrane, which is usually hyperreflective [4]. Confocal microscopy detects dysplastic cells. Both exams correlate highly with histological findings which remains the gold standard for a diagnosis of CIN [5]. Treatment options range from simple observation to epithelial keratectomy, chemotherapy, immunotherapy or lamellar keratoplasty [1].

When removing the epithelium, care should be taken to leave the basement membrane intact to avoid vertical seeding of the tumour [1]. Recurrence rates reported for simple excision of conjunctival and corneal forms are 17–24%, so associated chemotherapy (5-fluorouracil, mitomycin C) or immunotherapy (IFN $\alpha$ -2b) is recommended [6]. The mean lesion recurrence interval is 24 months [1]. However, re-

ports exist of non-recurring cases treated with epithelial keratectomy alone, though with a short follow up.

## CONCLUSIONS

In summary, we describe a rare case of CIN without limbal involvement. The lesion was successfully treated with epitheliectomy, alcohol application and interferon  $\alpha$ -2b in the early postoperative course. We should bear in mind that corneal intraepithelial neoplasia may present as an isolated lesion without conjunctival or limbal involvement and should always be suspected if there is a greyish corneal opacity with well-defined margins.

*Acknowledgments: we thank the Pathological Anatomy Department of our hospital for the iconography.*

*Figures: from the author's own materials.*

## CORRESPONDENCE

Paula Marticorena Álvarez  
Department of Ophthalmology, Hospital Universitario  
La Princesa, Madrid, Spain  
Calle de Diego de León, 62  
28006 Madrid, Spain  
e-mail: paula.marticorena@salud.madrid.org

## ORCID

Paula Marticorena Álvarez – ID – <http://orcid.org/0000-0003-4817-7350>  
Guadalupe Garrido Ceca – ID – <http://orcid.org/0000-0002-3917-2446>  
Diego Asensio Celdrán Vivancos – ID – <http://orcid.org/0000-0001-5018-0968>

## References

1. Horatanaruang O, Chansanti O, Mitarnun W et al. Isolated corneal intraepithelial neoplasia. *J Med Assoc Thai.* 2005; 88(suppl 9): S134-7.
2. Waring GO, Roth AM, Ekins MB. Clinical and pathologic description of 17 cases of corneal intraepithelial neoplasia. *Am J Ophthalmol.* 1984; 97(5): 547-59.
3. Erie JC, Campbell RJ, Liesegang TJ. Conjunctival and corneal intraepithelial and invasive neoplasia. *Ophthalmology.* 1986; 93: 176-83.
4. Singh S, Mittal R, Ghosh A et al. High-Resolution Anterior Segment Optical Coherence Tomography in Intraepithelial Versus Invasive Ocular Surface Squamous Neoplasia. *Cornea.* 2018; 37(10): 1292-8.
5. Chin EK, Cortés DE, Lam A et al. Anterior segment OCT and confocal microscopy findings in atypical corneal intraepithelial neoplasia. *Cornea.* 2013; 32(6): 875-9.
6. Shields CL, Kaliki S, Kim HJ et al. Interferon for Ocular Surface Squamous Neoplasia in 81 Cases: Outcomes Based on the American Joint Committee on Cancer Classification. *Cornea.* 2013; 32(3): 248-56.

## Authors' contributions:

Paula Marticorena Álvarez: 70%; Guadalupe Garrido Ceca: 15%; Diego Asensio Celdrán Vivancos: 15%.

## Conflict of interest:

None.

## Financial support:

None.

## Ethics:

The authors had full access to the data and take full responsibility for its integrity.

All authors have read and agreed with the content of the manuscript as written.

The paper complies with the Helsinki Declaration, EU Directives and harmonized requirements for biomedical journals.