

# Flaremetric evaluation of blood-aqueous barrier breakdown in diabetic patients after phacoemulsification and intraocular lenses with or without heparin-coated surface implantation

**Anna Górnik, Piotr Jurowski**

Department of Ophthalmology and Visual Rehabilitation, Medical University of Lodz, Poland  
Head: Prof. Piotr Jurowski, MD, PhD



## HIGHLIGHTS

Heparin surface modification of artificial IOL seems to be a reasonable method of stabilizing intraocular barrier considerably fastening postoperative rehabilitation of patients.

## ABSTRACT

**Background:** This study compared the intensity of blood-aqueous barrier breakdown in diabetic patients after phacoemulsification with heparin surface-modified and non-modified intraocular lens (IOL) implantation.

**Material and methods:** In this prospective trial, 68 diabetic patients were enrolled and divided into two groups: 33 patients with heparin surface-modified IOL implants (group 1) and 35 patients with standard hydrophobic IOL implants (group 2). Blood-aqueous barrier breakdown was assessed using a Laser Flare Meter 1 day, 7 days, 14 days, 1 month, and 3 months postoperatively.

**Results:** On postoperative days 1 and 7, the mean flare value was significantly higher in group 2 compared with group 1. On day 14, the mean flare value in both groups was similar and then higher in group 2.

**Conclusions:** The implantation of foldable heparin-coated IOLs led to a lower intensity and faster recovery of blood-aqueous barrier breakdown postoperatively.

**Key words:** blood-aqueous barrier, flare, heparin surface modified IOL

## INTRODUCTION

One of the most important steps of cataract surgery is the replacement of crystalline lens with the best refractive fitted and biocompatible artificial IOL. Choosing the adequate materials as well as modification of its surface makes IOL safer and much more biocompatible leading to lower inflammatory response after surgery. It is especially advisable in patients with high risk of inflammatory reaction i.e. in patients with diabetes and uveitis. In this context covering the IOL surface by heparin can lead to sufficient prevention of bacteria, protein and lens epithelial cells attachment into its surface, which in consequence minimizes the BAB breakdown [1–4]. This phenomenon is featured by influx of serum proteins and inflammatory cells into the aqueous humour of anterior and posterior chamber as a consequence of BAB breakdown. In the aqueous of anterior chamber these elements can be detected quantitatively using laser flare photometry [5].

The aim of the study was to assess the flare photometric measures in patients who underwent phacoemulsification with implantation of heparin surface modified (HSM) hydrophobic acrylic intraocular lens and to compare those measurements with the ones achieved after standard hydrophobic IOLs (AcrySof® IQ) implantation.

## MATERIAL AND METHODS

The study was conducted at the Department of Ophthalmology and Visual Rehabilitation, Medical University of Lodz. The approval of a relevant Bioethics Committee was obtained (number RNN/414/14/KB). This study was designed as a prospective trial to assess degree of damage and the time of BAB stabilization in patients who underwent phacoemulsification and implantation of heparin surface modified (HSM) IOL and standard hydrophobic IOLs (AcrySof® IQ) implantation. The range of preoperative examination included best-corrected visual acuity (BCVA), slit lamp of anterior segment and fundus examination. The international classification of clinical symptoms was used for grading the stage of diabetic retinopathy. The non-proliferative retinopathy was exclusively included in the study. Goldmann applanation tonometry was used to measure the IOP. Laser Flare Meter (LFM) FM-600, Kowa Co. Ltd. (Tokyo, Japan) was performed to quantify anterior chamber protein (flare). In brief, the device uses a diode laser beam to scan a measurement window that is projected inside the anterior chamber of the eye.

Measurements were obtained after pupil dilation with tropicamide eye drop 1% in a dark room condition. The values of laser flare were expressed in photons per milliseconds (ph/ms). All surgeries were performed under topical anaesthesia using standard phaco chop or divide-and-conquer technique. Either the HSM IOL or AcrySof® IQ were

implanted into the capsular bag. In both groups, the post-surgical medication consisted of: corticosteroid drug four times a day with dose tapering for up to 4 weeks, topical nonsteroidal anti-inflammatory drugs given four times a day for up to 4 weeks, and the fluoroquinolone antibiotic drug four times a day for 1 week. The follow-up examinations were performed 1, 7, 30 and 90 days postoperatively.

## RESULTS

Sixty-eight eyes of 68 patients, including 41 women and 27 men, were enrolled in the study. The mean age was 74 years (range 55–91). In 33 patients heparin surface IOLs (HSM IOLs – Polytech PolyLens, Roßdorf, Germany) were implanted (group 1). In 35 patients standard hydrophobic IOLs (Alcon IQ AcrySof®) were implanted (group 2). There was no significant difference between groups ( $p > 0.05$ ) in age, gender, duration of diabetes, type of diabetes treatment, preoperative intraocular pressure (IOP) and preoperative BCVA. Patient data at baseline are summarized in table 1.

TABLE 1

Patient data at baseline.		
Characteristic	Group 1	Group 2
Number of the eyes	33 (48.53%)	35 (51.47%)
Age	55–86 73.84 Mean	64–91 74.22 Mean
Gender		
Female	22 (66.67%)	19 (54.29%)
Male	11 (33.33%)	16 (45.71%)
Type of the IOL	Heparin Surface Modified Hydrophobic IOL	Hydrophobic IOL
Mean IOP preop	15.3 mmHg	16.34 mmHg

There was no significant difference of flare value between groups preoperatively ( $p = 0.246$ ) (tab. 2). In postoperative day 1<sup>st</sup> and 7<sup>th</sup> mean flare value was significantly higher in group 2 as compared to group 1. Fourteen days postoperatively, there was no significant difference ( $p = 0.921$ ) in flare measures between groups. The mean flare value measured at 1 and 3 months after surgery was again lower in group 1 as compared with group 2 (fig. 1).

TABLE 2

Mean flare in both groups at specific postoperative time points.

Time	Group 1 Mean flare (photon units/ms ± SD)	Group 2 Mean flare (photon units ± SD)	p
Baseline	10.19 ± 6.21	11.97 ± 6.54	p = 0.246
Day 1 <sup>st</sup>	21.74 ± 13.63	34.31 ± 30.31	p = 0.027
Day 7 <sup>th</sup>	13.7 ± 8.40	24.16 ± 19.02	p = 0.019
Day 14 <sup>th</sup>	11.97 ± 8.73	12.15 ± 8.24	p = 0.921
Month 1 <sup>st</sup>	10.22 ± 5.61	16.86 ± 10.95	p = 0.034
Month 3 <sup>rd</sup>	10.28 ± 5.56	15.32 ± 7.81	p = 0.003

There was no statistically significant difference in BCVA preoperatively between the two analysed groups (p = 0.317) (fig. 2). Patients in both groups achieved statistically significant visual improvement in every single day of measure in the follow-up. However, there was no statistically significant difference in BCVA between group 1 and group 2 over the 3 months of follow-up.

FIGURE 1

Means flare values over the 3-month follow-up.

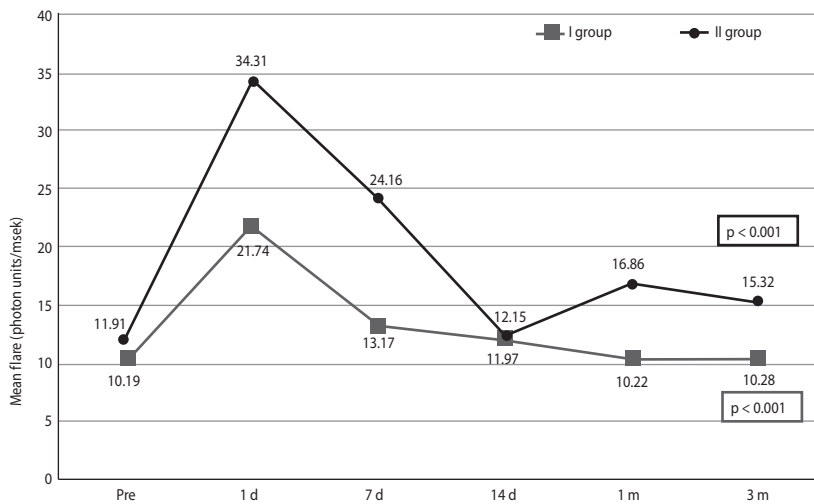
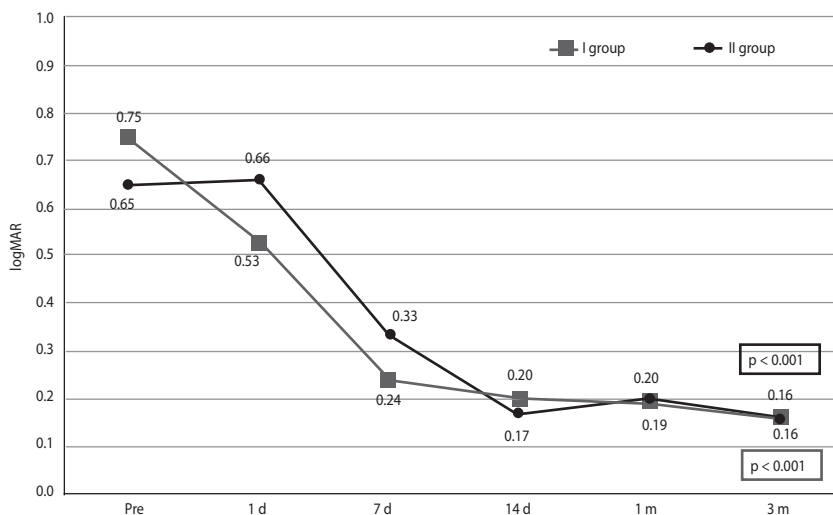


FIGURE 2

Best corrected visual acuity (logMAR).



## DISCUSSION

Blood-aqueous barrier belongs to the physiological barriers within the human eye. It is located at the non-pigmented epithelium of the ciliary body as well as in the endothelium of the iris blood vessels. Due to the fact that BAB is physiologically leaky there is a small amount of plasma proteins identified in aqueous humour of the eye. However, there is no agreement how the blood-aqueous barrier (BAB) is susceptible to some factors. Cataract surgery can induce dysregulation of the BAB function resulting in huge leakage of serum protein and blood cells into the aqueous humour. This protein in anterior chamber may be objectively quantified using Laser Flare Meter in a safe, non-invasive and efficient manner [6].

It is well-documented that postoperative BAB breakdown is connected up to many factors along with cataract surgical technique [7, 8], including the duration of surgery as well as the type of implanted IOL [9]. The reason for the observed phenomenon is not clearly known. It is also suggested that cataract surgery and the implantation of IOL may cause some changes in the nitric oxide (NO) level [10–12]. As a consequence, NO production may contribute to pathological developments in the anterior chamber such as vessel dilation, changes in perfusion, increased vessel permeability, and BAB breakdown. In patients with diabetes, the microcirculation per se is impaired and intraocular surgery can aggravate this impairment [13]. It is also suggested that the IOL material may be an important factor of BAB destabilisation.

Technology of IOL surface modification comprised ion beam, plasma, layer-by-layer self-assembly, ultraviolet radiation, and ozone. In those techniques such molecules as: poly(ethylene glycol), polyhedral oligomeric silsesquioxane, 2-methacryloyloxyethyl phosphorylcholine, TiO<sub>2</sub>, heparin, F-heparin, titanium, titanium nitride, vinyl pyrrolidone, and inhibitors of cytokines are introduced into IOLs surface [3]. It is advocated that coating the surface with heparin has a potential of reducing BAB breakdown. Heparin is a well-known anticoagulant commonly used in medicine without any serious side effects. Studies have shown that heparin can suppress proliferation of lens epithelial cell and fibroblast and reduce adhesion as well as deposition of platelets, fibroblasts and macrophage on posterior capsular surface [14, 15]. Importantly, heparinization can attenuate the foreign body response and reduce in some extent breakdown of BAB. It is suggested that it is the effect of the

same charges on the IOL surface and bacteria cell wall [16]. Additionally, the IOL surface is relatively non-adherent to inflammatory active particles, which potentially reduces the postoperative inflammatory reaction [17].

The technology of heparin surface modification of IOL has a long history. This process was originally used in polymethyl methacrylate (PMMA) lenses in the early 1990s. The investigators of this modification showed advantages in diminishing the postoperative inflammatory reaction [18]. Based on several studies, heparin-coated PMMA IOLs have been recommended for use in cataract surgery as treatment of choice, especially for high-risk populations such as those with uveitis or diabetes [19]. Studies strongly suggested that initial increase in anterior chamber flare is mainly the result of the trauma caused during surgery, especially in diabetic patients [20]. Heparin surface modified (HSM) foldable IOL in contrast to PMMA IOL requires a significantly smaller self-sealing incision resulting in much lower surgical trauma.

Krall et al. compared the flare value in patients who underwent phacoemulsification with HSM implantation in one eye and hydrophobic acrylic IOL in the contralateral eye [21]. In the HSM group lower laser flare values in the early postoperative period was observed with a significantly faster decrease in cells level than in the group in which the uncoated IOL was used. According to these researchers anti-inflammatory effect of heparin can be confirmed [21]. In this study the laser flare measures were used to determine aqueous flare in the anterior chamber. Patients with HSM IOL in this study showed lower flare values in the early postoperative period. What was especially surprising, in patients with implanted uncoated IOL changes of flare value were more variable, in 14 days the mean flare value achieved again higher level in contrast to those having HSM IOL. The mean flare value at 3 months was still higher than at baseline by 27.98% in the uncoated IOL group in contrast to patients with HSM IOL for whom the flare value decreased to nearly baseline levels at this time. It is commonly reported that BAB stabilization occurs usually after 3 months. Taking this into account it can be shown that BAB stabilization is much faster in patients with HSM IOL.

## CONCLUSIONS

The modification of artificial IOL seems to be a reasonable method of stabilizing BAB and making postoperative rehabilitation much faster, especially in diabetic patients.

### CORRESPONDENCE

**Anna Górnik, MD**

Department of Ophthalmology and Visual Rehabilitation,  
Medical University of Lodz  
90-549 Łódź, Żeromskiego 113  
e-mail: gornik.ania@gmail.com

### ORCID

Anna Górnik – ID – <http://orcid.org/0000-0002-0113-3361>  
Piotr Jurowski – ID – <http://orcid.org/0000-0003-1471-8577>

## References

1. Apple DJ. Influence of intraocular lens material and design on postoperative intracapsular cellular reactivity. *Trans Am Ophth Soc.* 2000; 98: 257-83.
2. Langwińska-Wośko E, Rowiński M, Bełzecka-Majszyk A et al. Soczewki wewnątrzgałkowe tylnokomorowe – przegląd asortymentu ze szczególnym uwzględnieniem soczewek zwijalnych. *Okulistyka.* 2001; 3: 17-22.
3. Huang Q, Cheng GP, Chiu K et al. Surface Modification of Intraocular Lenses. *Chin Med J.* 2016; 129: 206-14.
4. Kang S, Kim M-J. Comparison of clinical results between heparin surface modified hydrophilic acrylic and hydrophobic acrylic intraocular lens. *Eur J Ophthalmol.* 2008; 18(3): 377-83.
5. Sawa M. Laser flare-cell photometer: principle and significance in clinical and basic ophthalmology. *Jpn J Ophthalmol.* 2017; 61(1): 21-42.
6. Ladas JG, Wheeler NC, Morhun PJ et al. Laser flare-cell photometry: methodology and clinical applications. *Surv Ophthalmol.* 2005; 50(1): 27-47.
7. Percival P. Use of heparin-modified lenses in high-risk case for uveitis. *Dev Ophthalmol.* 1991; 22: 80-3.
8. Sanders DR, Kraft M. Steroidal and nonsteroidal anti-inflammatory agents; effect on postsurgical inflammation and blood-aqueous humor barrier breakdown. *Arch Ophthalmol.* 1984; 102(10): 1453-6.
9. Philipson B, Fagerholm P, Calel B et al. Heparin surface modified intraocular lenses. Three-month follow-up a randomized, double-masked clinical trial. *J Cataract Refract Surg.* 1992; 71-8.
10. Jurowski P. Ocena czynników stabilizujących strukturę wewnątrzgałkowe przed urazem termicznym w czasie pracy fakoemulsyfikatora w badaniach doświadczalnych u królików. Rozprawa habilitacyjna. 1997.
11. Jurowski P. Rola tlenu azotu w regulacji biochemicznych procesów wewnątrzgałkowych. *Okulistyka.* 1998, 1: 38-40.
12. Jurowski P, Goś R, Piasecka G. Nitric oxide levels in aqueous humor after lens extraction and poly(methyl methacrylate) and foldable acrylic intraocular lens implantation in rabbit eyes. *J Cataract Refract Surg.* 2002; 28(12): 2188-92.
13. Tang J, Kern TS. Inflammation in diabetic retinopathy. *Prog Retin Eye Res.* 2011; 30(5): 343-58.
14. Del Vecchio PJ, Bizios R, Holleran LA et al. Inhibition of human scleral fibroblast proliferation with heparin. *Invest Ophthalmol Vis Sci.* 1988; 29: 1272-6.
15. Tognetto D, Ravalico G. Inflammatory cell adhesion and surface defects on heparin-surface-modified poly(methyl methacrylate) intraocular lenses in diabetic patients. *J Cataract Refract Surg.* 2001; 27(2): 239-44.
16. Liu T, Hu AH, Hu QJ et al. Objective assessment of the inflammatory reaction in foldable heparin surface-modified hydrophilic acrylic intraocular lens. *Int Eye Sci.* 2016; 16(1): 11-3.
17. Ravalico G, Tognetto D, Baccara F. Heparin surface modified intraocular lens implantation in eye with pseudoexfoliation syndrome. *J Cataract Refract Surg.* 1994; 20(5): 543-9.
18. Shah SM, Spalton DJ. Comparison of the postoperative inflammatory response in the normal eye with heparin Surface-modified and poly (methyl methacrylate) intraocular lenses. *J Cataract Refract Surg.* 1995; 21(5): 579-85.
19. Mester U, Strauss M, Grewing R. Biocompatibility and blood-aqueous barrier impairment in at-risk eyes with heparin-surface-modified or unmodified lenses. *J Cataract Refract Surg.* 1998; 24(3): 380-4.
20. Pande M, Shah SM, Spalton DJ. Correlations between aqueous flare and cells and lens surface cytology in eyes with poly(methyl methacrylate) and heparin-surface-modified intraocular lenses. *J Cataract Refract Surg.* 1995; 21(3): 326-30.
21. Krall EM, Arlt EM, Jell G et al. Intraindividual aqueous flare comparison after implantation of hydrophobic intraocular lenses with or without a heparin-coated surface. *J Cataract Refract Surg.* 2014; 40(8): 1363-70.

### Wkład autorów:

Anna Górnik: przygotowanie manuskryptu, ostateczna ocena manuskryptu;  
Piotr Jurowski: ostateczna ocena manuskryptu.

### Konflikt interesów:

Nie występuje.

### Finansowanie:

Nie występuje.

### Etyka:

Treści przedstawione w artykule są zgodne z zasadami Deklaracji Helsińskiej, dyrektywami EU oraz ujednoliconymi wymaganiami dla czasopism biomedycznych.

### Authors' contributions:

Anna Górnik: writing of manuscript, final review of manuscript;  
Piotr Jurowski: final review of manuscript.

### Conflict of interest:

None.

### Financial support:

None.

### Ethics:

The content presented in the article complies with the principles of the Helsinki Declaration, EU directives and harmonized requirements for biomedical journals.