

Case report

## Problems of anticoagulant therapy in elderly cancer patients with atrial fibrillation and hemorrhagic stroke

**Marina F. Ballyuzek<sup>1,2</sup>, Maria V. Mashkova<sup>1</sup>**

<sup>1</sup> St. Petersburg Clinical Hospital, Russian Academy of Sciences, Russia

<sup>2</sup> St. Petersburg State University, Medical Faculty, St. Petersburg, Russia

For non-commercial use only

### **Correspondence:**

Maria V. Mashkova  
190021, Russian Federation,  
St. Petersburg, Institutskii pr. 29, apt. 10  
tel.: +79 (21) 361 71 90  
e-mail: mashkovamaria@epage.ru

### **Received:**

20.11.2017.

### **Accepted:**

28.11.2017.

DOI: 10.24292/01.OR.281117  
Copyright © Medical Education.  
All rights reserved.

### **ABSTRACT**

The problems of antithrombotic and first of all, anticoagulant therapy in patients with concomitant oncological and cardiovascular pathology, especially in gerontological practice, remain to be unsolved. The need to use anticoagulants is dictated by a high risk of thromboembolism in cancer patients combined with age-associated atrial fibrillation. The risk of hemorrhage increases with the age; moreover, there is a risk of dangerous drug interactions due to the need of polymorbid pathology treatment. Thus, the clinical situation sometimes creates difficulties in choosing a proper tactic in patient management and following the existing treatment standards.

A clinical case of a patient of an elder age with the recurrence of lung cancer, which has an established high-risk of thromboembolism, and with paroxysmal form of atrial fibrillation and new oral anticoagulants treatment, is considered.

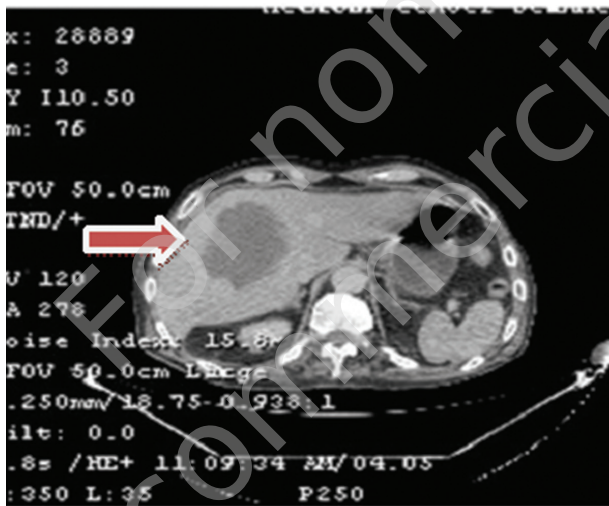
**Key words:** thromboembolism in cancer patients, geriatric patients, cardiooncology, antithrombotic and anticoagulant therapy

## INTRODUCTION

High risk of thromboembolic complications and also tendency to hemorrhage in cancer patients, based on the development of the tumor itself and the ongoing anti-cancer treatment, is well known. At the same time, the issues of antithrombotic and first of all anticoagulant therapy in these patients remain unsolved. However, if the risk of thromboembolism in cancer patients is combined with other risk factors, such as elderly age and age-associated atrial fibrillation (AF), more difficulties in clinical practice can occur.

FIGURE 1.

Chest CT (04/10/2016): a state after the lower right lobectomy. Post-tuberculosis changes in the lungs and in intrathoracic lymph nodes. CT signs of a cyst of the left hepatic lobe and a growth (67 × 76 × 37 mm) in S8 of the right hepatic lobe.



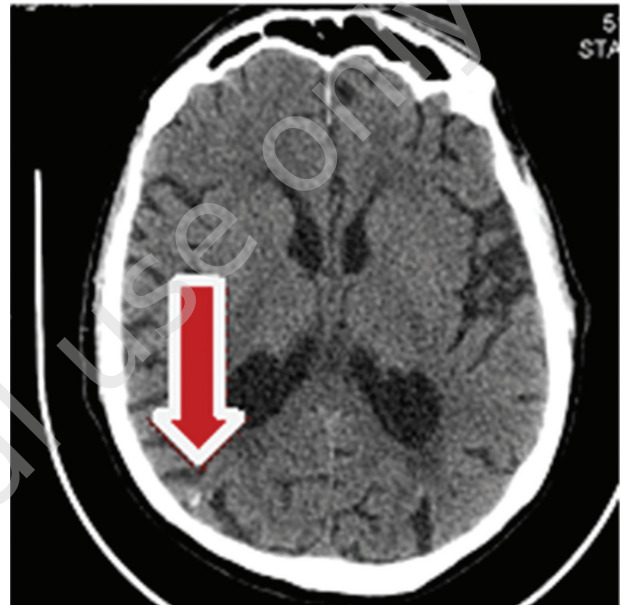## CLINICAL CASE

Man, aged 75 years old, with few paroxysms of atrial fibrillation in the last five years, constant oral anticoagulation therapy (rivaroxaban, 20 mg), CHA<sub>2</sub>DS<sub>2</sub>-VASc – 3, HAS-BLED – 2, GFR – 59,5, with adenocarcinoma of the lower right lobe, pT1bN0M0, stage IA diagnosed in April 2014. The lower lobectomy with pleural photodynamic therapy was conducted. From 2014 to 2016, the control computer tomography (CT) scans were made with no changes noticed.

On 3<sup>th</sup> of October 2016 the patient was hospitalized with dyspnea, subfebrile temperature and initial signs of cachexia syndrome as a part of paraneoplastic syndrome. The survey of the patients was conducted: weight – 70 kg, height – 1,85 m, BMI – 20,45 kg/m<sup>2</sup>, blood pressure sitting – 175/90 mmHg, HgB – 98 g/dl, platelets – 360 000/mm<sup>3</sup>.

FIGURE 2.

Head CT (24/10/2016): Hyperdense finding in cortical area of right parietal lobe (probably intracerebral hemorrhage). CT-signs of encephalopathy. Cerebral atherosclerosis. Hypoplasia of the right vertebral artery. Enlargement of brain cerebrospinal fluid spaces with predominance of communicating hydrocephalus.



The control CT was made showing a state after the lower right lobectomy, the right hepatic lobe growth (67 × 76 × 37 mm).

During the diagnostic laparoscopy 20<sup>th</sup> of October the tumor with diaphragm infiltration through right pleural cavity was visualized. The lung cancer recurrence was suspected. Adenocarcinoma was confirmed by histological analysis.

On 24<sup>th</sup> of October 2016 hemorrhagic stroke in the right hemisphere with left hemiparesis occurred.

Based on EHRO Practical Guide, 2015 recommendations anticoagulant therapy in patients with intracranial hemorrhages has to be cancelled for up to 4–8 weeks, therefore rivaroxaban treatment was cancelled and low molecular weight heparin wasn't assigned. The correction of hemodynamic parameters was made.

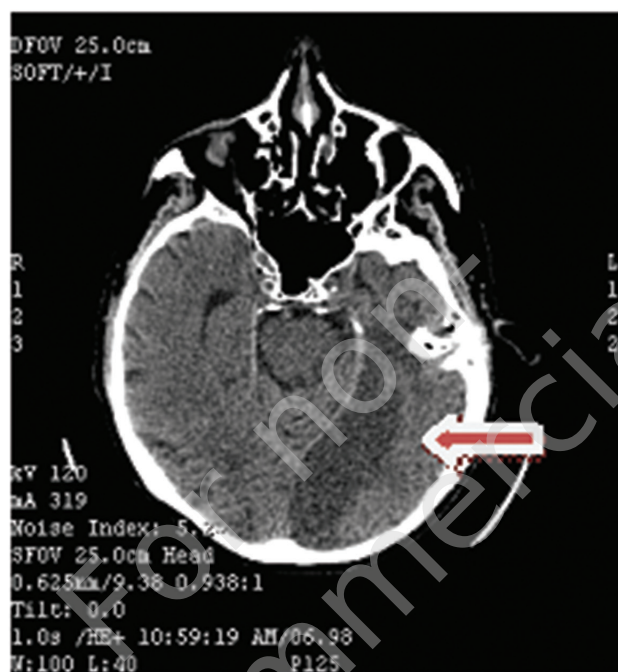
On 29<sup>th</sup> of October 2016 a paroxysm of atrial fibrillation and a severe ischemic stroke in left posterior cerebral artery with right hemiparesis occurred.

Vital functions support, including mechanical ventilation in an intensive care unit, was carried out. Six day after the low molecular weight heparin therapy was assigned.

The recurrent pulmonary embolism symptoms and increasing cancer intoxication culminated in death on the beginning of January 2017.

FIGURE 3.

Head CT (31/10/2016): Low-density area (ischemic stroke) in left parietal-occipital-temporal-posterior region. Hyperdense area in the right parietal lobe (intracerebral hemorrhage from 24/10/17). CT-signs of encephalopathy. Cerebral atherosclerosis.



## DISCUSSIONS

The elderly patient with a paroxysmal form of AF and constant new oral anticoagulant therapy in combination with a lung cancer recurrence had intracranial hemorrhage. Predisposition to thromboembolism in patients with lung cancer according to the

Khorana et al. scale 2016 [1] is defined as high, however, according to the latest recommendations of European Heart Rhythm Association Practical Guide 2015 [2], the oral anticoagulants has been canceled, which probably contributed significantly to the development of an extensive cardioembolic stroke leading to death. In such cases is it possible to choose another tactic, which would contradict the current recommendations? And who should make such decisions?

In this patient epicardial clipping of the left atrial appendage (LAA) or electrical isolation of the left atrial appendage with device occlusion for prevention of stroke could be considered, but given the small period of time between the hemorrhagic and ischemic strokes, the cancellation of anticoagulant therapy, these method couldn't be done. Moreover, despite the high risk of thromboembolism in patients with atrial fibrillation and oncological process, there are no straight recommendations about using left atrial appendage method in this category of patients, especially in such an acute phase. There is also a need to consider the high risk of bleeding in cancer patients, when one of the most important limitations in LAA ligation are the potential risks of atrial tears and related bleeding [3, 4].

## CONCLUSION

The study of comorbid cardiac and oncological patients' management issues, especially in gerontological practice, should be a priority research area in cardiooncology, and given the interdisciplinary nature of the problem, the proper algorithm of treatment should be developed individually and with the involvement of a cardiooncological team.

## References

1. Khorana AA et al. Guidance for the prevention and treatment of cancer-associated venous thromboembolism. *J Thromb Thrombolysis* 2016; 41: 81-91.
2. Heidbuchel Hein et al. Updated European Heart Rhythm Association Practical Guide on the use of non-vitamin K antagonist anticoagulants in patients with non-valvular atrial fibrillation. *Europace* 2015; 17: 1467-1507.
3. Leinonen JV, Emanuelov AK, Platt Y et al. Left atrial appendages from adult hearts contain a reservoir of diverse cardiac progenitor cells. *PLoS One* 2013; 8:e59228.
4. January CT, Wann LS, Alpert JS et al. 2014 AHA/ACC/HRS guideline for the management of patients with atrial fibrillation: executive summary: a report of the American College of Cardiology/American Heart Association Task Force on practice guidelines and the Heart Rhythm Society. *Circulation* 2014; 130: 2071-2104.

## Authors' contributions:

Marina F. Ballyuzek: 50%; Maria V. Mashkova: 50%.

## Conflict of interests:

None.

## Financial support:

None.

## Ethics:

The paper complies with the Helsinki Declaration, EU Directives and harmonized requirements for biomedical journals.