

Original article

## Retrospective assessment of everolimus treatment in patients suffering from advanced renal cell carcinoma

**Paweł Hernik, MD, Maksymilian Kruczała, MD, Marek Ziobro, MD, PhD**

*Clinic of Systemic and Metastatic Malignancies, Centre of Oncology, Maria Skłodowska-Curie Memorial Institute, Krakow Branch, Poland*

*Head of the Clinic: Marek Ziobro, MD, PhD*

### Correspondence:

Paweł Hernik, MD  
Clinic of Systemic and  
Metastatic Malignancies,  
Centre of Oncology,  
Maria Skłodowska-Curie  
Memorial Institute  
31-115 Kraków,  
ul. Garncarska 11  
e-mail: pawlus\_85@wp.pl

### Received:

8.02.2017

### Accepted:

26.03.2017

DOI: 10.24292/01.OR.300617.6

Copyright © Medical  
Education. All rights reserved.

### ABSTRACT

**Objective:** Results of second-line everolimus treatment in clear cell renal carcinoma.

**Material and methods:** Clinical data of 32 patients of the Clinic of Systemic and Metastatic Malignancies, Centre of Oncology, Maria Skłodowska-Curie Memorial Institute (Krakow Branch) treated with second-line everolimus between 2011 and 2016 were analysed.

**Results:** Median progression-free survival was 7 months. Stable disease was observed in 24 cases. Adverse events occurred in 59% of all patients, and the majority were mild and moderate (G1 and G2) according to CTCAE. The most frequent adverse events included anaemia, stomatitis, rash and fatigue.

**Conclusion:** Molecularly targeted drugs offer the only effective and available therapy in Poland, which can be administered in patients with advanced renal cell carcinoma. Second-line everolimus is a valuable therapeutic option in the above mentioned group (following progression on first-line TKI therapy), especially when it is necessary to avoid the accumulation of similar adverse events after TKI treatment (different toxicity profiles).

**Key words:** everolimus, renal cell carcinoma, targeted therapy

## INTRODUCTION

Kidney cancer constitutes up to 3% of all malignancies in adult patients, with 170,000 new cases registered each year, and over 72,000 related deaths [1]. In 2010 in Poland, over 2700 new cases of renal cancer were diagnosed in male patients (ca. 1500 deaths), and nearly 1900 new cases in female patients (ca. 1000 deaths). Most of the cases are diagnosed in patients above 55 years of age, with peak incidence observed in the eighth decade of life [2]. The most common histological type (nearly 90%) of kidney malignancies is renal cell carcinoma (RCC), with its most common subtype (80% of RCC) being clear cell carcinoma [3].

Surgery is the basic method of RCC treatment, including in particular:

- radical nephrectomy, performed as laparotomy or laparoscopy [4, 5]
- nephron sparing surgery (NSS), performed as open surgery, laparoscopy or robotic surgery [6, 7].

It should be noted here that the latter method is superior to others in terms of the reduced rate of complications [8]. If there are contraindications to perform the surgical procedure, ablation may be offered to the patients (RFA, radio frequency ablation; CA, cryoablation).

In the case of inoperable distant metastases, systemic treatment is the basic therapeutic method, which may involve:

- cytokines
- molecular targeted drugs
- (and recently) checkpoint inhibitors.

The efficacy of cytokines (interleukin 2, interferon  $\alpha$ ) is limited, with objective response reaching 6–15% [9–12]. Additionally, toxicity is a significant problem, in particular that associated with high doses of interleukin 2 [13].

A true breakthrough in systemic renal cancer treatment was brought about by the development of molecular targeted drugs:

- tyrosine kinase inhibitors (TKI) – sunitinib, pazopanib, sorafenib and axitinib
- mTOR (mammalian target of rapamycin) inhibitors – everolimus and temsirolimus
- bevacizumab.

Thanks to targeted therapy, expected median overall survival (mOS) has doubled, and it now amounts to 8 months (in the group of patients with poor prognosis) to ca. 40 months (in patients with favourable prognosis) [14, 15].

## OBJECTIVE

This paper presents the results of second-line everolimus treatment in patients suffering from clear cell renal carcinoma.

## MATERIAL AND METHODS

In the years 2011–2016, 32 patients treated at the Clinic of Systemic and Metastatic Malignancies (Centre of Oncology) in Krakow were qualified for second-line everolimus treatment, as they had progressed with clear cell renal carcinoma. Once diagnosed with the disease, all patients underwent nephrectomy:

- radical, in which case they were followed up on until the diagnosis of advanced disease, or
- palliative in the case of *de novo* diagnosis of advanced disease.

Following nephrectomy, all patients diagnosed with advanced disease had been qualified for first-line systemic treatment (sunitinib = 28; pazopanib = 3; interferon = 1). Once they progressed on first-line treatment, they were qualified for second-line everolimus therapy. To monitor treatment effects, computed tomography (CT) or magnetic resonance (MR) imaging tests of the area involved were performed every 12 weeks (with RECIST criteria used to assess treatment efficacy). Other tests included ECG and laboratory tests (CBC with differential, levels of creatinine, bilirubin, lactate dehydrogenase and alkaline phosphatase, and activity of alanine aminotransferase and aspartate aminotransferase). Adverse events were graded in accordance with the CTCAE v. 4.0 criteria (Common Terminology Criteria for Adverse Events).

Everolimus was dosed at 10 mg daily. When clinically significant adverse events were observed, treatment was discontinued until the events were resolved, and later resumed at a reduced dose. In the majority of the cases (30 patients), treatment was continued until disease progression. Efficacy of everolimus treatment and adverse events were analysed for the presented group of patients (tab. 1).

TABLE 1.  
Characteristics of the patients treated with everolimus.

Number of patients	32
Sex:	
• male	16
• female	16
History of cancer in first-degree or second-degree relatives:	
• positive	11
• negative	21
Age at diagnosis (years)	
• average	58
• range	39–77

Concomitant diseases*:	
• arterial hypertension	12
• bronchial asthma	1
• type 2 diabetes	2
• ischaemic heart disease	7
• none	15
Histological type:	
• RCC (clear cell renal carcinoma)	32 (including 4 with a sarcoma component and 1 with chromophobe cancer)
General condition upon treatment initiation:	
• WHO 0	4
• WHO 1	28
Prognosis category according to MSKCC:	
• favourable or intermediate	32
• poor	0
Location of metastases upon treatment initiation:	
• lungs	10
• lungs and other locations (lymph nodes, parenchymatous organs, bones, locoregional recurrence)	10
• other locations	12

MSKCC – Memorial Sloan Kettering Cancer Center Score.

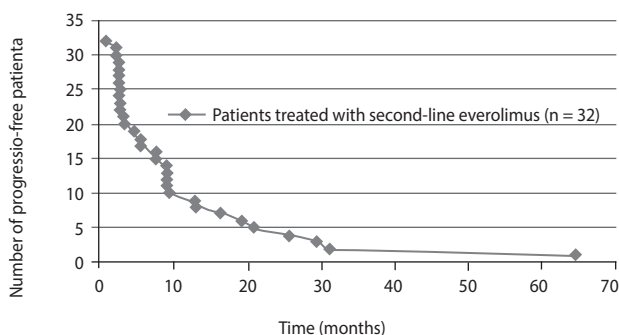
\* In some of the patients there was more than one concomitant disease.

## RESULTS

Median progression-free survival (PFS) was 7 months in the study group (1–64.3 months) (fig. 1). Stable disease (SD) was reported in 24 patients, and in the remaining 8 there was progression of the disease (PD) within the first 3 months of treatment. Partial or complete response was not observed.

FIGURE 1.

Number of progression-free patients depending on the time.



Adverse events were reported in 59% of the patients (i.e. in 19 of them). Most of them (63%) were grade 1 and grade 2 events, and they included:

- anaemia (5 cases)
- stomatitis (4)

- rash (4)
- fatigue (4)
- diarrhoea (2)
- hand–foot syndrome (2)
- individual cases of hypertransaminasemia, hyperbilirubinaemia, nausea and oedema.

Grade 3 events (26%) included:

- stomatitis
- anaemia
- rash.

In two cases treatment had to be discontinued due to life-threatening complications (exacerbation of renal failure and ventricular arrhythmia).

## DISCUSSION

Over the past two decades, some progress has been made in mRCC systemic treatment. Despite the relatively large number of efficacious drugs, and despite the hopes related to the outcomes of studies on checkpoint inhibitors, therapeutic options are still limited in Poland. Physicians dealing with systemic mRCC treatment are bound by the provisions of the therapeutic programme adopted by the Ministry of Health. The current clinical practice provides for many mRCC patients in our country to receive TKIs (sunitinib or pazopanib) as first-line drugs. According to the national drug reimbursement programme (January 2017) [16], second-line treatment available to those patients involves one of the two products: axitinib or everolimus. It should be noted that at the time when the patients described in the present article were qualified for treatment, everolimus was the only second-line treatment option.

The registration study of everolimus (RECORD-1, *REnal Cell cancer treatment with Oral RAD001 given Daily*) compared its efficacy to placebo combined with best supportive care in a group of 415 patients previously treated for mRCC. The study subjects were randomized to the everolimus arm (n = 277) or to the placebo arm (n = 139). Median age of the patients was 61 (range: 27–85, 78% male, 88% Caucasian), and the number of earlier VEGFR-TKI treatments was 1 (74%) or 2 (26%). The primary endpoint of the study was PFS, assessed in a general and independent blinded review in accordance with the RECIST criteria. Median PFS was 4.9 months in the everolimus arm (95% CI: 4.0–5.5 months), and 1.9 months in the placebo arm (95% CI: 1.8–1.9 months). The difference in favour of everolimus (HR = 0.33; 95% CI: 0.25–0.43; p < 0.001) was statistically significant [17].

This paper describes a group of patients treated at the Centre of Oncology in Krakow, in whose case progression-free survival was longer than the one reported in the registration study (median PFS: 7 months), but one should bear in mind the considerable difference in the group sizes (227 patients involved in the RECORD-1 study). Direct comparison of the outcomes of the registration study with the retrospective assessment of our patients, treated in a regular clinical setting is certainly not possible, but the results obtained deliver further evidence for the efficacy and safety of the treatment.

Recently, nivolumab (human monoclonal anti-PD1 antibody) [18] and cabozantinib (tyrosine kinase inhibitor) [19] have both gained advantage over everolimus as second- and third-line treatment. In its registration study, nivolumab demonstrated

significant activity, leading to mOS of 25 months. In the case of cabozantinib, on the other hand, median overall survival was 21 months. As those drugs are not available in Poland, we believe that everolimus (next to axitinib) remains a valuable second-line therapeutic option for mRCC patients. Following progression (third line), it is best (due to the lack of available and efficacious systemic treatment) to qualify patients for clinical trials or to offer them best supportive care, if the former is not possible.

## CONCLUSION

Everolimus prolongs PFS in patients with metastatic renal cell carcinoma who had previously been treated with tyrosine kinase inhibitors. Adverse events were reported in over a half of the patients, but most of them were mild to moderate.

## References

1. Ferlay J, Shin HR, Bray F et al. International Agency for Research on Cancer, Lyon, France 2010 [online: [www.globocan.iarc.fr](http://www.globocan.iarc.fr)].
2. National Cancer Registry [online: <http://onkologia.org.pl/nawotwory-zlosliwe-nerki-c67/>].
3. Eble JN, Sauter G, Epstein JI, Sesterhenn IA (ed.): World Health Organization Classification of Tumours. Pathology and Genetics of Tumours of the Urinary System and Male Genital Organs. IARC Press: Lyon 2004.
4. Hemal AK, Kumar A, Kumar R et al. Laparoscopic versus open radical nephrectomy for large renal tumors: a long-term prospective comparison. *J Urol* 2007; 177(3): 862-866.
5. Berger A, Brandina R, Atalla MA et al. Laparoscopic radical nephrectomy for renal cell carcinoma: oncological outcomes at 10 years or more. *J Urol* 2009; 182: 2172-2176.
6. Delakas D, Karyotis I, Daskalopoulos G. et al. Nephron-sparing surgery for localized renal cell carcinoma with a normal contralateral kidney: a European three-center experience. *Urology* 2002; 60(6): 998-1002.
7. MacLennan S, Imamura M, Lapitan MC et al. Systematic review of oncological outcomes following surgical management of localised renal cancer. *Eur Urol* 2012; 61: 972-993.
8. Wu Z, Li M, Liu B et al. (Coppola D. ed.). Robotic versus Open Partial Nephrectomy: A Systematic Review and Meta-Analysis. *PLoS ONE* 2014; 9(4): e94878. DOI: 10.1371/journal.pone.0094878.
9. Gitlitz BJ, Figlin RA. Cytokine-based therapy for metastatic renal cell cancer. *Urol Clin North Am* 2003; 30(3): 589-600.
10. Rosenberg SA, Yang JC, White DE et al. Durability of complete responses in patients with metastatic cancer treated with high-dose interleukin-2: identification of the antigens mediating response. *Ann Surg* 1998; 228(3): 307-319.
11. Fisher RI, Rosenberg SA, Fyfe G. Long-term survival update for high-dose recombinant interleukin-2 in patients with renal cell carcinoma. *Cancer J Sci Am* 2000; 6 (suppl 1): S55.
12. Coppin C, Proszolt R, Awa A et al. Immunotherapy for advanced renal cell cancer. *Cochrane Database Sys Rev* 2005; 1: CD001425.
13. de Reijke TM, Bellmunt J, van Poppel H et al. EORTC-GU group expert opinion on metastatic renal cell cancer. *Eur J Cancer* 2009; 45(5): 765-773.
14. Heng DY, Xie W, Regan MM et al. External validation and comparison with other models of the International Metastatic Renal-Cell Carcinoma Database Consortium prognostic model: a population-based study. *Lancet Oncol* 2013; 14(2): 141-148.
15. Chrom P, Stec R, Semeniuk-Wojtas A et al. Fuhrman Grade and Neutrophil-To-Lymphocyte Ratio Influence on Survival in Patients With Metastatic Renal Cell Carcinoma Treated With First-Line Tyrosine Kinase Inhibitors. *Clin Genitourin Cancer* 2016; 14(5): 457-464.
16. Treatment of malignant kidney neoplasms (ICD-10 C 64) – drug reimbursement programme of the Ministry of Health. [online: <http://www.mz.gov.pl/leki/refundacja/programy-lekowe/>].
17. Motzer RJ, Escudier B, Oudard S et al. Phase 3 trial of everolimus for metastatic renal cell carcinoma : final results and analysis of prognostic factors. *Cancer* 2010 15; 116(18): 4256-4265.
18. Motzer RJ, Escudier B, McDermott DF et al. Nivolumab versus Everolimus in Advanced Renal-Cell Carcinoma. *N Engl J Med* 2015; 373: 1803-1813.
19. Choueiri TK, Escudier B, Powles T et al. Cabozantinib versus everolimus in advanced renal cell carcinoma (METEOR): final results from a randomised, openlabel, phase 3 trial. *Lancet Oncol* 2016; 17: 917-927.

## Authors' contributions:

Paweł Hernik: 45%; Maksymilian Kruczała: 45%; Marek Ziobro: 10%.

## Conflict of interests:

None.

## Financial support:

None.

## Ethics:

The paper complies with the Helsinki Declaration, EU Directives and harmonized requirements for biomedical journals.