

Review article

## Current diagnosis and treatment of Nelson's syndrome

**Katarzyna Ożga<sup>1</sup>, Grzegorz Zieliński<sup>2</sup>, Łukasz Konecki<sup>3</sup>, Marta Mazur<sup>3</sup>, Przemysław Witek<sup>3</sup>**

<sup>1</sup> University Hospital in Cracow

<sup>2</sup> Department of Neurosurgery, Central Teaching Hospital of the Ministry of Defence, Military Institute of Medicine

<sup>3</sup> Department of Gastroenterology, Endocrinology and Internal Diseases, Central Teaching Hospital of the Ministry of Defence, Military Institute of Medicine

For non-commercial use only

### Correspondence:

Przemysław Witek  
Department of Gastroenterology,  
Endocrinology and Internal  
Diseases, Central Teaching  
Hospital of the Ministry of Defence,  
Military Institute of Medicine  
04-141 Warsaw, ul. Szaserów 128  
e-mail: pwitek@wim.mil.pl;  
drpwitek@gmail.com

### Received:

18.03.2018

### Accepted:

30.05.2018

DOI: 10.24292/01.OR.300518  
Copyright © Medical Education.

All rights reserved.

### ABSTRACT

Nelson's syndrome is a rare condition of enlarging pituitary mass lesion producing ACTH that can develop after total bilateral adrenalectomy (TBA) in patients with Cushing's disease. It is characterized by hyperpigmentation of the skin and mucous membranes and elevated plasma levels of ACTH. In this clinical review, the diagnosis and treatment strategies of patients with Nelson's syndrome including surgery, radiation, and pharmacotherapy are presented.

**Key words:** Nelson's syndrome, bilateral adrenalectomy, hyperpigmentation, transsphenoidal surgery, temozolomide

## INTRODUCTION

Nelson's syndrome (NS) is an aggressive enlargement of pituitary corticotroph tumour in Cushing's syndrome patients following a total bilateral adrenalectomy. Its prevalence is reported at 8–43% in adult patients and 25–66% in the paediatric population [1, 2]. It typically develops within 15 years from the removal of adrenals, although NS has also been reported to occur up to 24 years after the surgery [1].

NS was first described in 1958. The case of a 33-year old female patient was presented in whom characteristic symptoms were seen 3 years after a bilateral adrenalectomy, including hyperpigmentation of the skin, impaired field of view, elevated plasma levels of adrenocorticotrophic hormone (ACTH) and an invasive pituitary tumour discovered in a radiogram [4].

At present, due to the high success-rate of surgical procedures, including primarily selective transsphenoidal adenectomy, and the use of medication directly affecting the pituitary tumour (pasireotide, cabergoline), bilateral adrenalectomies are performed less frequently which translates into lower NS incidence.

## ETIOPATHOGENESIS OF NELSON'S SYNDROME

The factor behind development of Nelson's syndrome is the presence of a pituitary corticotroph tumour. Such tumours typically include microadenomas of which even 50% may be smaller in size than 5 mm. In some cases, this creates difficulties in identifying the location of lesions in magnetic resonance imaging (MRI) scans of the pituitary gland in patients with persistent somatic symptoms of hypercortisolaemia. The inability to identify the tumour location in an MRI study, and later during exploration of the sella turcica, makes the surgery less successful. When chronic hypercortisolaemia cannot be effectively managed by medication (which is a life-threatening condition), a bilateral removal of adrenal glands becomes necessary. It eliminates the negative feedback (partly retained in Cushing's syndrome) while high cortisol levels inhibit the growth of a pituitary corticotroph tumour. After the surgery, patients routinely receive low doses of hydrocortisone (25–35 mg) which might be insufficient; for this reason, some patients develop NS. A similar mechanism is observed in patients with pituitary micro- or macroadenomas which location has been determined precisely, but which cannot be completely removed due to their position or invasion of adjacent structures. However, NS only develops in some, not all, patients who have undergone bilateral adrenalectomy. The development is conditional on individual traits of the tumour such as its growth poten-

tial and invasiveness. Clinical observations suggest that NS more frequently develops in patients with a history of rapidly progressing Cushing's disease.

## SYMPTOMS OF NELSON'S SYNDROME

The disorder's clinical symptoms associated with the enlarging tumour include headaches, impaired field of view and cranial nerves palsy. The most frequent symptom seen in the majority of patients is hyperpigmentation of the skin and mucous membranes. This follows from the high levels of ACTH affecting melanocyte-stimulating hormone receptors in the skin. Other, less frequent symptoms, include: pituitary stroke and insufficiency, and growth of ovarian and testicular tumours emanating from the ectopic adrenal tissue under the influence of rising ACTH levels after bilateral adrenalectomy [6–8].

Clinical symptoms appear relatively late and this is why at present the diagnostic process is mostly based on imaging studies such as MRI and computed tomography (CT), as well as hormonal tests, all of above makes it more possible to diagnose NS at earlier stage.

In terms of biochemical traits, Nelson's syndrome is characterised by elevated plasma levels of ACTH which keep growing after bilateral adrenalectomy. In patients with Nelson's syndrome, basal ACTH secretion may be increased even six-fold and pulsatile secretion nine-fold relative to levels in Cushing's disease patients [9]. In order to test ACTH levels, a sample of blood should be taken at 8 am before the morning dose of glucocorticoids and 20 hours after the last dose received [10], and another blood sample should be taken 2 hours after administering the morning dose of glucocorticoids.

In a radiological study, the typical feature of Nelson's syndrome is an enlarging pituitary tumour [11]. MRI scans reveal tumours measuring even 3 mm in diameter, which makes it possible to diagnose the disorder at an early stage of progression [11]. An MRI study is recommended to be performed for each patient who has undergone a bilateral adrenalectomy. The first study should be performed 3 months after the surgery [11], followed by MRI scans performed every 6 months for two years, and later once a year till the end of the patient's life.

## DIAGNOSTIC CRITERIA OF NELSON'S SYNDROME

Early diagnosis of Nelson's syndrome is very important due to the rapid and invasive growth of the tumour. The disorder is usually

manifested by a triad of symptoms, including hyperpigmentation of the skin, enlarging pituitary tumour after adrenalectomy and elevated plasma levels of ACTH. However, no uniform and universally accepted criteria have been defined.

In particular, hyperpigmentation of the skin and mucous membranes raises concerns due to the fact that the assessment is subjective and no correlation has been proven to exist between ACTH levels and the darkening of the skin [12]. For this reason, the basic diagnostic criteria of Nelson's syndrome no longer include clinical manifestations of the disorder.

It seems that a history of persistent Cushing's disease treated with bilateral adrenalectomy can be assumed to be an essential criterion for the initial diagnosis of NS. Barber et al. propose that one of the two following criteria must be met in order to diagnose NS in this group of patients:

1. Radiologically confirmed (by a pituitary MRI scan) progressing growth of corticotroph tumour relative to its size from before a bilateral adrenalectomy.
2. Plasma ACTH level (after bilateral adrenalectomy) exceeding 500 ng/l in a sample collected at 8 am before the administration of a hydrocortisone replacement dose, in addition to progressive elevations of ACTH on at least 3 consecutive blood samples by at least 30% relative to the basal level measured following an adrenalectomy [13].

### DIAGNOSTIC IMAGING TECHNIQUES

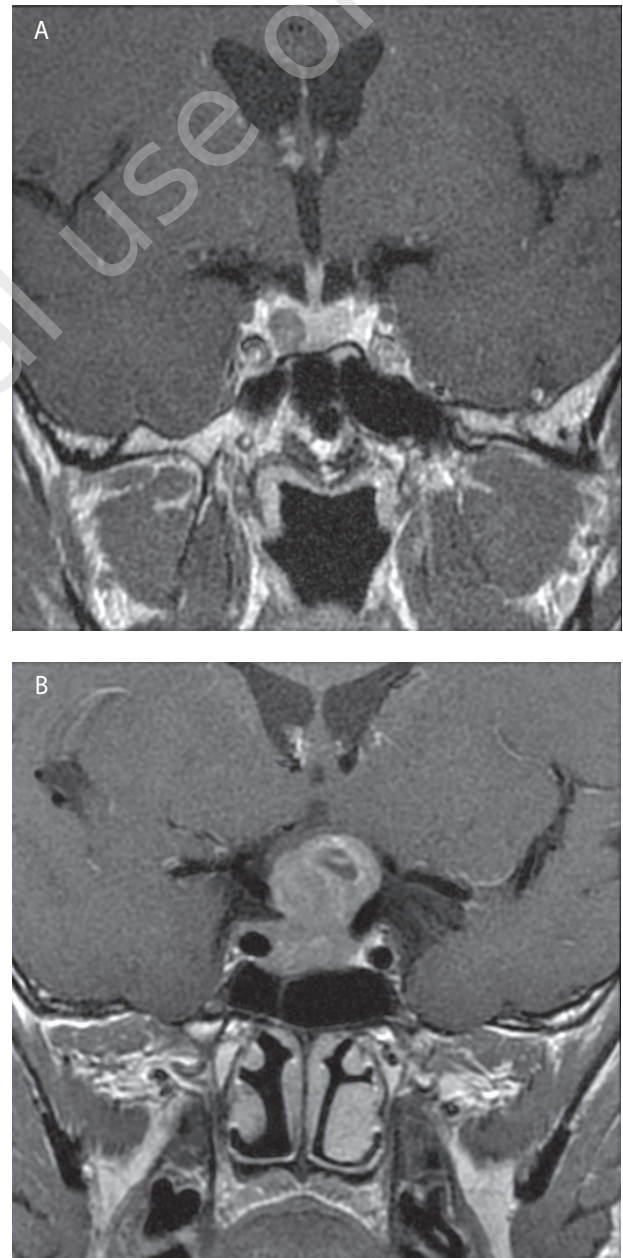
The method of choice for Nelson's syndrome imaging is MRI (fig. 1). When diagnosing NS, it is important to have access to initial imaging studies from the time of diagnosing Cushing's disease as well as those from after its surgical treatment, if any. These aid a precise assessment and classification of corticotroph tumour growth after a bilateral adrenalectomy.

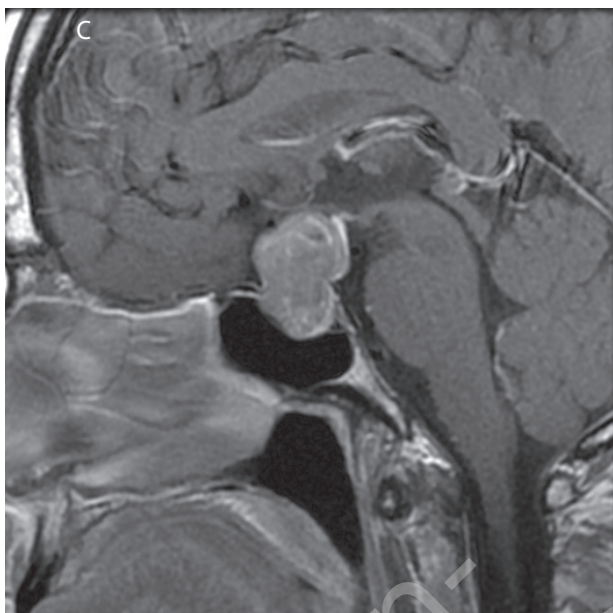
Computed tomography should only be used in case of pituitary tumours, including for the purpose of diagnosing Nelson's syndrome, when an MRI study is contraindicated.

Other imaging techniques include: somatostatin receptor scintigraphy (in Poland performed using a  $^{99m}\text{Tc}$ -Tektrotyd) and positron emission tomography (PET) using an  $^{11}\text{C}$ -labeled methionine analogue. Due to the high concentration of glucose in healthy brain tissue, an  $^{18}\text{F}$ -deoxyglucose (FDG) PET scan has a limited diagnostic value [14, 15, 31].

FIGURE 1.

Corticotroph tumours in patients with Nelson's syndrome documented by MRI. A. a coronal view of a corticotroph microadenoma (T1 + contrast agent) revealed in a patient with Cushing's disease post bilateral adrenalectomy in whom previously no abnormalities could be detected by means of MRI. B. and C. an invasive corticotroph macroadenoma in a patient after a bilateral adrenalectomy, involving a suprasellar extension, destruction of the bottom of sella turcica, compression of the optic chiasm and invasion of the right cavernous sinus (T1 + contrast agent; B. – coronal view, C. – sagittal view).





### TREATING NELSON'S SYNDROME

A surgical removal of the tumour using a transsphenoidal or transcranial (craniotomy) approach is the treatment of choice in Nelson's syndrome. Like in the case of other pituitary tumours, the success rate of surgical treatment of NS depends on the size of the tumour and its relation to adjacent structures, in particular invasion of cavernous sinuses (graded in accordance with the Knosp scale). Surgical treatment may have to be performed multiple times when tumours are large, invasive and infiltrate adjacent tissue. This is associated with the fact that the procedure is incomplete, and that tumours grow back due to elimination of the negative feedback as a result of prior removal of adrenal glands [3, 5]. The surgery may lead to complications, such as multiple pituitary hormone deficiency, cerebrospinal fluid rhinorrhoea and meningitis [5].

Radiotherapy may be used in Nelson's syndrome on an adjuvant basis following incomplete and, frequently, repeated surgical treatment. However, it should be noted that radiotherapy takes a long time to produce an effect, up to several years at times, and it may lead to such complications as neuropathy of the optic nerve, hypopituitarism, cerebral oedema and radiation-induced encephalitis [5]. To reduce the risk of complications, fractionated stereotactic radiotherapy (FSRT) or proton therapy are often used. With a view to protecting the optic nerve from damage by the prescribed ionising radiation dose (45–50 Gy), radiotherapy is administered in fractionated doses of 1.8–2.0 Gy [17, 41, 42].

Routinely administered radiotherapy of pituitary corticotroph tumours following bilateral adrenalectomy (performed by certain centres) is an area of controversy, and is not deemed to be the standard of care for lack of medical proof of its efficacy [18].

### PHARMACOLOGICAL TREATMENT

Historically, a range of different products were studied and used to treat Nelson's syndrome. Rosiglitazone is a PPAR agonist. In mice models, rosiglitazone in doses of 150 mg per kilogram of body mass has been proven to repress POMC mRNA transcription in corticotrophic cells [19] and to cause cell apoptosis *in vitro* while *in vivo* it has been shown to reduce ACTH secretion [19]. However, studies on human subjects have not confirmed this drug's efficacy in Nelson's syndrome. Similarly, the efficacy of sodium valproate and cyproheptadine has not been definitively established [21].

On the other hand, a new multi-receptor somatostatin analogue (pasireotide), acting on SSTR 1, 2, 3 and 5, shows an inhibitory effect on ACTH secretion in corticotrophic cells of patients with Cushing's disease *in vitro* [22]. Katznelson used pasireotide LAR in a Nelson's syndrome patient and decreased ACTH secretion and skin hyperpigmentation as well as reduced the tumour volume to the extent visible in an MRI study [20].

Daniel et al. demonstrated a significant reduction of ACTH level and a clinical improvement in a group of 7 Nelson's syndrome patients, however the volumes of pituitary tumours did not decrease significantly. It seems that further studies need to be made (or a meta-analysis of the data) to examine the effect of pasireotide LAR on pituitary tumour size in NS [23].

### Dopamine agonists

Expression of dopamine receptors is seen in pituitary corticotroph adenomas, which is why dopamine agonists are used for their treatment. Previously, cabergoline, a selective D2-dopaminergic receptors agonist, has been shown to be moderately efficacious in treating Cushing's disease [24]. There are single reports which demonstrate efficacy of cabergoline (but not bromocriptine) in reducing ACTH levels and achieving a clinical improvement in Nelson's syndrome. This matter needs to be further investigated [24–26].

### Temozolomide

Temozolomide (TMZ) is an alkylating agent, used mostly for treatment of polymorphic gliomas as an adjuvant therapy to incomplete surgical treatment. Temozolomide has been reported



to be efficacious in treating invasive pituitary tumours, particularly when the tumours exhibited a low MGMT (0-6-methylguanine-DNA methyltransferase) expression [16, 27].

TMZ's efficacy varies; it may lead to a rapid and marked tumour shrinkage, a moderate reduction of tumour mass or a tumour size stabilisation, or it may inhibit its further growth [29]. McCormack et al. suggest that ACTH-secreting pituitary tumours are among those that show the best response to TMZ treatment, with success rates reaching as much as 60% [28]. In studies conducted by Raverot et al., ACTH secretion was reduced by 67% and tumour mass decreased by 56% in patients with a corticotroph tumour following a TMZ therapy [27]. Similar data was also presented by other authors [30]. However, using temozolomide to treat NS requires further studies to be conducted, and its place in NS therapy remains yet to be clearly defined.

## SUMMARY

Nelson's syndrome is a complication of a bilateral adrenalectomy used as a radical treatment of persistent ACTH-dependent hypercortisolaemia which cannot be controlled by other methods. Due to advancement in diagnostic imaging as well as surgical and pharmacological therapies (including those that act directly on the pituitary tumour), NS is currently less frequently diagnosed than in the past. However, it remains to be a challenge for both endocrinologists and neurosurgeons. Selective transsphenoidal removal of the tumour by an experienced neurosurgeon is still considered to be the treatment of choice, while large tumours are removed using a transcranial approach. Radiotherapy may be used on an adjuvant basis, if necessary. In terms of pharmacotherapies, pasireotide LAR, a second-generation somatostatin analogue, shows promising outcomes but further studies need to be conducted to obtain a conclusive confirmation.

## References

1. Nagesser SK, van Seters AP, Kievit J et al. Long-term results of total adrenalectomy for Cushing's disease. *World J Surg* 2000; 24: 108-113.
2. Hopwood NJ, Kenny FM. Incidence of Nelson's syndrome after adrenalectomy for Cushing's disease in children: results of a nationwide survey. *Am J Dis Child* 1977; 131: 1353-1356.
3. De Tommasi C, Vance ML, Okonkwo DO et al. Surgical management of adrenocorticotrophic hormone-secreting macroadenomas: outcome and challenges in patients with Cushing's disease or Nelson's syndrome. *J Neurosurg* 2005; 103: 825-830.
4. Nelson DHJW, Meakin JB, Dealy JB Jr et al. ACTH – producing tumor of the pituitary gland. *N Engl J Med* 1958; 259: 161-164.
5. Kelly PA, Samandouras G, Grossman AB et al. Neurosurgical treatment of Nelson's syndrome. *J Clin Endocrinol Metab* 2002; 87: 5465-5469.
6. Rees JR, Zilva JF. Diabetes insipidus complicating total adrenalectomy. *J Clin Pathol* 1959; 12: 530-534.
7. Baranetsky NGRD, Zipser U, Goebelsmann U. Adrenocorticotropin – dependent virilizing paraovarian tumors in Nelson's syndrome. *J Clin Endocrinol Metab* 1979; 49: 381-386.
8. Shekarriz M, Schneider C, Sabanegh E et al. Excessive testosterone production in a patient with Nelson syndrome and bilateral testicular tumors. *Urol Int* 1996; 56: 200-203.
9. van Aken MO, Pereira AM, van den Berg G et al. Profound amplification of secretoryburst mass and anomalous regularity of ACTH secretory process in patients with Nelson's syndrome compared with Cushing's disease. *Clin Endocrinol* 2004; 60: 765-772.
10. Munir A, Newell-Price J. Nelson's Syndrome. *Arq Bras Endocrinol Metabol* 2007; 51: 1392-1396.
11. Banasiak MJ, Malek AR. Nelson syndrome: comprehensive review of pathophysiology diagnosis and management. *Neurosurg Focus* 2007; 23: E13.
12. Kimura N, Ishikawa T, Sasaki Y et al. Expression of prohormone convertase, PC2, in adrenocorticotropin-producing thymic carcinoid with elevated plasma corticotropin-releasing hormone. *J Clin Endocrinol Metab* 1996; 81: 390-395.
13. Barber TM, Adams E, Ansorge O et al. Nelson's syndrome. *Eur J Endocrinol* 2010; 163: 495-507.
14. Tang BN, Levivier M, Heureux M et al. 11C-methionine PET for the diagnosis and management of recurrent pituitary adenomas. *Eur J Nucl Med Mol Imaging* 2006; 33(2): 169-178.
15. Jeong SY, Lee SW, Lee HJ et al. Incidental pituitary uptake on whole-body 18F-FDG PET/CT: a multicentre study. *Eur J Nucl Med Mol Imaging* 2010; 37(12): 2334-2343.
16. Patel J, Eloy JA, Liu JK. Nelson's syndrome: a review of the clinical manifestations, pathophysiology, and treatment strategies. *Neurosurg Focus* 2015; 38(2): E14.
17. Leber KA, Bergloff J, Pendl G. Dose-response tolerance of the visual pathways and cranial nerves of the cavernous sinus to stereotactic radiosurgery. *J Neurosurg* 1998; 88: 43-50.
18. Mauermann WJ, Sheehan JP, Chernavsky DR et al. Gamma Knife surgery for adrenocorticotrophic hormone producing pituitary adenomas after bilateral adrenalectomy. *J Neurosurg* 2007; 106: 988-993.
19. Heaney AP, Fernando M, Yong WH, Melmed S. Functional PPAR-g receptor is a novel therapeutic target for ACTH-secreting pituitary adenomas. *Nat Med* 2002; 8: 1281-1287.
20. Katznelson L. Sustained improvements in plasma ACTH and clinical status in a patient with Nelson's syndrome treated with pasireotide LAR, a multireceptor somatostatin analog. *J Clin Endocrinol Metab* 2013; 98(5): 1803-1807.

21. Kasperlik-Załuska AA, Zgliczyński W, Jeske W et al. ACTH responses to somatostatin, valproic acid and dexamethasone in Nelson's syndrome. *Neuroendocrinol Letters* 2005; 26: 709-712.
22. Hofland LJ, van der Hoek J, Feelders R et al. The multi-ligand somatostatin analogue SOM230 inhibits ACTH secretion by cultured human corticotroph adenomas via somatostatin receptor type 5. *Eur J Endocrinol* 2005; 152: 645-654.
23. Daniel E, Debono M, Caunt S et al. A prospective longitudinal study of Pasireotide in Nelson's syndrome. *Pituitary* 2018; 21(3): 247-255.
24. Pivonello R, Faggiano A, Di Salle F et al. Complete remission of Nelson's syndrome after 1-year treatment with cabergoline. *J Endocrinol Invest* 1999; 22(11): 860-865.
25. Shraga-Slutzky I, Shimon I, Weinshtein R. Clinical and biochemical stabilization of Nelson's syndrome with long-term low-dose cabergoline treatment. *Pituitary* 2006; 9: 151-154.
26. Casulari LA, Naves LA, Mello PA et al. Nelson's syndrome: complete remission with cabergoline but not with bromocriptine or cyproheptadine treatment. *Hormone Res* 2004; 62: 300-305.
27. Raverot G, Castinetti F, Jouanneau E et al. Pituitary carcinomas and aggressive pituitary tumours: Merits and pitfalls of temozolomide treatment. *Clin Endocrinol* 2012; 76(6): 769-775.
28. McCormack AI, Wass JA, Grossman AB. Aggressive pituitary tumours: the role of temozolomide and the assessment of MGMT status. *Eur J Clin Invest* 2011; 41(10): 1133-1148.
29. Dillard TH, Gultekin SH, Delashaw JB Jr. et al. Temozolomide for corticotroph pituitary adenomas refractory to standard therapy. *Pituitary* 2011; 14(1): 80-91.
30. Curto L, Torre ML, Ferrau F et al. Temozolomide-induced shrinkage of a pituitary carcinoma causing Cushing's disease- report of a case and literature review. *Sci World J* 2010; 10: 2132-2138.
31. Koulouri O, Steuwe A, Gillett D et al. A role for C-methionine PET imaging in ACTH-dependent Cushing's syndrome. *Eur J Endocrinol* 2015; 173: M107-M120.

**Authors' contributions:**

Katarzyna Ożga: 60%; Grzegorz Zieliński: 5%; Łukasz Konecki: 5%; Marta Mazur: 5%; Przemysław Witek: 25%.

**Conflict of interests:**

None.

**Financial support:**

None.

**Ethics:**

The paper complies with the Helsinki Declaration, EU Directives and harmonized requirements for biomedical journals.