

Review article

Challenges in diagnosing and treating pancreatic neuroendocrine tumours in patients with a multiple endocrine neoplasia type 1 (MEN1) syndrome

Natalia Rogozik¹, Agnieszka Kolasińska-Ćwikła², Jarosław B. Ćwikła³, Andrzej Cichocki⁴, Adam Przybyłkowski⁵, Maciej Słodkowski⁶, Tomasz Bednarczuk¹

¹ Chair and Department of Internal Diseases and Endocrinology, Medical University of Warsaw

² Chemotherapy Ward, Department of Oncology, Maria Skłodowska-Curie Institute of Oncology in Warsaw

³ Chair of Radiology, Faculty of Medical Sciences, University of Warmia and Mazury in Olsztyn

⁴ Department of General and Endocrine Surgery, Maria Skłodowska-Curie Institute of Oncology in Warsaw

⁵ Department of Gastroenterology and Internal Diseases, Medical University of Warsaw

⁶ Chair and Department of General, Gastroenterological and Oncological Surgery, Medical University of Warsaw

ABSTRACT

Multiple endocrine neoplasia type 1 (MEN1) syndrome is an autosomal dominant hereditary disorder characterised by coexistence of pancreatic neuroendocrine tumours (pNETs) with parathyroid and pituitary tumours. PNETs, including mostly non-functioning tumours, gastrinoma and insulinoma, occur in nearly 95% of MEN1 patients and account for over 50% of disorder-related mortality. Therefore, early initiation of screening for pNET using biochemical and imaging tests as well as appropriate surgical and systemic treatment are of particular importance for this group of patients. Currently, there are no clearly defined guidelines which determine the optimal methods for detection and treatment of pNET in MEN1. Caution should be exercised when applying the guidelines designed for patients with sporadic pNET to MEN1 patients as the clinical course of the disorder is slightly different, involving multifocality of lesions and younger age of patients at onset. This paper discusses the distinctive features and challenges in diagnosing and treating pNETs in MEN1 patients.

Key words: pancreatic neuroendocrine tumours, multiple endocrine neoplasia type 1 syndrome, diagnosis, treatment

Correspondence:

Natalia Rogozik
Chair and Department of Internal
Diseases and Endocrinology, Central
Clinical Hospital in Warsaw
02-097 Warsaw, ul. Banacha 1a
tel.: (+48) 22 599-17-23
e-mail: natalia.rogozikk@gmail.com

Received:

1.04.2018

Accepted:

27.05.2018

DOI: 10.24292/01.OR.270518
Copyright © Medical Education.

All rights reserved.

INTRODUCTION

Multiple endocrine neoplasia type 1 (MEN1) syndrome is a genetic disorder with an autosomal dominant inheritance involving a high genetic penetrance leading to a mutation of menin, a suppressor protein. It is estimated that over 98% of patients diagnosed with menin gene mutation manifest clinical and biochemical symptoms of the disorder by the end of the fifth decade of their life [1]. A *de novo* mutation occurs in ca. 10% of patients with no family history of MEN1 syndrome [2]. In approx. 5–25% patients with clinical manifestations of MEN1 syndrome, the mutation of MEN1 gene is not detected by standard workup [1]. In order to make a clinical diagnosis of this disorder in patients with a negative family history of MEN1, it is necessary to establish the coexistence of at least two of the three following abnormalities: pancreatic neuroendocrine tumours, focal parathyroid lesions and pituitary adenomas. In case of a positive family history of MEN1 gene mutations, it is sufficient to identify the presence of just one of the three lesions specified above. More than ten different types of endocrine and non-endocrine neoplasms may occur in the course of this disorder [1, 3] (tab. 1).

TABLE 1.
 Prevalence of tumours in the course of MEN1 syndrome (modified based on [1, 4]).

Tumour type	Prevalence [%]
Parathyroid adenoma	90
Neuroendocrine tumours non-functioning (no hormonal activity)	95
gastrinoma	20–55
insulinoma	40
glucagonoma, somatostatinoma, VIPoma	10
Pituitary adenoma	< 3
Adrenocortical adenoma	30–40
Pheochromocytoma	40
Bronchial neuroendocrine tumour	< 1
Thymus neuroendocrine tumour	2
Gastric neuroendocrine tumour	2
Lipoma	10
Angiofibroma	30
Collagenoma	85
Meningioma	70
	8

The prevalence of MEN1 syndrome is ca. 1 : 30,000. The disorder is estimated to affect 1–18% patients with primary hyperparathyroidism, 16–38% patients with gastrinoma and less than 3% patients with pituitary tumours [1].

To date, the prevalence of pancreatic neuroendocrine tumours (pNETs) in MEN1 patients has been assumed at ca. 30–70% [1]. However, results of autopsy studies suggest that pNET occur in nearly all MEN1 patients (> 95%), albeit most of the tumours are

small in size (< 5 mm) and do not produce symptoms [4]. The features of MEN1-associated pNETs which differentiate them from sporadic pNETs include the multifocality and occurrence in younger patients.

MEN1 patients develop both functioning and non-functioning pancreatic neuroendocrine tumours (referred to as, respectively, F-pNETs and NF-pNETs). F-pNETs show hormonal activity leading to corresponding clinical symptoms: gastrinoma (in 40% MEN1 patients), insulinoma (in 10% MEN1 patients) and rare syndromes including VIPoma, glucagonoma and somatostatinoma (in less than 3% patients) [1–5]. NF-pNETs affect 20–55% MEN1 patients, and despite the absence of hormonal hypersecretion symptoms, they may be capable of producing certain substances, such as pancreatic polypeptide (PP), chromogranin A (CgA) and neuron-specific enolase (NSE) [1, 5]. It is estimated that less than 15% NF-pNETs will grow enough to produce symptoms resulting from tumour mass [4].

Approximately 20% of patients with gastrinoma are diagnosed with MEN1 syndrome. Those lesions are often small in size (< 5 mm) and numerous. In over 80% cases they are located in the duodenum, although a note must be made that duodenal and pancreatic gastrinoma occurs in ca. 13% patients, while the incidence of these neoplasms in the pancreas only is lower [1, 2]. They are characterised by a slow growth and a high potential of producing lymph node metastases (in 34–85% patients at the time of diagnosis) and, less frequently, hepatic metastases [1, 2]. In MEN1 patients, the effects of hypergastrinemia which lead to recurring and numerous peptic ulcers are exacerbated by coexisting hypercalcemia associated with primary hyperparathyroidism. Hypercalcemia leads to an augmented gastrin secretion. For this reason, striving to achieve normal levels of calcium is important for this group of patients. It has been demonstrated that following an effective treatment of primary hyperparathyroidism ca. 20% MEN1 patients showing symptoms of the Zollinger–Ellison syndrome experienced a significant reduction of hypergastrinemia symptoms [1].

Approximately 4% patients with insulinoma are diagnosed with MEN1 syndrome. Patients often develop single tumours, with sizes generally not exceeding 5 mm. Insulinoma occurs earlier in MEN1 patients than gastrinoma. In 25% cases, insulinoma develops in patients below the age of 20 [5]. Insulinoma is estimated to coexist with NF-pNETs in 10% patients [1].

It is vitally important to diagnose and treat pNETs as those tumours represent the chief reason for mortality caused by MEN1

syndrome complications (40%). The average life expectancy of patients in whom MEN 1 coexists with pNETs is 55 years, which is shorter when compared to the general population and to MEN1 patients without pNET [6].

DIAGNOSING MEN1 IN PATIENTS WITH PNETS

MEN1 syndrome should be suspected in pNET patients in the following situations:

- coexistence of pNETs with primary hyperparathyroidism and/or pituitary adenoma
- coexistence of pNETs with other endocrine tumours associated with MEN1, e.g. pNET and adrenocortical adenoma
- multiple pNETs regardless of patient's age
- gastrinoma regardless of patient's age
- insulinoma in patients below the age of 20 [1, 3, 5].

All patients with pNET and a clinical diagnosis or suspicion of MEN1 syndrome should be offered a genetic test. If genetic testing is not accessible, basic laboratory screening tests for MEN1, including tests of total calcium, parathormone and prolactin levels, are proposed to be performed. This follows from the distinctive clinical course of pNET in MEN1 which may affect diagnostic and therapeutic decisions later, as well as the need to screen patients for other neoplasms associated with MEN1 annually (tab. 2). Genetic tests should also be suggested to first-degree relatives of patients diagnosed with MEN1 mutation. In such cases, it is recommended to perform genetic tests as early as possible, preferably before the age of five. The prevalence of pNETs in the second decade of life of patients diagnosed with MEN1 mutation is estimated at 40%, while some reports confirm pNET prevalence in patients aged 5 to 12 years [2, 7]. First-degree relatives in whom no such mutations are detected are not required to be monitored any further. On the other hand, first-degree relatives who are diagnosed with MEN1 mutation are subject to annual screening using biochemical and imaging tests from the age of 5 (tab. 2).

TABLE 2.

Follow-up of relatives of patients with multiple endocrine neoplasia type 1, MEN1 mutation carriers (modified based on [1, 3]).

Tumour	Age at the beginning of monitoring (in years)	Biochemical tests annually	Imaging studies
Parathyroid adenoma	8	calcium, PTH	(-)
Pituitary adenoma	5	PRL, IGF-1	MRI every 3 years
Gastrinoma	20	gastrin (stomach pH)	(-)
Insulinoma	5	glucose, fasting insulin	(-)
Other pNET	< 10	CgA, PP, glucagon, VIP	MRI, CT or EUS annually
Adrenal adenoma	< 10	only in symptomatic patients or when tumour size > 10 mm	MRI, CT and pancreas assessment annually
Thymus and bronchial carcinoid	15	(-)	CT or MRI every 1–2 years

PTH – parathormone; PRL – prolactin; IGF-1 – insulin-like growth factor 1; CgA – chromogranin A; PP – pancreatic polypeptide; VIP – vasoactive intestinal peptide; CT – computed tomography; MRI – magnetic resonance imaging; EUS – endoscopic ultrasound scan.

CHALLENGES IN LABORATORY DIAGNOSTICS OF PNETS IN MEN1

In case of patients with MEN1 mutation, the guidelines [1] recommend that annual laboratory screening is performed to detect pNETs (comprising tests of chromogranin A, pancreatic polypeptide, gastrin, glucose and fasting insulin levels, tests of glucagon and VIP levels) from the first decade of life. However, this is a weak recommendation based on low quality evidence. pNET markers such as chromogranin A or pancreatic polypeptide have proven their diagnostic value in case of sporadic lesions [5, 8]. In contrast, medical literature contains few papers demonstrating usefulness of standard pNET markers in MEN1 patients. Available research data suggests that the diagnostic value of such markers is limited, with the diagnostic sensitivity of chromogranin A, pancreatic polypeptide and glucagon in this group of patients reaching, respectively, 33%, 36% and 43% [9]. No significant correlation between the substances named above and the size and number of lesions, tumour location and the stage of progression of the disorder has been demonstrated, while chromogranin A levels have not declined following surgical treatment [10].

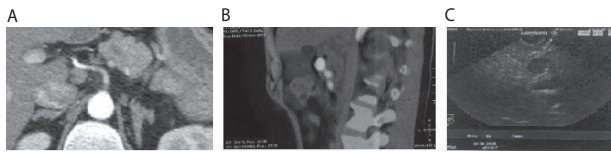
The absence of sufficiently sensitive and specific pNET markers to be used in MEN1 patients requires additional imaging studies to be performed on an annual basis. At present, studies are being conducted on new neuroendocrine tumour markers, including a PCR analysis of neuroendocrine tumour molecules in peripheral blood (e.g. NETest) [11].

CHALLENGES IN DIAGNOSTIC IMAGING OF PNETS IN MEN1

According to guidelines [1], MEN1 patients need to undergo annual screening in the form of imaging studies (CT, MRI, EUS) to detect the presence of pNETs starting from the first decade of life (fig. 1) but there are no clear guidelines that specify which imaging study is the test of choice for this group of patients.

FIGURE 1.

Imaging scans of a 44-year-old female MEN1 patient with three pNETs; A. computed tomography scan of the abdominal cavity; B. PET/CT with 68Ga-labeled somatostatin analogues; C. EUS scan.



Endoscopic ultrasonography (EUS) is probably the most sensitive method to detect pNETs smaller in size than 10 mm [12, 13]. However, this is an invasive method with result depending on the experience of the operator performing the procedure, and its sensitivity when imaging lesions in the distal portion of pancreas is inferior [13, 14].

Three-phase computed tomography (CT) is the most accessible and fast study, with a sensitivity of detecting pNETs in MEN1 patients rated at ca. 81%. The key issue that limits the safety of CT screening is the cumulative dose of ionising radiation to which patients are exposed, particularly in young age. In such cases, the alternative to be used is the more expensive and less accessible magnetic resonance imaging (MRI). Both types of studies are also used to assess the progression of the disorder and monitor the response to treatment.

Despite the high sensitivity of positron-emission tomography (PET-CT) using 68Ga-labeled somatostatin analogues in detecting pNETs, currently there are no clearly defined indications to perform the study on MEN1 patients. According to current guidelines, this study should be performed on each pNET patient considered for surgical treatment, and on patients with a metastatic disease for the purpose of assessing its progression [8]. PET-CT using 68Ga-labeled somatostatin analogues is not recommended for screening of asymptomatic MEN1 patients [5, 8].

CHALLENGES IN SURGICAL TREATMENT OF PNETS IN MEN1

The aim of surgical treatment of pNETs in MEN1 patients is to resolve the symptoms associated with hormonal activity of the lesions and to reduce the risk of distant metastases. In accordance with the guidelines [5, 8], a surgery is indicated for MEN1 patients in the following situations:

- lesion measuring more than 20 mm in case of gastrinoma and non-functioning pNETs due to a significantly higher risk of metastatic disease (tab. 3)

- identifying symptoms of hormone overproduction associated with insulinoma, somatostatinoma and VIPoma, regardless of the size of lesion [8].

TABLE 3.

Correlation between NF-pNET size and prevalence of metastatic disease [16].

NF-pNET size [mm]	Prevalence of metastatic disease [%]
≤ 10	4
11–20	10
21–30	18

It should be noted, that functioning pNETs may coexist with non-functioning pNETs (10% of insulinoma cases in MEN1 [1]), which makes it difficult to determine which lesions should be removed. In such cases of insulinoma, it is possible to perform an angiogram with a selective calcium stimulation test or a GLP-1 receptor analogue scintigraphy [5].

The different approach to surgical treatment of gastrinoma relative to other functional pNETs in MEN1 is due to the fact that the symptoms of the Zollinger–Ellison syndrome can be effectively managed by using proton-pump inhibitors, while ensuring the procedure is radical enough proves to be difficult. Such lesions are predominantly small in size, multifocal and located deep to the mucous membrane of duodenum, which leads to inferior therapeutic outcomes in case of conservative procedures. In order to detect the lesions during a surgery more effectively, intra-operative ultrasound scans are used.

The decision on how radical the procedure should be depends on the location and size of the lesion and its position relative to the pancreatic duct. The following surgical methods are used: enucleation (removal of the lesion with a narrow margin of healthy tissue), distal pancreatectomy (removal of a portion of the pancreas to the left of the superior mesenteric vein), pancreaticoduodenectomy using the Whipple technique (removal of the duodenum as well as the head and uncinate process of pancreas up to the superior mesenteric vein) and total pancreatectoduodenectomy (removal of the entire pancreas and duodenum) [15]. Postoperative complications after pNET surgery include pancreatic fistulas (25%) and symptoms associated with the impaired exocrine and endocrine function of the pancreas. Post-operative diabetes affects ca. 20–50% patients following the Whipple procedure and ca. 8–60% patients following distal pancreatectomy [15].

Minimally invasive techniques of treating pancreatic neuroendocrine tumours are being developed, such as, among others, EUS-guided radiofrequency ablation (RFA) of the tumour and EUS-guided ethanol injection into the tumour. In order to define their place in treating pNETs, consultations and assessments must be made during appropriately designed clinical studies [17, 18].

TREATING ADVANCED PNETS

In case of advanced pNETs in MEN1 patients, the following methods are used:

- local methods (cytoreductive procedures, EUS-guided ablation with ethanol injection, radiofrequency ablation – RFA, transarterial embolization/chemoembolization – TAE/TACE) [5, 19]
- systemic treatment (somatostatin analogues, tyrosine kinase inhibitors – TKI, mTOR kinase inhibitors, targeted peptide receptor radionuclide therapy – PRRT, chemotherapy) [5, 20].

The choice of appropriate systemic treatment for pNETs in MEN1 patients is currently consistent with the guidelines for sporadic pancreatic neuroendocrine tumours. No studies are available

which would assess the efficacy of such therapies in MEN1 patients. There is a single retrospective study covering 20 MEN1 patients with pNETs measuring more than 2 cm who received an octreotide LAR therapy. 10% patients responded to the treatment, stability of the disorder was achieved in 80% patients, while 10% patients experienced a progression of the disease in the course of a follow-up period of 12 to 75 months [21].

SUMMARY

Pancreatic neuroendocrine tumours are the chief cause of disease-related mortality among MEN1 patients. The lesions are usually multifocal, they show a potential hormonal activity (mostly gastrinoma or insulinoma) and develop in patients at a younger age.

Patients diagnosed with MEN1 syndrome on the basis of clinical and/or genetic methods must undergo screening on an annual basis, preferably from the age of 10. Most clinical decisions regarding MEN1 patients are based on guidelines that follow from expert opinions and recommendations relevant for sporadic pNET, which is a source of numerous challenges in diagnosis and treatment.

References

1. Thakker RV, Newey PJ, Walls GV et al. Clinical practice guidelines for multiple endocrine neoplasia type 1 (MEN1). *J Clin Endocrinol Metab* 2012; 97: 2990-3011.
2. Yates CJ, Newey PJ, Thakker RV. Challenges and controversies in management of pancreatic neuroendocrine tumours in patients with MEN1. *Lancet Diabetes Endocrinol* 2015; 3(11): 895-905.
3. Gietka-Czernel M, Kozakowski J, Szczepańska E. Zespół mnogich nowotworów gruczołów dokrewnych typu 1 (MEN1). *Post N Med* 2017; XXX(12): 665-673.
4. Amin S, Kang Kim M. Islet Cell Tumors of the Pancreas. *Gastroenterol Clin North Am* 2016; 45(1): 83-100.
5. Kos-Kudła B, Rosiek V, Borowska M et al. Pancreatic neuroendocrine neoplasms – management guidelines (recommended by the Polish Network of Neuroendocrine Tumours). *Endokrynol Pol* 2017; 68(2): 169-197.
6. Ito T, Igarashi H, Uehara H et al. Causes of death and prognostic factors in multiple endocrine neoplasia type 1: a prospective study: comparison of 106 MEN1/Zollinger-Ellison syndrome patients with 1613 literature MEN1 patients with or without pancreatic endocrine tumors. *Medicine (Baltimore)* 2013; 92(3): 135-181.
7. Newey PJ, Jeyabalan J, Walls GV et al. Asymptomatic children with multiple endocrine neoplasia type mutations may harbor nonfunctioning pancreatic neuroendocrine tumors. *J Clin Endocrinol Metab* 2009; 94(10): 3640-3646.
8. Falconi M, Ericsson B, Kaltsas G et al. ENETS Consensus Guidelines Update for the Management of Patients with Functional Pancreatic Neuroendocrine Tumors and Non-Functional Pancreatic Neuroendocrine Tumors. *Neuroendocrinology* 2016; 103: 153-171.
9. de Laat JM, Pieterman CR, Weijmans M et al. Low accuracy of tumor markers for diagnosing pancreatic neuroendocrine tumors in multiple endocrine neoplasia type 1 patients. *J Clin Endocrinol Metab* 2013; 98(10): 4143-4151.
10. Qiu W, Christakis I, Silva A et al. Utility of chromogranin A, pancreatic polypeptide, glucagon and gastrin in the diagnosis and follow-up of pancreatic neuroendocrine tumours in multiple endocrine neoplasia type 1 patients. *Clin Endocrinol (Oxf)* 2016; 85(3): 400-407.
11. Oberg K, Modlin IM, De Herder W et al. Consensus on biomarkers for neuroendocrine tumour disease. *Lancet Oncol* 2015; 16(9): e435-e446.
12. Langer P, Kann PH, Fendrich V et al. Prospective evaluation of imaging procedures for the detection of pancreaticoduodenal endocrine tumors in patients with multiple endocrine neoplasia type 1. *World J Surg* 2004; 28(12): 1317-1322.
13. Camera L, Paoletta S, Mollica C et al. Screening of pancreaticoduodenal endocrine tumours in patients with MEN 1: multidetector-row computed tomography vs. endoscopic ultrasound. *Radiol Med* 2011; 116(4): 595-606.
14. Barbe C, Murat A, Dupas B. Magnetic resonance imaging versus endoscopic ultrasonography for the detection of pancreatic tumours in multiple endocrine neoplasia type 1. *Dig Liver Dis* 2012; 44(3): 228-234.

15. Harper S, Harrison B. First surgery for pancreatic neuroendocrine tumours in a patient with MEN1: enucleation versus disease-modifying surgery. *Clin Endocrinol (Oxf)* 2015; 83(5): 618-621.
16. Triponez F, Dosseh D, Goudet P et al. Epidemiology data on 108 MEN1 patients from the GTE with isolated nonfunctioning tumors of the pancreas. *Ann Surg* 2006; 243: 265-272.
17. Pai M, Habib N, Senturk H et al. Endoscopic ultrasound guided radiofrequency ablation, for pancreatic cystic neoplasms and neuroendocrine tumors. *World J Gastrointest Surg* 2015; 7(4): 52-59.
18. Lakhtakia S. Therapy of Pancreatic Neuroendocrine Tumors: Fine Needle Intervention including Ethanol and Radiofrequency Ablation. *Clin Endosc* 2017; 50(6): 546-551.
19. Dąbkowski K, Gajewska P, Walter K et al. Successful EUS-guided ethanol ablation of insulinoma, four-year follow-up. Case report and literature review. *Endokrynol Pol* 2017; 68(4): 472-479. DOI: 10.5603/EP.2017.0053.
20. Kos-Kudła B, Blicharz-Dorniak J, Strzelczyk J et al. Diagnostic and therapeutic guidelines for gastro-entero-pancreatic neuroendocrine neoplasms (recommended by the Polish Network of Neuroendocrine Tumours). *Endokrynol Pol* 2017; 68(2): 79-110.
21. Ramundo V, Del Prete M, Marotta V et al. Impact of long-acting octreotide in patients with early-stage MEN1-related duodeno-pancreatic neuroendocrine tumours. *Clin Endocrinol (Oxf)* 2014; 80(6): 850-865.

For non-commercial use only

Authors' contributions:

Natalia Rogozik: 40%; other Authors: 10%.

Conflict of interests:

None.

Financial support:

None.

Ethics:

The paper complies with the Helsinki Declaration, EU Directives and harmonized requirements for biomedical journals.