

Case report

A patient with lung cancer and increased right ventricular pressure – should all lung cancer patients be suspected of pulmonary embolism?

Katarzyna Styczkiewicz¹, Sabina Mędrek¹, Adam Adamowicz¹, Marek Styczkiewicz¹

¹ Department of Cardiology, Specialist Hospital in Brzozow, Subcarpathian
Oncological Center, Brzozow, Poland
Head of the Department: Marek Styczkiewicz, MD, PhD

For non-commercial use only

ABSTRACT

Lung cancer is associated with an increased risk of venous thromboembolism, including pulmonary embolism. In some situations, clinical deterioration in patients with lung cancer accompanied by elevated pressure in the right ventricle, usually measured by commonly used echocardiography, may support the diagnosis of pulmonary embolism. However, there are many other causes of increased pressure in the right ventricle in such patients, for example: progression of cancer, pre-existing lung diseases, surgical resection of pulmonary tissue, pneumotoxicity of radiotherapy or concomitant diseases of the left heart. The article presents 2 clinical cases of patients with lung cancer, in which elevated pressure in the right ventricle was resulted from other causes and accompanied the progression of cancer, despite the clinical picture suggesting a pulmonary embolism. Increased pressure in the right ventricle and usually associated pulmonary hypertension, significantly worsen already poor prognosis of patients with lung cancer. The differential diagnosis should, therefore, take into account the whole clinical picture, excluding venous thromboembolism as an important cause of pulmonary hypertension, but also take into account other potential factors to be able to make the right diagnosis and implement optimal treatment as early as possible.

Key words: lung cancer, pulmonary embolism, right ventricle pressure, pulmonary hypertension

Correspondence:

Katarzyna Styczkiewicz
Department of Cardiology, Specialist
Hospital in Brzozow, Subcarpathian
Oncological Center, Brzozow, Poland
36-200 Brzozów, Bielawskiego 18
phone: (+48 22) 430-79-42
e-mail: krachwal@interia.pl

Received:

26.09.2018

Accepted:

27.02.2019

DOI: 10.24292/01.OR.219270219

Copyright © Medical Education.

All rights reserved.

CASE 1.

A 68-year-old man with small-cell lung cancer was urgently qualified for systemic treatment due to rapid disease progression. Cardiac consultation was recommended due to increased dyspnea and symptoms of heart failure.

Medical history:

- chronic heart failure with preserved left ventricular ejection fraction – NYHA II
- grade 3 hypertension
- type 2 diabetes mellitus
- family history of liver cancer (sister)
- substance dependence: a 20-year history of tobacco smoking, a non-smoker for 10 years.

Physical examination:

- regular heart rate increased up to 105 beats per minute (bpm); no pathological murmurs; blood pressure increased up to 160/90 mmHg
- diminished right vesicular breath sounds over the lung fields on auscultation
- an enlarged lymph node with a diameter of about 1 cm in the right supraclavicular fossa
- minor edema of the lower legs
- body mass index (BMI) of 27 kg/m²
- ECOG 2 (Eastern Cooperative Oncology Group performance status).

Laboratory findings:

- Hematology: hemoglobin – 13 g/dl; hematocrit – 42%; leukocytes – 9.3 thousand/mm³; platelets – 263 thousand/mm³
- eGFR – 95 ml/min, sodium – 145 mmol/l, potassium – 4.8 mmol/l
- glucose – 93 mg%, ALT – 22 U/l, **↑BNP – 3400 pg/ml, ↑d-dimers 4.1 µg/ml**
- APTT – 27.6 s, INR – 1.0.

Imaging/additional tests:

- chest computed tomography (CT): a 49 x 56 x 60 mm tumor with an area of lysis located in the right lung. A pathological 32 x 24 mm nodal mass is located anteriorly from the trachea
- endobronchial ultrasound (EBUS) transbronchial biopsy: paratracheal lymph nodes 4R: cells of metastatic small cell lung cancer
- cancer stage: T4N2M0 (tumour-node-metastasis classification, TNM)

- echocardiography (fig. 1–3) was performed as part of consultation and showed an enlarged right ventricle (fig. 1), increased right ventricular pressure (fig. 2) and pathological lesions in the dilated pulmonary artery suggestive of pulmonary embolism (fig. 3)
- urgent CT angiography excluded pulmonary embolism and revealed infiltrative mass of the lung tumor, involving also the right pulmonary artery (fig. 4).

The patient was referred to the Department of Clinical Oncology for rescue chemotherapy – first cycle of CE (carboplatin/etoposide regimen). A follow-up echocardiography after a month showed a reduced size of the right ventricle and decline in velocity of the trans-tricuspid regurgitant flow (fig. 5, 6); chest CT showed a significant remission of the lesions (fig. 7).

FIGURE 1.

Transthoracic echocardiography. Right ventricular view. Visible enlargement of the right heart chambers.

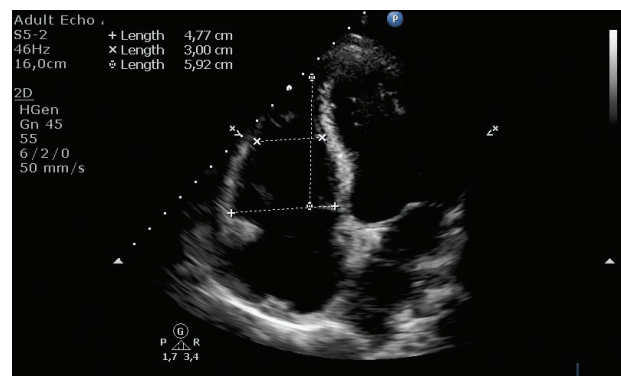


FIGURE 2.

Transthoracic echocardiography. Four-chamber view. Color and continuous Doppler examination. Doppler gate positioned at the level of the tricuspid valve shows increased gradient through the tricuspid valve to 69.2 mmHg. Maximum velocity of tricuspid regurgitant flow – 4.16 m/s – indicates a high risk of pulmonary hypertension.

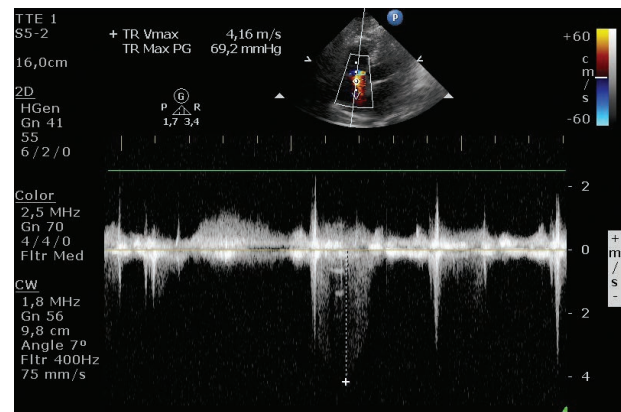


FIGURE 3.

Short-axis parasternal view. Slightly dilated pulmonary trunk with a pathological lesion at the site of division into pulmonary arteries.

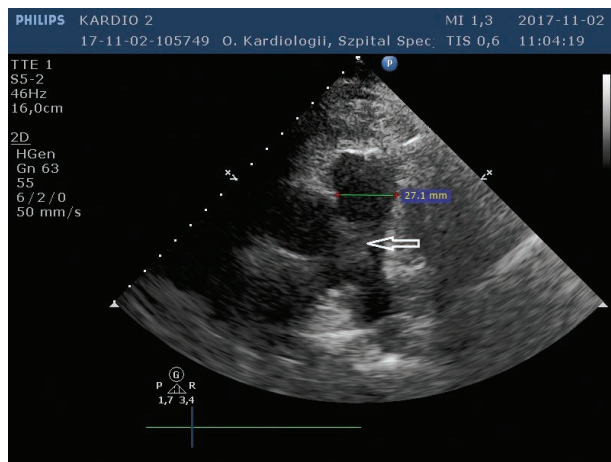


FIGURE 4.

Chest CT. The presented scan shows extensive infiltration of pulmonary parenchyma closing the right pulmonary artery.

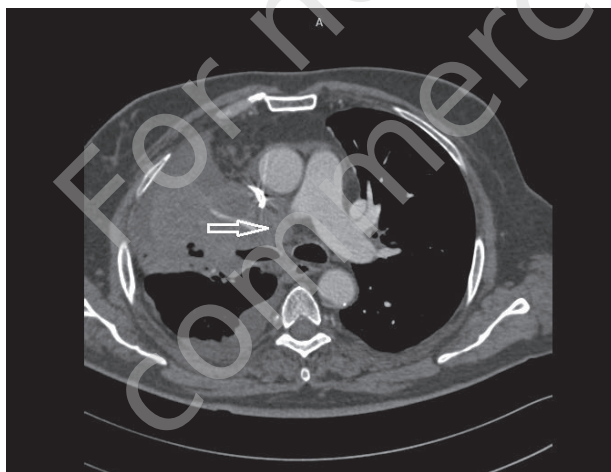


FIGURE 5.

Transthoracic echocardiography, four-chamber view. The patient after the first cycle of chemotherapy. The size of the right ventricle is visible reduced as compared to baseline examination (fig. 1).

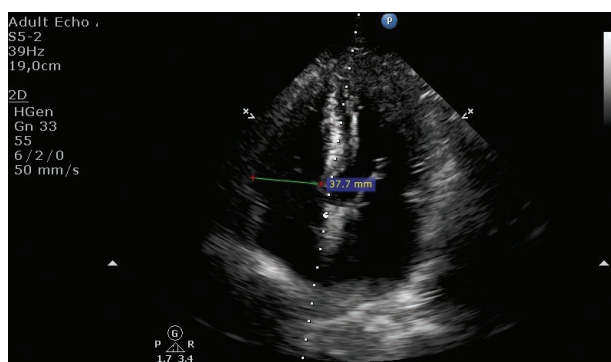


FIGURE 6.

Transthoracic echocardiography. Four-chamber view. Color and continuous Doppler examination. Doppler gate positioned at the level of the tricuspid valve shows significantly reduced trans-tricuspid gradient to 33.7 mmHg.

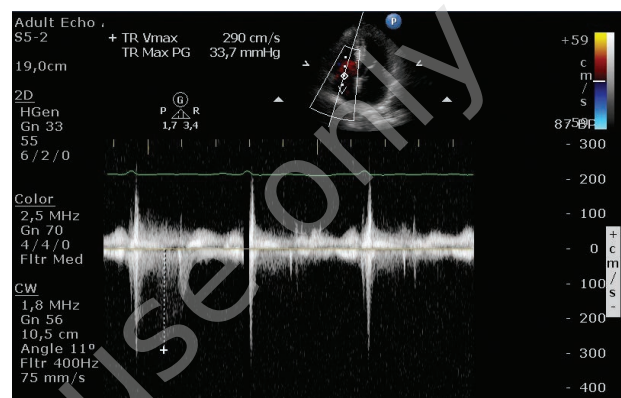
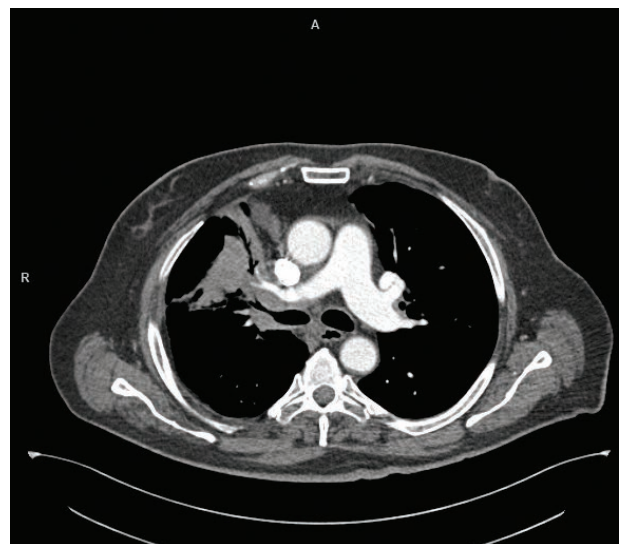

FIGURE 7.

Chest CT. The presented scan shows significantly reduced infiltration and contrast-enhanced right pulmonary artery lumen indicating restored patency.



CASE 2.

A 60-year-old man with large-cell neuroendocrine carcinoma of the right lung was hospitalized in the Department of Clinical Oncology to receive the first cycle of PE chemotherapy (cisplatin/etoposide regimen). Sudden deterioration of patient's condition with symptoms of increased dyspnea, fatigue and fever of up to 38°C, was observed after chemotherapy. The patient was referred for cardiac consultation.

Medical history:

- negative cardiac history
- family history of prostate cancer (brother and father)

- substance dependence – 40 years of tobacco smoking, a non-smoker for a month.

Physical examination:

- tachycardia 120 bpm, reduced blood pressure of 90/60 mmHg
- diminished right vesicular breath sounds over the lung fields on auscultation
- no peripheral edema
- BMI of 23 kg/m²
- ECOG 2.

Laboratory findings:

- Hematology: **↓hemoglobin – 9.1 g/dl**; **↓hematocrit – 32%**;
↓leukocytes – 19.2 thousand/mm³; **↓platelets – 23 thousand/mm³**
- ↑CRP 246 mg/dl** (24 mg/dl on the day before)
- ↑d-dimers 22 µg/dl** (9 µg/dl on the day before)
- troponin I – 0.012 ng/dl.

Imaging/additional tests:

- chest CT: a pathological mass about 55 x 39 mm in size in the right lung hilum. Fluid up to 20 mm in the right pleural cavity; cancer spread to the liver and bones
- histopathology: large-cell neuroendocrine carcinoma (chromogranin +, CD56 -, TTF-1 slightly positive, p63-)
- cancer stage: T4N2M1
- echocardiography was performed revealing: normal left ventricular contractility, enlarged right ventricle and right atrium with signs of overload (fig. 8, 9)
- urgent chest CT excluded embolism and showed neoplastic infiltrate with an area suspicious of an abscess (fig. 10).

FIGURE 8.

Transthoracic echocardiography. Four-chamber view. Enlarged right heart chambers, evident disproportion between the left and right heart.

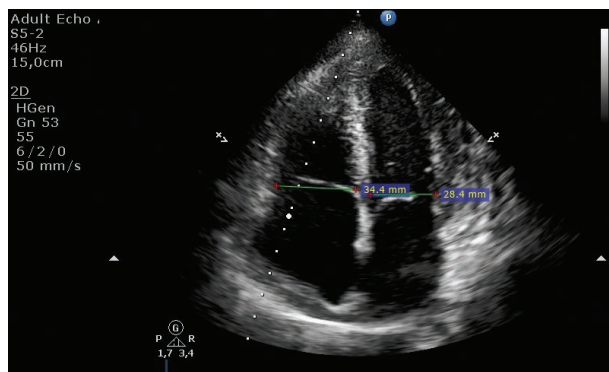


FIGURE 9.

Transthoracic echocardiography. Four-chamber view. Color and continuous Doppler examination. Doppler gate positioned at the level of the tricuspid valve shows increased gradient through tricuspid valve to 42.6 mmHg (flow velocity of 3.26 m/s indicates moderate risk of pulmonary hypertension).

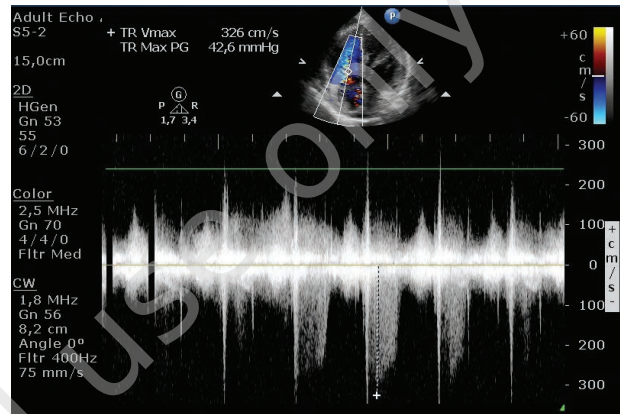
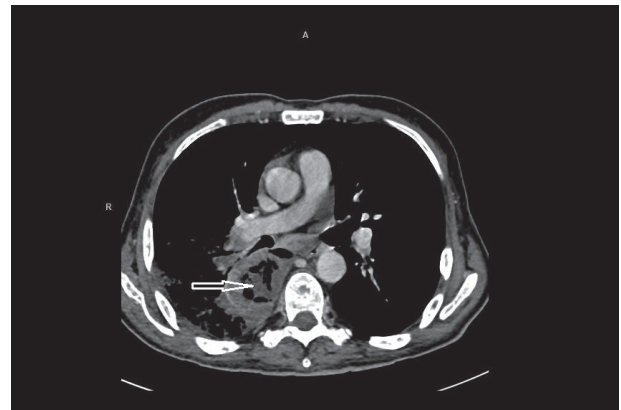

FIGURE 10.

Chest CT. Extensive infiltration with a non-homogeneous lesion probably corresponding to an abscess in the right paraspinal area.



There was rapid deterioration of patient's condition during further hospital stay. The patient received broad-spectrum antibiotic therapy due to suspected septic shock; blood cultures were negative. The patient died before further diagnosis could be made.

COMMENT

Lung cancer is diagnosed annually in about 15 000 men (standardized incidence rate: 50/100 000) and 6000 women (standardized incidence rate: 17/10 000) in Poland [1]. This type of malignancy is associated with a particularly increased risk of venous thromboembolism (VTE), including pulmonary embolism [2]. The risk of VTE is particularly increased in patients with

adenocarcinomas and non-small cell lung cancer compared to small cell lung cancer, and in patients receiving anti-angiogenic therapy. According to the diagnostic algorithm for pulmonary embolism recommended by the European Society of Cardiology [3], transthoracic echocardiography plays an important role in patients presenting with the symptoms of shock or hypotonia due to its wide availability if urgent CT cannot be performed. The presence of thrombi in the right heart or the pulmonary trunk indicates on pulmonary embolism. In the case of echocardiographic signs of overload and elevated right ventricular pressure, the concordance of clinical picture is decisive in making therapeutic decisions; however, other modalities should be used to visualize thrombi once the patient's condition stabilizes.

In the 2 described cases, the clinical picture, including sudden dyspnea in patients with advanced lung cancer, could imply pulmonary embolism as the potential cause of deterioration. Increased right ventricular pressure, which is often colloquially referred to as pulmonary hypertension (the latter one should be, however, verified in invasive pulmonary artery pressure measurements), did not result however from pulmonary embolism, but tumor progression in these patients.

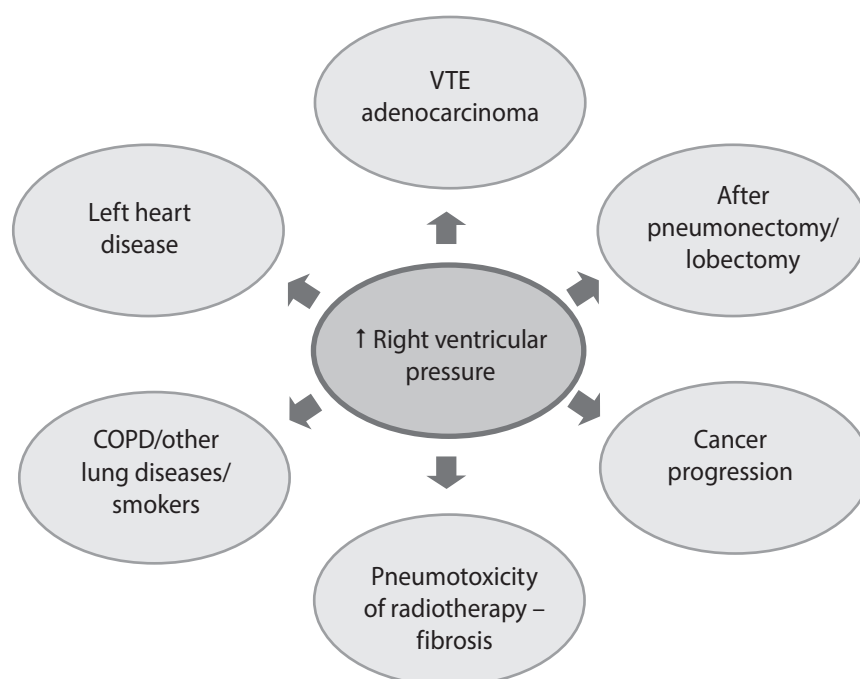
In addition to the above, there are many other reasons for increased right ventricular pressure in patients with lung cancer (fig. 11). First of all, it may result from a pre-existing lung disease, including smoking-related chronic obstructive pulmonary disease (COPD) in particular [4]. Changes in the pulmonary parenchyma, hypoxia and the consequent vascular remodeling lead to

increased vascular resistance, which in turn increases right ventricular pressure. The most common cardiac causes of increased right heart pressure include valvular diseases and left ventricular failure, the progression and stage of which are reflected by the development of pulmonary hypertension. Surgical treatment of lung cancer involving resection of pulmonary tissue may also increase pressure in the pulmonary artery and the right ventricle. The resection leads to right ventricular remodeling and enlargement as a result of redirecting the entire blood flow through the remaining pulmonary parenchyma, which increases vascular resistance [5]. It was documented that pulmonary hypertension and right ventricular overload are more common after pneumonectomy involving a larger portion of lung tissue rather than after lobectomy. Radiation therapy, either alone or in combination with chemotherapy, is another iatrogenic cause of increased right ventricular pressure. This type of treatment may lead to progressive lung fibrosis and, consequently, increased right cardiac overload and remodeling.

It should be noted that increased right ventricular pressure and the usually accompanying pulmonary hypertension, worsen the already poor prognosis in patients with lung cancer. Therefore, the differential diagnosis should include the whole clinical picture, excluding VTE as an important cause of increased right ventricular pressure, as well as considering other causes of pulmonary hypertension in order to be able to make the right diagnosis and implement optimal treatment as early as possible.

FIGURE 11.

Causes of increased right ventricular pressure in patients with lung cancer.



References

1. Krzakowski M. Nowotwory płuca, opłucnej i śródpiersia. W: Krzakowski M, Potemski P, Warzocha K, Wysocki P (ed). Onkologia kliniczna. Tom II. Via Medica 2015; 4: 523-571.
2. Vitale C, D'Amato M, Calabrò P et al. Venous thromboembolism and lung cancer: a review. Multidiscip Respir Med 2015; 10: 28. DOI: 10.1186/s40248-015-0021-4.
3. Konstantinides SV, Torbicki A, Agnelli G et al. 2014 ESC Guidelines on the diagnosis and management of acute pulmonary embolism: The Task Force for the Diagnosis and Management of Acute Pulmonary Embolism of the European Society of Cardiology (ESC). Endorsed by the European Respiratory Society (ERS). Eur Heart J 2014; 35(43): 3033-3069.
4. Seeger W, Adir Y, Barbera JA et al. Pulmonary hypertension in chronic lung diseases. J Am Coll Cardiol 2013; 62: D109-116.
5. Potaris K, Athanasiou A, Konstantinou M et al. Pulmonary hypertension after pneumonectomy for lung cancer. Asian Cardiovascular & Thoracic Annals 2014; 22: 1072-1079.

Authors' contributions:

All authors contributed significantly to the development of clinical cases, participated in the writing and approved the final version of the article

Conflict of interests:

None.

Financial support:

None.

Ethics:

The authors had full access to the data and take full responsibility for its integrity. All authors have read and agreed with the content of the manuscript as written. All authors declare no conflict of interest. This work has been carried out in accordance with The Code of Ethics of the World Medical Association (Declaration of Helsinki) for experiments involving humans.