


Follicular mucinosis on the forehead of a 15-year-old girl

Piotr Brzeziński, MD, PhD¹, prof. Anca Chiriac, MD, PhD^{2,3}

¹ Head of Military Ambulatory, 6th Military Support Unit, Ustka, Poland

² Dermato-Physiology Department, Apollonia University, Iasi, Romania

³ Department of Dermatology, Nicolina Medical Center, Iasi, Romania



Received: 31.12.2014. Accepted: 02.09.2015.

ABSTRACT

Follicular mucinosis is a rare dermatosis characterized by accumulation of mucin in the follicular epithelium and sebaceous glands. Clinically, it is characterized by the presence of papules or well-circumscribed and infiltrative plaques. In this paper, we report a case of a 15-year-old girl, in which an asymptomatic, erythematous and infiltrative plaque evolved within a few weeks in the forehead region. There was no regression of the lesion with the use of topical glucocorticosteroids and isotretinoinum for 30 days.

KEY WORDS: follicular mucinosis, lymphoma, skin diseases, alopecia mucinosa, paraneoplastic syndrome

Correspondence:

Piotr Brzeziński, MD, PhD
Head of Military Ambulatory, 6th Military Support Unit
Os. Ledowo 1N, 76-270 Ustka, Poland
tel.: (+48) 692-121-516
fax: (+48 59) 815-18-29
e-mail: brzezoo77@yahoo.com

INTRODUCTION

Alopecia mucinosa, often referred to as follicular mucinosis (FM), was first reported by Pinkus in 1957. The term follicular mucinosis was proposed by Jablonska in 1959.

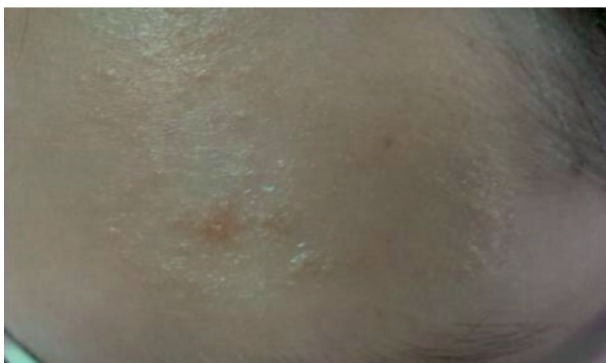FM is a reactive response, and 80% of its cases are linked to lymphocyte proliferation [1]. The presence of mucin in outer root sheath, sebaceous glands, and sometimes in the epidermis around hair follicle ostia is of secondary character, regardless of whether the condition is associated with a lymphoma or inflammatory infiltration [2].

We present a case of a 15-year-old girl with FM symptoms located on the forehead.

CASE PRESENTATION

A 15-year-old female patient presented to the dermatology clinic with a forehead lesion which had been gradually growing in size for several weeks. The patient complained about a mild pruritus of the lesion. The clinical picture demonstrated a slightly convex oedematous and erythematous spot lesion with rather sharp boundaries on the left side of the forehead. The skin lesion was partly covered by light adjacent scales (Fig. 1). Hair follicle ostia were reported as enlarged, and mucorrhea was observed under slight pressure, i.e. a discharge of viscous substance from the follicle ostia. The girl's mother failed to give her consent to the biopsy of the dermal lesion. Lab test results were within normal ranges.

FIGURE 1.
Follicular mucinosis with plugged hair follicles in a 15-year-old girl.



Basing on the clinical picture, the patient was diagnosed with follicular mucinosis. The treatment offered included strong topical corticosteroids once a day and isotretinoin

gel administered once a day for 2 months. Improvement of the skin lesions was observed already one month into the treatment, and on the following visit (one month later), the lesions receded completely, leaving a slight post-inflammatory discolouration.

DISCUSSION

The clinical picture of FM may often be atypical, which is why the diagnosis is frequently based on histopathological examinations. These, however, were not available in the above-mentioned case. Usually a single inflammatory focus is identified, with lesions most often located on the scalp or the hairy skin of the nape and shoulders [3]. Hair follicle ostia are frequently enlarged and sometimes filled with keratinized plugs. A viscous discharge from follicle ostia is often observed under light pressure. In medical practice, it is referred to as *mucorrhea* [4]. The condition usually involves hair loss, and it may escalate to the form of *alopecia mucinosa*. The lesions often cause pruritus.

The disease can be divided into idiopathic, inflammatory, and lymphoma-associated follicular mucinosis. It is assumed that if the condition affects children and young adults, it is most probably of a reactive or idiopathic character, while in older patients one has to consider the risk of an associated lymphoma [5, 6]. The lesions may recede after several weeks or even months. Cicatricial atrophy is not observed in the hairy regions. The condition is usually reactive, e.g. developing in the course of atopic dermatitis. If there are larger spot foci or nodules within the lesion, one should consider the possibility of an associated lymphoma.

Thus, FM can be classified as one of the paraneoplastic conditions [4]. The most common types of lymphoma involved include granuloma fungoides, Hodgkin lymphoma, and angioimmunoblastic lymphadenopathy. Co-existence of FM with lymphoproliferative diseases is well-documented, and its association with different types of granuloma fungoides is ever more frequent, affecting from 15 to 30% of the FM patients [7].

Lewars et al. described a case of a 5-year-old female patient with FM located on her back and trunk [1], treated with topical glucocorticosteroids with no desired therapeutic effect. Martin Peyra et al., on the other hand, presented a case of FM in a 16-year-old male [5]. His skin lesions, similarly to our patient, were located on the left side of the forehead,

closer to the eyebrow. A 3-year follow-up did not indicate evolution of the lesion into neoplastic disease.

It remains largely unclear whether reactive FM is a topical condition or one which is bound to evolve into lymphoma. There are no individual clinical or histological features which would make it easier to identify the population of patients with a benign course of disease. However, in patients diagnosed with granuloma fungoides, initial lesions have rarely been reported as located on the skin of the head or neck [1, 3].

Differential diagnostics involves exclusion of keloidal folliculitis, alopecia areata, and mycosis [8]. There is no standard management pertaining to the treatment of FM. Provided the patient has not been diagnosed with lymphoma, the treatment is limited to the administration of topical and general glucocorticosteroids, dapsone, tetracycline, mepacrine, isotretinoin or PUVA, with none of them having confirmed therapeutic efficacy, though [3, 9].

Despite the fact that in the case described, the disease affected a young patient, and was of reactive character, we are not released from responsibility of a long-term follow-up (even once the patient has been cured), as there have been cases of lymphomas evolving from FM lesions in children. FM patients must be informed about the necessity of further observation aimed at an early detection of secondary symptoms associated with neoplasia. Such a long-term follow-up is obligatory, and should cover the period of at least 5 years [7, 10], with some experts suggesting life-long control [11].

In our case, the decisive factor confirming the reactive nature of the condition was linked to the rapid regression of the lesion under the influence of topical glucocorticosteroids and isotretinoin as well as the lack of disease recurrence in 1-year follow-up.

Acknowledgements

Authors reports no conflict of interest.

References

1. Lewars M, Levin J, Purcell S. Follicular mucinosis. *Indian Dermatol Online J* 2013; 4: 333-335.
2. Puri N, Puri A. A clinical and histopathological study of cicatricial alopecia. *Our Dermatol Online* 2013; 4: 311-315.
3. Garrido MC, Riveiro-Falkenbach E, Rodriguez-Peralto JL. Primary cutaneous follicle center lymphoma with follicular mucinosis. *JAMA Dermatol* 2014; 150: 906-907.
4. Chamberlain RS, Blumgart LH. Mucobilia in association with a biliary cystadenocarcinoma of the caudate duct: a rare cause of malignant biliary obstruction. *HPB Surg* 2000; 11: 345-351.
5. Martin Peyra M, Gómez Vázquez M, Navarra Amayuelas R et al. [Facial follicular mucinosis in childhood]. *An Pediatr (Barc)* 2014; 81: 198-199.
6. Mir-Bonafé JM, Cañueto J, Fernández-López E et al. Follicular mucinosis associated with nonlymphoid skin conditions. *Am J Dermatopathol* 2014; 36: 705-709.
7. Passos PC, Zuchi MF, Fabre AB et al. Follicular mucinosis – case report. *An Bras Dermatol* 2014; 89: 337-339.
8. Kazlouskaya V, Lal K, Khaikova A. Lupus Tumidus: underreported variant of lupus erythematosus (a case report and review of the literature). *Our Dermatol Online* 2014; 5: 34-36.
9. Li W, Liu Y, Luo Q et al. Off-label uses of retinoids in dermatology. *Our Dermatol Online* 2012; 3: 259-278.
10. Brown HA, Gibson LE, Pujol RM et al. Primary follicular mucinosis: Long-term follow-up of patients younger than 40 years with and without clonal T-cell receptor gene rearrangement. *J Am Acad Dermatol* 2002; 47: 856-862.
11. Cervigón-González I, Manzanares FJ, Bahillo C et al. [Alopecia mucinosa]. *Actas Dermosifiliogr* 2006; 97: 514-517.

Authors' contributions:

Anca Chiriac – substantive corrections, compilation of references;
Piotr Brzeziński – preparation of the article and other materials.