

Patient with metastatic renal cell carcinoma treated successfully with pazopanib for four years

*Agnieszka Słowik, MD¹, Joanna Streb, MD¹, Robert Chrzan, MD, PhD²,
Krzysztof Krzemieniecki, MD, PhD¹*

¹ *Clinical Department of Oncology at the University Hospital in Krakow, Poland*

² *Department of Diagnostic Imaging at the University Hospital in Krakow, Poland*



Received: 15.06.2015. Accepted: 09.07.2015.

ABSTRACT

We present a case of a patient with metastatic renal cell carcinoma who was treated with pazopanib in the first-line treatment. Although nephrectomy was not performed, there was a positive reaction to the therapy with multi-targeted tyrosine kinase inhibitor. After 18 months of the palliative treatment, the cancerous kidney was surgically removed and pazopanib was restarted with the effect of further disease remission. The development of hypertension, complete hair discoloration and isolated hyperbilirubinemia occurred, and there was occasionally hypokalaemia in laboratory findings within 48 months of therapy. No serious adverse events were reported.

KEY WORDS: metastatic renal cell carcinoma, tyrosine kinase inhibitors, pazopanib

Correspondence:

Agnieszka Słowik, MD

Clinical Department of Oncology at the University Hospital in Krakow

31-531 Kraków, ul. Śniadeckich 10

tel.: (+48 12) 424-88-88

fax: (+48 12) 424-89-10

e-mail: agnesnew@wp.pl

INTRODUCTION

In Poland, kidney cancer incidence constitutes 3.9% of all malignant neoplasms in men and 2.7% in women [1]. In the structure of mortality from malignant tumors, deaths from renal cancer occur more often in male population and represent about 3% of all cases. Rates of both incidence and mortality from kidney cancer are rising, with incidence peak after 50 years of age [2]. In the case of local disease, the primary treatment comprises surgical resection of the tumor. At the end of the 20th century, standard treatment for metastatic disease was based on cytokines, interferon alfa and interleukin 2.

Nowadays, we have at our disposal 4 small molecule tyrosine kinase inhibitors connected with the VEGF (vascular endothelial growth factor) receptors – sunitinib, sorafenib, pazopanib, and axitinib and 2 inhibitors of the mTOR pathway (mammalian target of rapamycin) – temsirolimus and everolimus. From the antibodies available, only bevacizumab proved to be effective in the treatment of renal cell carcinoma [3, 4].

The first kinase inhibitor to be used in clinical practice in the first line treatment of advanced renal cell carcinoma was sunitinib [5]. The effectiveness of this drug was documented on large populations [6] and the effectiveness of the next lines treatment after progression during sunitinib treatment was examined in clinical trials [7-9]. A newer drug which also proved to be effective in the treatment of metastatic renal cell carcinoma is called pazopanib. In a randomized 3rd phase trial, the effectiveness of the new drug was shown with connection to a response rate (30% vs 3%) and progression-free survival (PFS 9.2 vs 4.2 months) when compared to placebo [10]. An indirect comparison of pazopanib with interferon alfa concerning overall survival was favorable for tyrosine kinase inhibitor (HR 0.512; 95% CI 0.326, 0.802) [11]. The overall survival is hard to estimate due to the fact that the cross-over procedure was allowed (54% patients from the placebo group were given pazopanib in the next line) [12,13].

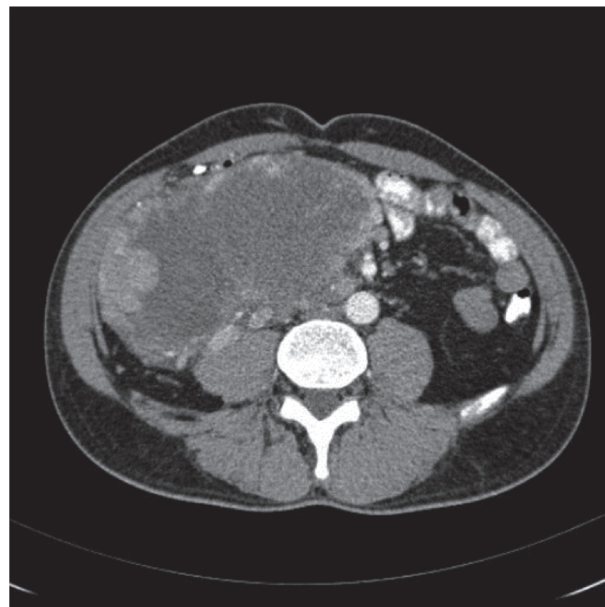The direct comparison of the two tyrosine kinase inhibitors mentioned above, conducted in the trial named COMPARZ, revealed similar effectiveness of those two drugs, with a difference in the area of toxicity profile. Fatigue, hand-foot syndrome and thrombocytopenia were observed more often in the sunitinib group and aminotransferases elevation was the problem in the pazopanib arm of the trial [14].

Below, we describe the case of a patient with advanced renal cell carcinoma, for whom we chose pazopanib as the first line treatment. A remarkable characteristic is his very long-lasting response to the therapy, at present amounting to 48 months, without progression of the malignant neoplasm, with a good tolerance of the multi-targeted kinase inhibitor.

CASE REPORT

A 41-year-old male diagnosed with clear cell renal cell carcinoma (ccRCC) of the right kidney with metastases in the lungs, liver, peritoneum and pleura was admitted to the Oncology Clinic of the University Hospital in Cracow in March 2011. The patient was previously diagnosed in relation to the left pleural effusion and subsequently hospitalized in the Thoracosurgical Clinic where thoracoscopy with evacuation of 3,700 ml of fluid was performed, followed by pleurodesis and collection of tissue samples for histopathological examination. The baseline CT scan revealed a big tumor in the right kidney, measuring 14 × 9 × 15.5 cm, which was strictly adjacent to peritoneum and liver, thereby causing relocation of the major abdominal vessels (Fig. 1).

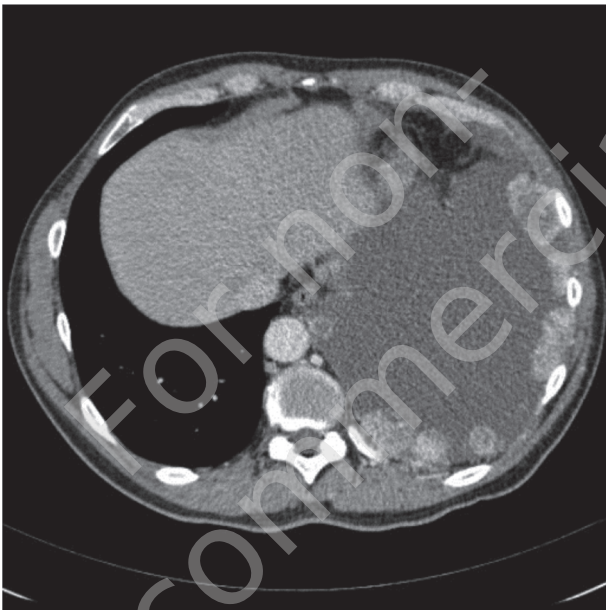
FIGURE 1.
CT scan of the abdominal cavity before treatment, March 2, 2011.



Cancerous masses were found in the renal vein. The liver was enlarged with a suspicious lesion. A neoplastic invasion into the peritoneum was present and measured

32 × 24 × 30 mm. A significant amount of fluid present in the thoracic cavity, constricting the lungs, and multiple metastatic spreads to the left pleura measuring up to 80 mm were visible. In the right lung, 4 metastatic lesions were present, the biggest measuring 30 × 27 mm, and multiple small nodules in the left lung were identified by the radiologist (Fig. 2). On the basis of the computer scan assessment, the baseline clinical staging using TNM criteria was evaluated as T4N0M1.

FIGURE 2.
CT scan of intrapleural invasions on the left side performed before the treatment.



The histopathological report on the sample collected from the pleura revealed partly necrotic tissue as well as tissue of the clear cell renal carcinoma, hence the diagnosis of RCC was reached as the most probable one.

Laboratory findings revealed the presence of hypoalbuminemia and elevated levels of: alanine transaminase, alkaline phosphatase, lactate dehydrogenase and a slightly elevated level of leukocytosis. Other blood test results were within normal limits.

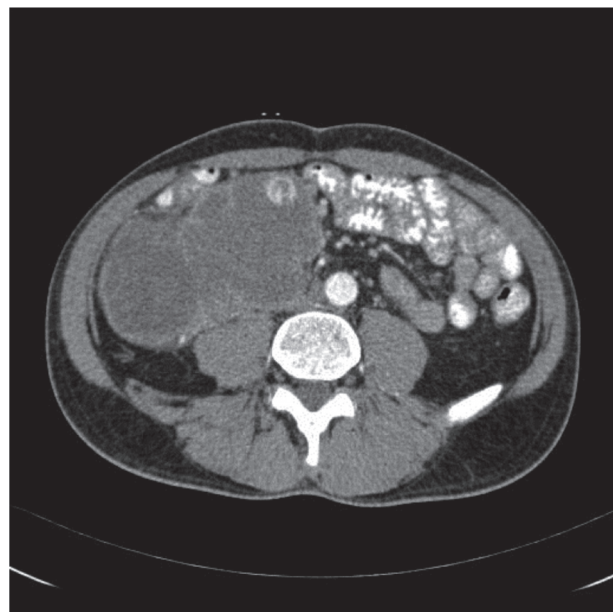
During his first visit in the University Hospital in Cracow, the patient was in a good overall condition. He complained about weakness. The initial dyspnea fully subsided after pleurodesis and there were no problems with breathing. The patient had no concomitant illnesses at that stage. His per-

formance status was evaluated according to Zubrod scale and assessed as PS = 1. In the physical examination, during palpation, there was a big tumor in the mesogastric area, expanding downwards over the median anterior line, reaching 3 cm above the right iliac bone.

In April 2011, treatment with pazopanib was started using free samples at a dose of 800 mg per day. During the first check-up, the patient felt subjectively better and the laboratory parameters which were previously inappropriate reached normal values.

In the follow-up CT scan performed after 3 series of treatment with pazopanib, a partial regression of the lesion in the kidney was described, with the reduction of the pressure on abdominal vessels (Fig. 3). In the chest, in the right lung, the nodules were smaller and lesions in the left lung were in complete remission. On the left, adjacently to mediastinum, a space filled with fluid was visible measuring 55 × 18 mm. The liver was described as not enlarged with regression of the hypodense lesion. Peritoneal mass was bigger, measuring 40 × 28 × 40 mm. According to the RECIST 1.1 criteria, the response to the oncological therapy was evaluated as SD (stable disease). At that stage the doctor applied for a non-standard treatment to the National Health Fund (NFZ, *Narodowy Fundusz Zdrowia*).

FIGURE 3.
CT scan of the abdominal cavity after 3 months of treatment with pazopanib, June 29, 2011.



After the NFZ gave its approval in July 2011, a 4-months treatment with pazopanib began. During the therapy, hypokalaemia and total hair discoloration were observed. In the subsequent follow-up CT scan of the abdomen and chest in September 2011, the kidney tumor had the same size. In the right lung, further remission of the lesions was observed and the tumor masses in the renal vein decreased. The amount of fluid in the left pleural cavity also diminished. Other cancerous lesions were described as stable.

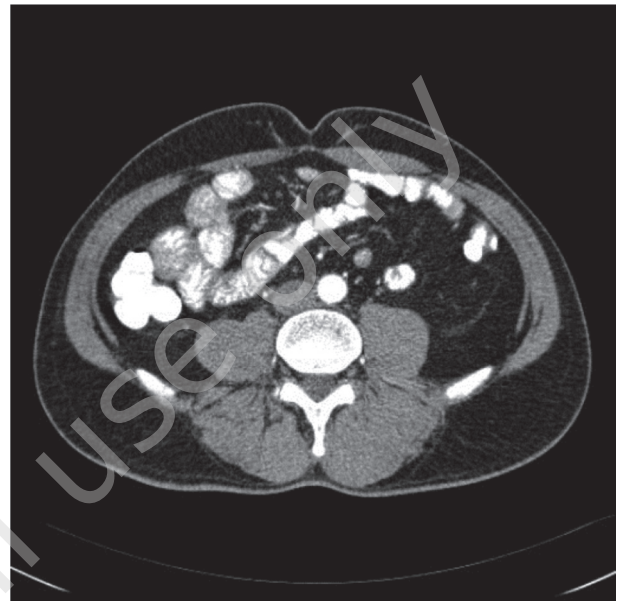Since the response to antiangiogenic treatment proved to be positive, the therapy was continued. After the 7th series of pazopanib, in November 2011, the patient complained about headache, which most probably resulted from undiagnosed hypertension. Since higher blood pressure was observed also at the check-up visit in the Oncology Clinic (the next measurement was 160/100 mmHg), the antihypertensive drug amlodipine at a dose of 10 mg was introduced as a routine treatment. Patient's blood pressure returned to an acceptable level.

In the next radiological examinations, in December 2011 and March 2012, stabilization of the disease was observed. The treatment was continued with no serious adverse events. During subsequent cycles, only higher level of bilirubin in the serum (up to 25.5 $\mu\text{mol/l}$) and hypokalaemia were reported.

As the patient's response to therapy was very good, he was consulted by the surgeon who proposed surgical treatment. In August 2012, right nephrectomy was performed with no medical complications. Histopathologically, the diagnosis of RCC was confirmed, Fuhrman grade G3/G4. In the post-operative CT scan, which was performed in November 2012, there was no right kidney, no masses in the right renal vein and no peritoneal mass (Fig. 4). The dimensions of the nodules in the right lung were smaller and the lesion in the liver was stable. In the same month, an application concerning continuation of pazopanib was filed to the NFZ. In December 2012, the treatment was restarted using the due dose of 800 mg per day (17th cycle). Until April 2013, 4 next series of antiangiogenic therapy were prescribed, which brought about a response in the thoracic cavity and a stabilization of other lesions. Intrapleural masses were described as calcified.

FIGURE 4.

CT scan of the abdominal cavity after the surgery, November 2012.



From the 22nd cycle, the treatment was continued as a part of the NFZ therapeutic program. In the CT scan performed in August 2013, there were no signs of local recurrence and the image of the abdomen showed stabilization. In the mediastinum, the fluid area subsided entirely. The treatment with pazopanib was prolonged for the next months. In June 2014, in the segment 10 of the left lung, the radiologist described an enlargement of the nodule which was defined as a vessel entity at previous examinations (Fig. 5). Using the RECIST 1.1 criteria, the response to the therapy did not fulfil the criteria of progression (the enlargement of the sum of metastatic lesions was below 20%). In the two subsequent radiological examinations (September and December 2014), there was no progression of the disease according to RECIST 1.1 criteria.

During the pazopanib treatment, after nephrectomy, hyperbilirubinemia (max. level: 42 $\mu\text{mol/l}$), hypokalaemia, occasionally slightly higher creatinine level (107–121 $\mu\text{mol/l}$) and lower glomerular filtration rate (GFR decreased to 52 ml/min/1.73 m²) were noted. Throughout the therapy, the patient had correct hepatic enzyme values (AST, ALT) and correct levels of hemoglobin, calcium and LDH. In October 2014, there was one episode of uncontrolled hypertension, which was most probably the consequence of the patient's non-compliance (discontinuation of the antihypertensive drug). Oncological treatment was never postponed because of adverse events.

FIGURE 5.
CT scan of intrapleural invasions after three years of treatment with pazopanib, June 2014.

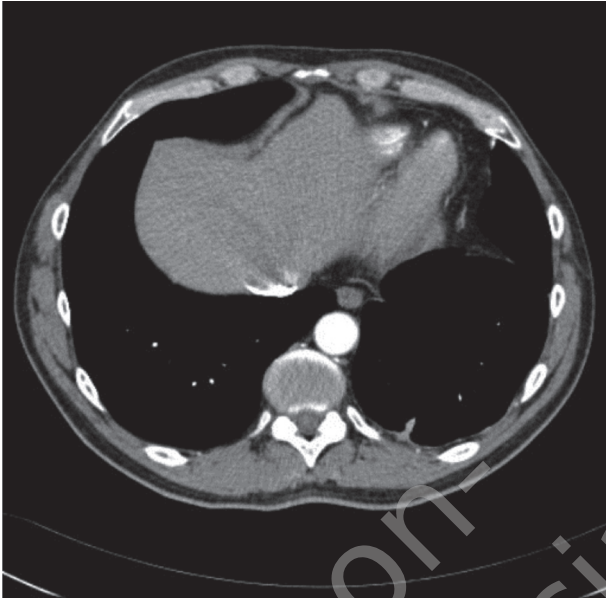
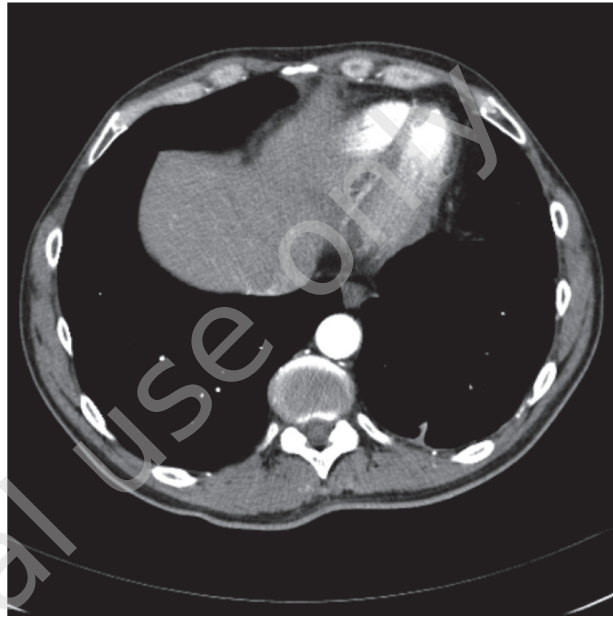


FIGURE 7.
Current CT scan of the chest at the level of initial intrapleural invasions.

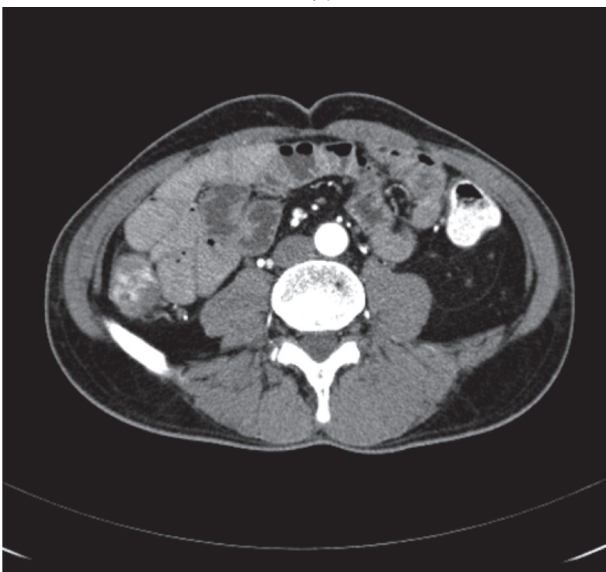

Until now the patient has received 42 cycles of pazopanib therapy without any serious complications, maintaining a very good life quality, with the actual performance status according to Zubrod scale PS = 0. He still continues the treatment as a part of the NFZ therapeutic program.

SUMMARY AND DISCUSSION

To assess individual overall survival of the patient with diagnosed advanced renal cell carcinoma, MSKCC criteria

FIGURE 6.
The last CT scan of the abdominal cavity performed.



(The Memorial Sloan-Kettering Cancer Center) are applied in clinical practice. On the basis of 19 years of observation, 5 prognostic factors have been isolated which divide patients with RCC into three prognostic groups. In the case of good prognosis (no risk factors), median overall survival reaches 20 months; in the case of intermediate group (1–2 risk factors), it amounts to 10 months and in the case of poor prognosis (> 2 risk factors) – 4 months. [15]. Some of the factors influencing the prognosis include the patient's performance status (< 80 in Karnofsky scale), corrected calcium level (> 10 mg/dl), low level of hemoglobin (< normal), high level of lactate dehydrogenase (LDH > 1,5 × normal limit) and no nephrectomy at the start of the treatment. However, newer criteria proposed by Cleveland Clinic Foundation (CCF) in 2005, apart from calcium level, hemoglobin and LDH, mention other risk factors, like metastases in the lungs, liver, retroperitoneal lymph nodes (in two or three locations) as well as the history of undergone radiotherapy [16]. Taking into consideration all these prognostic parameters (no nephrectomy before the treatment and the presence of multiple metastases, both in lymph nodes and solid organs), the above-mentioned patient may be classified under the intermediate risk group.

Since the beginning of the pazopanib treatment 48 months ago until now, there have been no visible signs of progression and no serious adverse reactions to the therapy. The only side effects include total hair discoloration, isolated hyperbilirubinemia and, occasionally, hypokalaemia. Development of

arterial hypertension was observed but it was successfully controlled by one drug, a third generation calcium blocker. Episodes of loss of control over arterial blood pressure were due to the patient's not taking the antihypertensive drug. None of the adverse events were associated with cessation of the therapy, nor did they result in the pazopanib reduction dose. Taking into consideration the tumor baseline staging and lack of nephrectomy before introducing the TKI in the present clinical case, worth noting is long progression-free survival and long overall survival achieved with only one drug in the first line setting of mRCC (metastatic renal cell carcinoma).

It has been shown that the effectiveness of TKI treatment in the first line may be a good prognostic factor. One of the trials assessing 119 patients with mRCC, after TKI or mTOR inhibitor used in the first line, showed a prognostic value of PFS time but failed to be predictive for the next line chemotherapies [17].

The influence of nephrectomy over further response to oncological therapy seems to be of great importance. In the case of interferon, clinical trials revealed that removal of the cancerous kidney is a reasonable step, ensuring a better response to the immunotherapy [18-20]. On the other hand, in the case of temsrolimus, inhibitor of mTOR pathway that is used in patients in the poor prognosis group, no difference in effectiveness in no-nephrectomy group was observed [21]. In a retrospective analysis, Richey et al. gathered patients receiving tyrosine kinase inhibitors in the first and next lines (86.7% and 76.6% respectively) and showed that long overall survival in the era of molecular treatment is not dependent of prior nephrectomy but is strictly connected to prognostic factors out of which three (PS, elevated LDH and hypercalcemia) are the same as MSKCC criteria and the next five parameters (retroperitoneal lymph node invasion, thrombocytosis, number of metastatic sites, smoking and lymphopenia) are new indicators but require prospective validation. However, it has to be taken into consideration that in this trial, only one patient received pazopanib as targeted treatment [22]. Thus, the question arises whether the results from the trials on patients receiving only some of the available TKIs (sunitinib, sorafenib) can also be applied in the case of patients undergoing treatment with pazopanib or axitinib.

When evaluating the importance of nephrectomy in the small molecule tyrosine kinase inhibitors, there are two trials

underway: CARMENA – multinational 3rd phase trial comparing results of the therapy with sunitinib after primary surgical excision of the kidney and without nephrectomy, and SURTIME – comparing the effects of preoperative treatment with sunitinib, with its continuation after surgery versus introducing sunitinib after palliative nephrectomy [23].

There are also 2nd phase trials underway which assess neoadjuvant pazopanib and axitinib in patients with no metastases (ClinicalTrials.gov identifiers NCT01512186 and NCT01263769). In the mRCC, the idea of neoadjuvant treatment has found its advocates [24]; however, skeptical papers have also been published [25].

In the case described, a long treatment with pazopanib, with the nephrectomy performed one year and a half after starting the treatment, seems to uphold the theory favoring the use of small molecule kinase inhibitors with the intention of further surgical treatment. Assessing the tumor behavior after the operation of primary tumor, in the CT scan of the patient in question, a further cancer remission was observed, which corresponds with the findings published [26-28]. One trial showed that in the group of patients where the treatment was postponed (delay group), which in 33% was caused by surgical resection, the median overall survival rate was 4.8 versus 18.9 months in the group in which TKI therapy was introduced without undue delay [27].

The clinical case presented demonstrates a huge anticancer potential of pazopanib with acceptable toxicity profile. When faced with the choice of the first line therapy in metastatic renal cell carcinoma, there are currently two options of oral multi-targeted kinase inhibitors in Poland: sunitinib and pazopanib. Varying toxicity profiles of those two drugs may help in only small part when making a decision about the most appropriate therapy. Sunitinib has been used in clinical practice for a longer time. However, treatment with pazopanib is an alternative, initially described in clinical trial as better tolerated and preferred by patients and oncologists [29]. In the future, when molecular markers of response to tyrosine kinase inhibitors will possibly become available, this difficult decision may be made on the basis of more objective predictive factors than nowadays [30, 31].

Acknowledgements

Authors report no conflict of interest.

References

1. Wojciechowska U, Didkowska J, Zatoński W. Nowotwory złośliwe w Polsce w 2010 roku. Warszawa 2012.
2. Srinivasan R, Rosner IL, Linehan WM. Renal cell carcinoma. In: Abraham J, Gulley JL, Allegra CJ et al. The Bethesda Handbook of Clinical Oncology. Lippincott Williams&Wilkins, Philadelphia 2010: 177-178.
3. Escudier B, Bellmunt J, Négrier S et al. Phase III Trial of Bevacizumab Plus Interferon Alfa-2a in Patients With Metastatic Renal Cell Carcinoma (AVOREN): Final Analysis of Overall Survival. *J Clin Oncol* 2010; 28: 2144-2150.
4. Escudier B, Pluzanska A, Koralewski P et al. Bevacizumab plus interferon alfa-2a for treatment of metastatic renal cell carcinoma: a randomised, double-blind phase III trial. *Lancet* 2007; 370: 2103-2111.
5. Sun M, Shariat SF, Trinh QD et al. An evidence-based guide to the selection of sequential therapies in metastatic renal cell carcinoma. *Ther Adv Urol* 2013; 5: 121-8.
6. Gore ME, Szczylik C, Porta C et al. Safety and efficacy of sunitinib for metastatic renal-cell carcinoma: an expanded-access trial. *Lancet Oncol* 2009; 10: 757-63.
7. Motzer RJ, Escudier B, Oudard S et al. Efficacy of everolimus in advanced renal cell carcinoma: a double-blind, randomised, placebo-controlled phase III trial. *Lancet* 2008; 372: 449-56.
8. Motzer RJ, Escudier B, Oudard S et al. Phase 3 trial of everolimus for metastatic renal cell carcinoma: final results and analysis of prognostic factors. *Cancer* 2010; 116: 4256-65.
9. Rini BI, Escudier B, Tomczak P et al. Comparative effectiveness of axitinib versus sorafenib in advanced renal cell carcinoma (AXIS): a randomized phase 3 trial. *Lancet* 2011; 378: 1931-39.
10. Sternberg CN, Davis ID, Mardiak J et al. Pazopanib in Locally Advanced or Metastatic Renal Cell Carcinoma: Results of a Randomized Phase III Trial. *J Clin Oncol* 2010; 28: 1061-8.
11. Kilonzo M, Hislop J, Elders A et al. Pazopanib for the first line treatment of patients with advanced and/or metastatic renal cell carcinoma: a NICE single technology appraisal. *Pharmacoeconomics* 2013; 31: 15-24.
12. Sternberg CN, Hawkins RE, Wagstaff J et al. A randomised, double-blind phase III study of pazopanib in patients with advanced and/or metastatic renal cell carcinoma: Final overall survival results and safety update. *Eur J Cancer* 2013; 49: 1287-96.
13. Nieto M, Borregaard J, Ersbøll J et al. The European Medicines Agency review of pazopanib for the treatment of advanced renal cell carcinoma: summary of the scientific assessment of the Committee for Medicinal Products for Human Use. *Clin Cancer Res* 2011; 17: 6608-14.
14. Motzer RJ, Huston TE, Cella D et al. Pazopanib versus sunitinib in metastatic renal-cell carcinoma. *N Engl J Med* 2013; 369: 722-31.
15. Motzer J, Mazumdar M, Bacik J et al. Survival and Prognostic Stratification of 670 Patients With Advanced Renal Cell Carcinoma. *J Clin Oncol* 1999; 17: 2530-2540.
16. Makhail TM, Abou-Jawde RM, Boumerhi G et al. Validation and extension of the Memorial Sloan-Kettering prognostic factors model for survival in patients with previously untreated metastatic renal cell carcinoma. *J Clin Oncol* 2005; 23: 832-841.
17. Seidel C, Busch J, Weikert S et al. Progression free survival of first line vascular endothelial growth factor-targeted therapy is an important prognostic parameter in patients with metastatic renal cell carcinoma. *Eur J Cancer* 2012; 48: 1023-30.
18. Flanigan RC, Salmon SE, Blumenstein BA et al. Nephrectomy followed by interferon alfa-2b compared with interferon alfa-2b alone for metastatic renal-cell cancer. *N Engl J Med* 2001; 345: 1655-1659.
19. Mickisch GH, Garin A, van Poppel H et al. Radical nephrectomy plus interferon-alfa-based immunotherapy compared with interferon alfa alone in metastatic renal-cell carcinoma: a randomised trial. *Lancet* 2001; 358: 966-970.
20. Flanigan RC, Mickisch G, Sylvester R et al. Cytoreductive nephrectomy in patients with metastatic renal cancer: a combined analysis. *J Urol* 2004; 171: 1071-1076.
21. Kwitkowski VE, Prowell TM, Ibrahim A et al. FDA approval summary: temsirolimus as treatment for advanced renal cell carcinoma. *Oncologist* 2010; 15: 428-435.
22. Richey SL, Culp SH, Jonasch E et al. Outcome of patients with metastatic renal cell carcinoma treated with targeted therapy without cytoreductive nephrectomy. *Ann Oncol* 2011; 22: 1048-53.

23. Bex A, Haanen J. Do targeted agents offer clinical benefit as presurgical therapy? *World J Urol* 2014; 32: 3-8.
24. Wood CG, Margulis V. Neoadjuvant (presurgical) therapy for renal cell carcinoma: a new treatment paradigm for locally advanced and metastatic disease. *Cancer* 2009; 115: 2355-2360.
25. Bex A, van der Veldt AA, Blank C et al. Neoadjuvant sunitinib for surgically complex advanced renal cell cancer of doubtful resectability: initial experience with downsizing to reconsider cytoreductive surgery. *World J Urol* 2009; 27: 553-9.
26. Aben KK, Heskamp S, Janssen-Heijnen ML et al. Better survival in patients with metastasized kidney cancer after nephrectomy: a population-based study in the Netherlands. *Eur J Cancer* 2011; 47: 2023-2032.
27. O'Malley RL, Brewer KA, Hayn MH et al. Impact of cytoreductive nephrectomy on eligibility for systemic treatment and effects on survival: are surgical complications or disease-related factors responsible? *Urology* 2011; 78: 595-600.
28. Choueiri TK, Xie W, Kollmannsberger C et al. The impact of cytoreductive nephrectomy on survival of patients with metastatic renal cell carcinoma receiving vascular endothelial growth factor targeted therapy. *J Urol* 2011; 185: 60-66.
29. Escudier B, Porta C, Bono P et al. Randomized, controlled, double-blind, cross-over trial assessing treatment preference for pazopanib versus sunitinib in patients with metastatic renal cell carcinoma: PISCES Study. *J Clin Oncol* 2014; 32: 1412-8.
30. Karam JA, Wood CG. Words of wisdom: re: prognostic or predictive plasma cytokines and angiogenic factors for patients treated with pazopanib for metastatic renal-cell cancer: a retrospective analysis of phase 2 and phase 3 trials. *Eur Urol* 2013; 63: 769.
31. Tran HT, Liu Y, Zurita AJ et al. Prognostic or predictive plasma cytokines and angiogenic factors for patients treated with pazopanib for metastatic renal-cell cancer: a retrospective analysis of phase 2 and phase 3 trials. *Lancet Oncol* 2012; 13: 827-37.

Authors' contributions:

Agnieszka Słowik – data collection, preparation of the article, translation;
Joanna Streb – preparation of the article, substantive consultation;
Robert Chrzan – figures compilation, substantive consultation;
Krzysztof Krzemieniecki – preparation of the article, substantive consultation.