


Treatment of multiple superficial basal cell carcinomas with topical imiquimod

Piotr Brzeziński, MD PhD¹, prof. Anca Chiriac, MD PhD²

¹ Head of Military Ambulatory, 6th Military Support Unit, Ustka, Poland

² Head of Department of Dermato-Physiology, Apollonia University Iasi, Romania



Received: 13.12.2014. Accepted: 26.01.2015.

ABSTRACT

Basal cell carcinoma is the most common malignancy of man. The use of the topical imiquimod 5% cream offers a noninvasive, nonsurgical, and an effective option for the treatment of primary types superficial basal cell carcinoma (sBCC). We present a case series of patients who used imiquimod 5% cream with good therapeutic effect. The medication had a good tolerability profile and there were no ocular adverse events. Imiquimod 5% cream could be considered the first choice treatment for BCCs in older patients who are poor candidates to surgery.

KEY WORDS: basal cell carcinoma (BCC), cryotherapy, imiquimod 5% cream

Correspondence:

Piotr Brzeziński, MD PhD
Military Ambulatory, 6th Military Support Unit
os. Ledowo 1N, 76-270 Ustka, Poland
tel.: (+48) 692-121-516
fax: (+48 59) 815-18-29
e-mail: brzezoo77@yahoo.com

INTRODUCTION

Basal cell carcinoma (BCC) is the most common type of facial skin cancer. It represents alone approximately 65% of all epitheliomas, and the incidence is 4-fold higher than that of squamous cell carcinoma [1].

Among predisposing factors, chronic exposure to the sun and/or to other types of ionising radiation plays a main role.

Other significant factors include immunosuppression, pre-existing cutaneous lesions and genetic conditions (e.g. albinism, xeroderma pigmentosum, and Gorlin-Goltz syndrome, Bazex syndrome), immunosuppressant settings such as AIDS and organ transplantation [2].

The reported annual incidence is approximately 65/100,000 individuals in Europe, 146/100,000 in the US and reaches 726/100,000 in Australia [3, 4].

The tumor may occur at any age, but higher frequency is noted in males and in older age, with a peak around the age of 70, 6, 7, 8. Nearly 80–85% of BCCs involve the head and neck regions and 25–30% are localized in the nasal area. Other frequently involved anatomical regions are the cheeks, the retroauricular area, the forehead, the periorbital area, and, in particular, the inner canthus [5].

DISCUSSION

Although it is described as a slowly growing tumor and metastases are extremely rare (< 0.1%), BCC may lead locally to considerable morbidity and complications, with particular reference to cases of recurrence following surgical excisions of primary lesions; recurrent cases of BCC tend to have a more aggressive progression [6].

The rates of recurrence after elimination appear to depend, to a large extent, on the anatomical localization, the histological characteristics, the initial treatment strategy and the eventual neoplastic margin involvement.

There are various methods for BCC treatment [6, 7]:

- cryotherapy
- curettage and electrodesiccation
- intralesional immunomodulatory agents (alpha interferon)
- photodynamic therapy
- radiotherapy
- surgical excision (classical, Mohs) (considered the gold standard treatment)
- topical chemotherapy (5% fluorouracil cream or solution)
- topical immunomodulatory agents (imiquimod 5% cream).

Five-year recurrence rates by treatment modality are as follows: Mohs micrographic surgery 1.0%, surgical excision 10.1%, curettage and electrodesiccation 7.7%, radiation therapy 8.7%, and cryosurgery 7.5% [1, 4]. The recurrence of basal cell carcinoma depends on the method of treatment and ranges between 4% and 18%.

Imiquimod 5% cream is licensed in the USA (FDA) and Europe (EMA) for the treatment of external genital warts, superficial basal cell carcinoma, and actinic keratoses [6, 8].

For superficial BCC the recommendation is to apply the 5% cream once daily, overnight, five times a week, for six weeks in a row [9].

Its mechanism of action relies on [9, 10]:

- binding to toll-like receptor 7 and 8 (TRL7 and TRL8) and on the release of pro-inflammatory cytokines including IFN- α , TNF- α and IL-12 and with the activation of cytotoxic functions of CD8⁺ cells
- inducing apoptosis
- binding to adenosine receptors (ADORAs) expressed in tumoral lesions and that could influence immune surveillance processes.

Advantages of topical cream therapy with imiquimod are [9, 11]:

- elderly patients, non-hospitalized, with multiple comorbidities and contra-indication for surgery
- complete cure rate varies, depending on studies, from 80% to 83%
- easy to perform, adapted to each person, good compliance from the patient and family member
- can be apply on large areas and in multiple locations
- the action of imiquimod is not limited to clinically evident lesions, but also on close proximity supporting the concept of “field cancerization” (treatment of subclinical-early malignancies); this so called prophylactic effect was proved in actinic keratoses and BCC
- scar free healing
- cost effective treatment compared to photodynamic therapy.

Disadvantages:

- lack of histological control
- pain, pruritus and local inflammatory reactions observed in some patients
- risk of residual or/and recurrent tumoral lesion impossible to identify; close follow-up of the patient is mandatory

- unpredictable duration of treatment, adapted to each person, depending on age of the patient, location of lesion, depth of the tumor, other treatment associated, patient compliance
- adverse reactions on long term: vitiligo or vitiligo-like hypopigmentation associated with imiquimod treatment of condylomata acuminata, lichen planus
- a case of pulmonary embolism has been recently reported during topical treatment with imiquimod.

CONCLUSION

Imiquimod 5% cream could be considered the first choice treatment for BCCs in older patients who are poor candidates to surgery. In Figures 1–4 we present our results.

Acknowledgements:

Authors report no conflict of interest.

FIGURE 1.

Large ulcerated BCC on the left temporal area in a 72 year-old woman treated with imiquimod 5% cream daily application. A: before treatment; B: at 4 weeks interval; C: at 6 weeks interval.

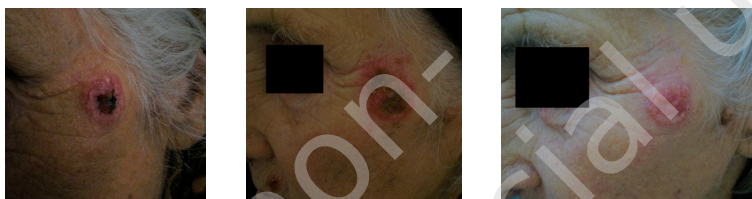

FIGURE 2.

Ulcerated BCC covered with hemorrhagic crust on the left nasal wing. A: before treatment; B: after 6 weeks of topical imiquimod 5% cream.

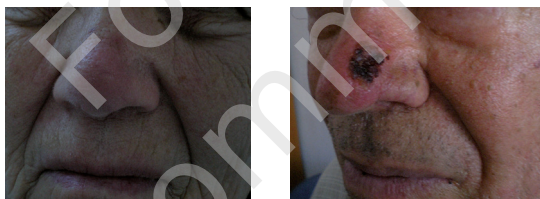

FIGURE 3.

Ulcerated BCC on the left temporal region in a 78 year-old man. A: local inflammatory reaction after 3 weeks of treatment; B: atrophic scar surrounded by erythema with imiquimod 5% cream in daily application at the end of 6 weeks of therapy.

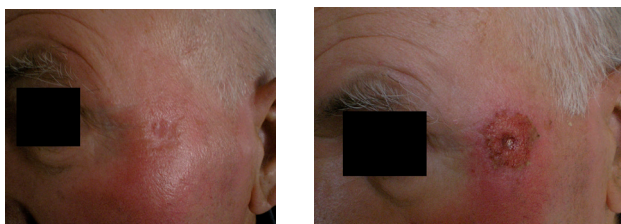
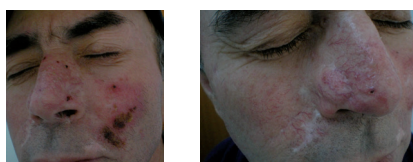

FIGURE 4.

A and B: Multiple crusts, atrophic scars, erythema, erosions, telangiectasia distributed on the nose and malar areas in a 57 year-old male patient diagnosed with multiple BCCs, treated previously by classic surgery and in present by topical imiquimod 5% cream.



References

1. Lopes Filho LL, Soares Lopes LR, Lima IP et al. [Frontal basal cell carcinoma with superciliar affection: surgical treatment with bilateral advancement flap]. *Surg Cosm Dermatol* 2009; 1: 103-104.
2. Hassan I, Abid K, Mashkoor A, Qazi M. Bazex syndrome – a case report. *N Dermatol Online* 2011; 2: 18-20.
3. Vikram KM, Pushpinder Sch, Karaninder SM, Vikas S. Favre-Racouchot Syndrome. *Our Dermatol Online* 2013; 4: 328-329.
4. Molina AL, Mejía M, Restrepo R. [Congenital and multiple basal cell carcinoma]. *Rev Asoc Colomb Dermatol* 2011; 19: 85-88.
5. Martínez Braga G, Riveros R, Di Martino Ortiz B et al. [Dermatoscopy: contribution as a method to define surgical margins in basal cell carcinomas of the face, neck and trunk]. *Our Dermatol Online* 2013; 4: 28-31.
6. Abdulaziz A., Brzezinski P., Chiriac A. Skin of sailor: Cutis rhomboidalis nuchae, actinic keratosis, squamous cell carcinoma and basal cell carcinoma. Case report. *OncoReview* 2014; 1: A36-A40.
7. Lezcano L, Di Martino Ortiz B, Rodriguez Masi M et al. [Bowen's disease treated with cryotherapy combined with topical 5% imiquimod. Alternative treatment to surgery in elderly patients with co-morbidities]. *N Dermatol Online* 2011; 2: 61-64.
8. Schmitt AR, Bordeaux JS. Solar keratoses: photodynamic therapy, cryotherapy, 5-fluorouracil, imiquimod, diclofenac, or what? Facts and controversies. *Clin Dermatol* 2013; 31: 712-717.
9. Schulze HJ, Cribier B, Requena L et al. Imiquimod 5% cream for the treatment of superficial basal cell carcinoma: results from a randomized vehicle-controlled phase III study in Europe. *Br J Dermatol* 2005; 152: 939-947.
10. Schön M, Bong AB, Drewniok C et al. Tumor-selective induction of apoptosis and the small-molecule immune response modifier imiquimod. *J Natl Cancer Inst* 2003; 95: 1138-1149.
11. Arits AH, Mosterd K, Essers BA et al. Photodynamic therapy versus topical imiquimod versus topical fluorouracil for treatment of superficial basal-cell carcinoma: a single blind, non-inferiority, randomised controlled trial. *Lancet Oncol* 2013; 14: 647-654.

Authors' contributions:

Piotr Brzeziński: preparing, references, analysis;
Anca Chiriac: idea, references, corrections, analysis.