

# Adriamycin cardiomyopathy with congestive heart failure, cardiogenic shock and emergency heart transplant: 30-year follow up

*Asma Mursleen, MD<sup>1</sup>, Eric E. Harrison, MD, Fellow of ACC, AHA, SCAI, ACP<sup>2</sup>*

<sup>1</sup> Saba University School of Medicine

<sup>2</sup> Morsani School of Medicine  
University of South Florida



Received: 02.03.2015. Accepted: 10.03.2015.

## ABSTRACT

Doxorubicin chemotherapeutic agent is widely utilized for many types of cancers since the late 1960s. Cardiomyopathy is a well-known side effect of doxorubicin often limiting its use. In many cases doxorubicin cardiomyopathy can lead to end stage cardiac failure requiring heart transplantation. The quality of life of heart transplant patients is exceptional with most patients being able to continue normal activities following recovery. There has been significant advancement in cardiac transplantation since it was first attempted in 1967 in Cape Town, South Africa. Drugs such as cyclosporine played an important role in preventing graft failure and prolonging patient survival. Cardiac transplant can extend a patients' life by over a decade. The patient in this case, Mr. Glen Frank Spurling, has survived 30 years following his cardiac transplant surgery. In this article an overview of doxorubicin cardiotoxicity, cardiac transplantation, and an interview with Mr. Glen Frank Spurling is presented.

**KEY WORDS:** heart transplantation, doxorubicin cardiomyopathy, heart transplant survivor

## Correspondence:

Eric E. Harrison, MD

e-mail: eeharrison253@hotmail.com

Asma Mursleen, MD

e-mail: asma.mursleen@gmail.com

## INTRODUCTION

Doxorubicin chemotherapeutic agent is widely utilized for diverse types of cancers. Doxorubicin-induced cardiomyopathy can result in terminal heart failure necessitating heart transplantation. The United Network of Organ Sharing database reported 453 heart transplants secondary to Adriamycin toxicity from 1987–2011 [14]. The median life expectancy of heart transplant patient is 11 years [1]. Heart transplantation is a life saving procedure that has come a long way since it was first attempted by Dr. Christiaan Barnard at the Groote Schuur Hospital in Cape Town, South Africa, in 1967. A significant milestone in transplant surgery was the discovery of immunosuppressant drugs such as cyclosporine, which considerably improved patient survival. Mr. Glen Frank Spurling, a patient who underwent heart transplant for doxorubicin cardiomyopathy following diagnoses of osteosarcoma, is exception to the rule. He is celebrating his 30-year heart transplant anniversary this year. This article provides an overview of doxorubicin cardiotoxicity, cardiac transplantation, and an interview with Mr. Glen Frank Spurling.

## CASE PRESENTATION

Glen Frank Spurling is a 79-year-old Caucasian married male from Alabama, who was an industrial engine salesman. His present illness began with the discovery of right lower leg pain with the diagnosis of an osteosarcoma for which the patient underwent a below knee amputation. He received an unknown amount of doxorubicin in 1978. Seven years following cure of his cancer, he developed left ventricular dysfunction, which progressed into cardiogenic shock. Patient was hospitalized in Lakeland Region Medical Center with vasopressors for hypotension, low cardiac output, and congestive heart failure.

Surgeons at Tampa General Hospital did the first surviving heart transplant June 6 1985 on a 42 year-old male. At age 43 Mr Spurling was transported to Tampa General Hospital in extremis and his has cardiac transplant on June 21, 1985 as Tampa General and Florida's second cardiac transplant, receiving a heart from a 20-year-old Ohio man who died in South Carolina.

Mr. Spurling sailed through recovery and appeared to have been a perfect match. He has been followed twice a year with echocardiogram, cardiac catheterization and endomyocardial biopsy. He has had so many biopsies that only scar tissue can be obtained from the area of the right ventricle to which the guiding catheter directs the biptome. Further biopsies can no longer be performed.

He has been plagued by chronic vasculopathies and has received multiple stents. He is currently asymptomatic but has a totally occluded left anterior descending and distal left circumflex (Figure 1). His left ventricular ejection fraction is entirely normal. His current medications include sirolimus, cyclosporine, clopidogrel, aspirin, saxagliptin, furosemide, lovastatin, lisinopril, pregabalin, potassium, novolog, insulin glargine, allopurinol, folic acid, iron, and vitamin D.

## DISCUSSION

Doxorubicin is an anthracycline anticancer drug, which can lead to progressive cardiomyopathy with poor prognosis. The drug cardiotoxicity can be acute or chronic. Acute cardiotoxicity can develop in 2–3 days and occurs in 11% of the patients taking this drug [2]. Chronic doxorubicin cardiotoxicity has a lower incidence of 1.7% and usually occurs within 30 days of administration of last dose but could occur up to 6–7 years later [2]. Patients who develop congestive heart failure secondary doxorubicin have 50% mortality in 1 year [2]. Patients with congestive heart failure are treated with aggressive medical management whereas some continue their downhill course and require cardiac transplantation.

Heart transplantation is a remarkable and life prolonging procedure which has been made possible by the contributions of many physicians over decades. The first successful human heart transplantation was performed in 1967 by Dr. Christiaan Barnard at the Groote Schuur Hospital in Cape Town, South Africa. The 55 year-old Louis Washkansky received the heart from 25 year-old Denise Darwall who died in an automobile accident. Louis Washkansky survived 18 days and died after developing bilateral pneumonia and severe septicemia. The success of the procedure was quite amazing; critical immunosuppression drugs used today were not available at the time. Moreover, the patient was also not an ideal candidate suffering from severe coronary insufficiency, diabetes and peripheral vascular disease, as well as was a cigarette smoker. Dr Barnard's second patient, Philip Blaiberg, survived a total of 19 months, and was the first transplant patient able to leave the hospital [3]. Of the first 10 heart transplant patients at Groote Schuur Hospital, two patients, Dorothy Fisher and Dirk Van Zyl, lived 13 and 23 years, respectively; again a very impressive feat considering the lack of development in immunosuppression drugs [4].

The second heart transplant in the world and first in the US was completed by Dr. Adrian Kantrowitz 3 days following Dr. Barnard's procedure at the Maimonides Medical Center in Brooklyn, NY. The surgical technique used in both these procedures

and still used today was developed by Dr. Norman Shumway who first successfully carried out a heart transplant in a dog at Stanford University in California 1958. Organ transplants in general are made possible due to the Alexis Carrel's work on vascular anastomosis for which he received a 1912 Nobel Prize in Medicine and Physiology [5].

One of the major limitations of heart transplantation surgery is the number of donors available. Potential solutions, such as total artificial heart transplants and xenotransplants, have been researched extensively with for some time now. In 1984 patient Barney Clark was the first ever recipient of a total artificial heart transplant which was permanently implanted by Dr. William DeVries, Dr. Willem S. Kolff, Dr. Robert K. Harvik and colleagues at University of Utah in Salt Lake City. The patient experienced many complications and survived almost 4 months following a difficult post-operative course [3]. Currently the SynCardia Total Artificial Heart is FDA approved for bridging to heart transplant and has recently been approved for destination therapy in a clinical study of 19 patient who are not eligible for a donor heart transplant [13].

Dr. Leonard Bailey transplanted a baboon heart into a 12 days old girl suffering from hypoplastic left heart syndrome in 1984. The patient survived a total of 20 days [6]. The median age of survival of heart transplantation patient today is between 10–11 years [1]. However in the early 1970s, only about 30% of the patients survived to 2 years [5]. A landmark discovery significantly contributing to prolonged survival of transplant patients was the immunosuppressant drug cyclosporine from soil fungus in the mid 1970s. In 1974 the 1 year, 2 year and 3 year survival is 43%, 40%, 26%, respectively [5]. In the mid 1980s when cyclosporine was being used clinically and the 1 year, 2 year, 3 year survival improved to 63%, 56%, 52% respectively [5]. The one year survival for cardiac transplant now is greater than 90% [7].

Cyclosporin inhibits the transcription of IL2 receptors and suppresses T lymphocyte growth and differentiation. One of the major side effects of this immunosuppressant drug is nephrotoxicity. Approximately 10% of transplants patients develop stage 4 kidney failure secondary to cyclosporine maintenance therapy [7]. Strategies used to minimize toxicity of cyclosporine include delaying its use post-operatively and using combination of immunosuppressive agents, requiring lower doses of each medication. Although immunosuppressive medications such as cyclosporine did prolong survival; the current median survival at 12 years is only 50% [8]. A big challenge in transplant surgery is the balance between preventing rejection versus avoiding infec-

tion. Immunosuppressive agents used to prevent rejection predispose patients to infection and cancer. In the first year following cardiac transplant 18% of deaths are due to acute rejection and 22% are due to infection. In fact the leading cause of death in the first year after heart transplantation is infection.

Major causes of death in patients who survive greater than 5 years include cardiac allograft vasculopathy (CAV) and cancer [1]. Transplant patient are at risk of both common infection and opportunistic infection such as CMV and *aspergillus fumigatus*. Patients on long-term immunosuppression are at the greatest risk for cutaneous malignancy but can also develop lymphoproliferative diseases and solid organ cancers [7]. Typically between 3–18% of heart transplant recipients develop cancer and 10–23% of patients die as a result of it [7]. The immunosuppressive medication OKT3 is responsible for an eight fold increase in the risk of lymphoma. Although skin tumors have a benign course, solid tumors and lymphomas carry a very poor prognosis [2].

Cardiac allograft vasculopathy is the leading cause of late graft failure and is thought to be a combination of both immune and traditional cardiovascular risk factors [7]. Histological presentations of CAV differ from typical CAD and usually present as diffuse fibroproliferative concentric and longitudinal narrowing of coronary arteries. Typical CAD presents as focal disease with eccentric narrowing. During the initial stages of CAV coronary artery walls undergo thickening followed by slow luminal narrowing as the disease progresses. Initial coronary intimal proliferation is seen in more than 80% of the transplant patient in the first year [9]. Greater than 50% of the patients develop advanced CAV 10 years following transplant [1]. Early CAV is associated with poor clinical outcomes and indicates aggressive disease, both extent and rate of CAV progression are significant in disease outcomes [1]. Typical atherosclerotic risk factors, such as diabetes, obesity, hypertension & smoking, lead to typical coronary artery disease compounding CAV. Heart transplant patients lack of cardiac muscle and do not experience angina, unless the nerves regenerate but can present with heart failure, arrhythmias or sudden death. This makes annual screening for developments and progression of CAV critical. Currently the standard method of screening accepted by most centers includes invasive coronary angiography (ICA) and transthoracic echocardiogram to evaluate cardiac function. Although ICA provides good prognostic data, it is an invasive technique that exposes the patient to radiation, contrast and compounds the risk of kidney injury in transplant patients taking immunosuppressive medications such as cyclosporine. ICA is also unable to detect changes in coronary artery walls and underestimates the degree of CVA.

Intravascular ultrasound (IVUS) and optical coherence tomography (OCT) are the most sensitive tool for detecting CAV and allows for the detecting of initial thickening, as well as luminal narrowing. However, IVUS uses higher radiation dose and contrast volumes compared to ICA alone. The size of catheters used with IVUS cannot image small caliber vasculature, and intimal proliferation of larger vessels on IVUS does not always correlate with histologic or immunohistochemical analysis of small-artery disease. Non-invasive techniques have limited sensitivity and specificity for detection of CAV and therefore are not utilized clinically. Nonetheless ongoing improvements in non-invasive methods could make them potential screening tools in the near future.

Advancements in cardiac CT allow for assessment of coronary arteries and cardiac function while requiring lower radiation and contrast. Cardiac CTA has high negative predictive value (96%) and can accurately exclude significant obstruction on CAV making it a potential tool for noninvasive screening in CAV [10]. Transplant patients typically have high resting heart rates, which could make it difficult to obtain good images secondary to limited temporal resolution. However, studies show good to excellent image quality can be obtained even with higher heart rates in transplant patients. This is likely due to decreased cardiac motion following sternotomy with scar tissue surrounding the allograft and lower heart rate variability due to heart denervation [10]. Currently, CTA can detect obstructive CAV with sensitivity of 86% and specificity of 89% [10]. Potentially higher specificity maybe acquired with coronary CT FFR Limitations of CCTA

similar to ICA include radiation and contrast, however CCTA procedures do require lower amount of contrast in comparison ICA. Excellent quality images from prospectively EKG-triggered dual source CT using model iterative reconstruction can require radiation doses at sub-millisievert levels. The current multi-slice and dual source CCTA can be evaluated proximal multiple coronary segments but are limited to arteries greater than 1.5 mm in diameter, so can not detect diffuse disease in medium and small vessels. Major advantage of CCTA over ICA is the possibility to detect CAV at earlier stages. This could help provide a greater understanding on the natural progression of CAV and the effectiveness of different treatment modalities on the disease process. Also with improving technology CCTA can be utilized as a potential noninvasive screening tool, which can be used decrease the number of periodic ICA required. Future research analyzing higher quality CCTA and FFR results compared with ICA, IVUS and OCT is required before the role of CCTA as a screening tool in CVA can be established.

## PATIENT INTERVIEW

The only thing Mr. Spurling clearly remembers is a poster with the date 06/21/1985 on the wall across from his hospital bed. Ms. Spurling on the other hand recalls everything, from the day she was told Frank wouldn't survive much longer without a heart transplant, to the surgery, and the following long and painful recovery.

"What people have wrong about (organ) transplants is the idea that everything is back to normal after surgery. But your life is changed forever", said Ms Spurling.

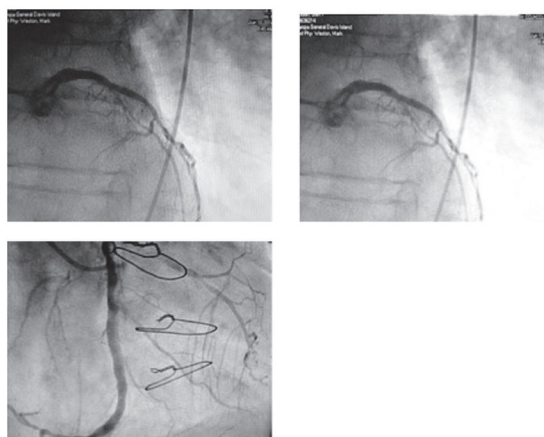
In August of 1977 Frank was diagnosed with left leg osteogenic sarcoma, which was treated with chemotherapy and below knee amputation. His chemotherapy regime included the drug adriamycin, which according to Frank, "disintegrated his heart".

Mr. Spurling was suffering from severe heart failure and his condition was deteriorating rapidly. At the time the nearest heart transplant center was in Birmingham, Alabama. However, Mr Spurling's cardiologist at the time, didn't think Frank would survive the trip.

Luckily, a new heart transplant program was being started at Tampa General, and Frank was listed number two for the procedure.

FIGURE 1.

Cardiac Catheterization. Patient has 100% severe stenosis of proximal left anterior descending and 100% stenosis of mid-left circumflex with collaterals from right coronary artery. There is also 50% stenosis of distal right coronary. The left ventricular ejection fraction is 50%, with no regional wall motion abnormalities.



"I remember looking out the hospital window and seeing a team of people coming with the new heart. I was truly really numb. I had been up so long and he was sick for so long, I was just praying I will get to see him again", said Ms Spurling.

This year is Frank's 30-year heart transplant anniversary, making him one of the longest heart transplant survivor in the world.

The recovery was long, "the best place to be was right next to him, less stressful for me and him, this is the way we lived for weeks", Ms Spurling recalled. Frank felt his whole body change when she spoke. He felt he was subconsciously aware of her presence.

Since the transplant in 1985 the Spurlings have travelled a rough road with their shares of ups and downs. The collection of immunosuppression drugs Frank takes to prevent rejection predisposes him to host of infections and cancers, most commonly skin cancer. Mr. Spurling feels every infection, every bump in the road could be his last, leading to his death. However, every successful recovery makes Mr. Spurling even more grateful to be alive to experience another day and be thankful to the donor.

Mr. Spurling doesn't feel there is a word to express how deeply thankful he is to the donor for giving him the gift of life and giving him the chance to do what he always wanted to but didn't

have the time to do. The donor was a young man who died in a head-on automobile collision. Frank was able to get in touch with the donor's family and had an opportunity to express his gratitude to the donor's fiancé and mother.

"If your gonna do something, do it today", is the motto Frank lives by. He can't sit down and do nothing; he has to be constantly moving. Frank feels blessed to just be able to think, walk and function every day.

## CONCLUSION

It is increasingly important to understand doxorubicin-induced cardiomyopathy and its treatment options as the number of cancer survivors increase worldwide. End-stage heart failure secondary to doxorubicin toxicity often requires heart transplantation. The average life expectancy following heart transplantation has significantly improved since the procedure was first attempted in 1967. Although cardiac transplant patients can live as long as a decade, Mr Spurling is a unique case surviving 30 years post-transplant.

## Acknowledgements

Authors report no conflict of interest.

## References

1. Davis MK, Hunt SA. State of the art: Cardiac transplantation. Trends in cardiovascular medicine 2014; 24(8): 341-349.
2. Chatterjee K, Zhang J, Honbo N, Karliner JS. Doxorubicin cardiomyopathy. Cardiology 2010; 115(2): 155.
3. Weisse AB. Cardiac surgery: a century of progress. Texas Heart Institute Journal 2011; 38(5): 486.
4. Brink JG, Hassoulas J. The first human heart transplant and further advances in cardiac transplantation at Groote Schuur Hospital and the University of Cape Town With reference to: The operation. A human cardiac transplant: an interim report of a successful operation performed at Groote Schuur Hospital, Cape Town: historical review article. Cardiovascular journal of Africa 2009; 20(1): 30-35.
5. DiBardino DJ. The history and development of cardiac transplantation. Texas Heart Institute Journal 1999; 26(3): 198.
6. De Salvatore S, Segreto A, Chiusaroli A et al. The Role of Xenotransplantation in Cardiac Transplantation. Journal of cardiac surgery 2015; 30(1): 111-116.
7. Alraies MC, Eckman P. Adult heart transplant: indications and outcomes. Journal of thoracic disease 2014; 6(8): 1120.
8. Taylor DO, Edwards LB, Boucek MM et al. Registry of the International Society for Heart and Lung Transplantation: twenty-fourth official adult heart transplant report – 2007. The Journal of heart and lung transplantation 2007; 26(8): 769-781.
9. Pollack A, Nazif T, Mancini D, Weisz G. Detection and imaging of cardiac allograft vasculopathy. JACC: Cardiovascular Imaging 2013; 6(5): 613-623.



10. Ferencik M, Brady TJ, Hoffmann U. Computed tomography imaging of cardiac allograft vasculopathy. *Journal of cardiovascular computed tomography* 2012; 6(4): 223-231.
11. Yagdi T, Sharples L, Tsui S et al. Malignancy after Heart Transplantation: Analysis of 24-Year Experience at a Single Center. *Journal of cardiac surgery* 2009; 24(5): 572-579.
12. Pollack A, Nazif T, Mancini D, Weisz G. Detection and imaging of cardiac allograft vasculopathy. *JACC: Cardiovascular Imaging* 2013; 6(5): 613-623.
13. FDA Approves the SynCardia Total Artificial Heart for Destination Therapy Study. [(2015, January 6). Retrieved March 2, 2015, from <http://www.syncardia.com/2015-multimedia-releases/fda-approves-the-syncardia-total-artificial-heart-for-destination-therapy-study/itemid-1737.html>].
14. Lenneman AJ, Wang L, Wigger M et al. Heart Transplant Survival Outcomes for Adriamycin Dilated Cardiomyopathy. *The American Journal of Cardiology* 2013; 111(4): 609-612.

**Authors' contributions:**

Both authors equally contributed to idea & design of the article, clinical data collection, analysis of the data and writing the manuscript.