

Nuclear medicine diagnostic tools for early detection of myocardial damage in treated breast cancer patients

*Antonia Tzonevska, MD PhD¹, Krasimir Tzvetkov, MD²,
Mariana Atanasova, MD³, Anna Chakarova, MD⁴*

*¹ Department of Nuclear Medicine, Specialized
Hospital for Active Treatment in Oncology, Sofia, Bulgaria*

*² Department of Functional Cardiovascular and Pulmonary Diagnostics, Specialized
Hospital for Active Treatment in Oncology, Sofia, Bulgaria*

*³ Chemotherapy Clinic, Specialized
Hospital for Active Treatment in Oncology, Sofia, Bulgaria*

⁴ Radiotherapy Clinic, Specialized Hospital for Active Treatment in Oncology, Sofia, Bulgaria



ABSTRACT

The most severe side effect in treated patients with breast cancer is treatment-induced cardiotoxicity, leading to chronic heart failure or CAD, and worsening the patient's quality of life. The early detection and medical protection is needed to prevent it. The aim of the study was to detect early signs of cardiotoxicity.

Material and methods: 148 breast cancer patients were included in the study: 64 after combined treatment (chemo- and radiotherapy), 56 patients after radiotherapy, 28 patients after chemotherapy. We performed myocardial scintigraphy (GSPECT-CT), EchoCG, proBNP measurement.

Results: The analysis of the results present early signs of cardiotoxicity in 46% of investigated patients. Exclusion criteria were: patients with cardiac symptoms, pathologic ECG and LVEF.

EchoCG results indicated normal systolic function in all (n = 120) patients (mean LVEF 64%), in 79 (66%) patients – normal diastolic function, in 41 (34%) patients diastolic dysfunction was found. Myocardial scintigraphy: normal systolic function was found in all patients (mean LVEF 68%), no segmental dysfunction, diastolic dysfunction had 47 (32%) patients. Hypoperfused myocardial segments were found in 39 (26%) patients. Normal myocardial perfusion had 125 (84%) patients. ProBNP: normal proBNP values were measured in 64 patients, increased values – in 7 (9%) patients.

Conclusion: The results indicated earlier detection of signs of cardiotoxicity in comparison to the routine diagnostic methods. Applying myocardial GSPECT-CT, we can detect early signs of myocardial damage before positive results from routine tests for cardiotoxicity and before severe morphologic myocardial damage.

KEY WORDS: treatment-induced cardiotoxicity, myocardial scintigraphy, GSPECT-CT

INTRODUCTION

In cancer therapy, the optimal treatment effect and quality of life must both be considered in development of treatment plan for individual patient. In two of major modalities for cancer therapy – radiation therapy and chemotherapy, the introduction of new techniques and treatment schedules in order to intensify the antitumor effect with a curative intent, may be associated with a higher risk for normal organs and normal tissues which may not only limit the effectiveness of the treatment but also have further implications to the quality of life of the patient. In the evaluation of organ toxicity from cancer therapy, both the early and late effects have to be considered. The first manifestations of injury are predominantly functional, and nuclear medicine techniques are particularly appropriate for monitoring function, enabling damage to be detected at an early stage before morphological alterations occur [1].

Although many acute side effects of cancer therapy have faded as critical issues, cardiotoxicity remains a relevant concern and necessitates careful ongoing clinical attention with high index of suspicion. Various antineoplastic agents can cause cardiotoxicity. Of them anthracyclines are the best recognized, though other chemotherapeutic and biologic agents are now known to have cardiac side effects [2].

Anthracyclines have been used in oncologic practice since the late 1960s. The tumors most commonly responding to doxorubicin include breast and esophageal carcinomas, osteosarcoma, soft-tissue sarcomas, Hodgkin's and non-Hodgkin's lymphomas. In a retrospective study of 399 patient records, cardiomyopathy (CMP) and congestive heart failure (CHF) were dose-dependent. Incidence rose to unacceptably high levels when the cumulative dose of the drug exceeded 550 mg per square meter of body-surface area. CHF developed in < 4% of patients who had received a cumulative dose of 500 to 550 mg of doxorubicin/m², < 18% at a dose of 551 to 600 mg/m² and to about 36% at a dose of 601 mg/m². An empirical dose limit of 500 mg/m² was suggested as a strategy to minimize the risk of cardiomyopathy, although CMP has been reported to develop at a cumulative dose of doxorubicin of less than 500 mg/m² [3].

Several risk factors that predispose patients to an increased risk of anthracycline-associated toxicity have been identified, from them the most important are: age > 65 years, mediastinal radiotherapy (previous or concomitant), previous cardiac disease (coronary, valvular, or myocardial), cardiac risk factors. The spectrum of cardiotoxicity ranges from myocarditis, pericarditis, myocardial infarction, sudden cardiac death to the most serious side effect – delayed-onset cardiomyopathy and congestive heart failure, which have poor clinical outcomes [4].

The pathogenesis of anthracycline-associated cardiac toxicity is known. The chemical structure of doxorubicin is prone to the generation of free radicals, and the oxidative stress that results correlates with cellular injury. Doxorubicin administration is associated with a decrease in the presence of the endogenous antioxidants responsible for the scavenging of free radicals [5]. A decrease in antioxidants and an increase in oxidants (free radicals) result in increased oxidative stress, leading to myocardial damage.

There is no ideal monitoring test for patients at high risk for cardiotoxicity [6–8]. The standard clinical approach to monitoring for doxorubicin cardiotoxicity: assessment of base-line cardiac performance before doxorubicin therapy begins, regular monitoring during treatment, and follow-up after therapy has been completed. The insidious nature of doxorubicin-induced CMP is best observed in the transient improvement in cardiac performance after the completion of therapy, followed by the development of full-blown CMP with CHF after years of latency [9, 10].

TABLE 1.
Diagnostic methods [11].

physical examination and history taking	lack of specificity
electrocardiography: arrhythmias, flattening of T-wave, prolongation of QT interval, decrease in R-wave voltage	lack of specificity
serial echocardiography and radionuclide ejection fraction	high reliability imaging: decrease in left ventricular wide use and availability
angiography with radiolabeled anti-myosin antibody for cell necrosis	high sensitivity low specificity
angiocardiography with metaiodobenzylguanidine – myocardial integrity and cardiac function	high sensitivity low specificity
endomyocardial biopsy	greatest reliability high expense

However, in patients with low-grade myocardial damage and no substantial changes in the ejection fraction at the completion of therapy, it is still possible that CHF with typical features of doxorubicin-induced cardiomyopathy will develop 4 to 20 years later [12].

Patients with cancer in whom symptoms of cardiomyopathy developed within the first year after doxorubicin therapy may have had an improvement in their condition during the first four years, but it subsequently deteriorated, and they died six to eight years

later. Endomyocardial biopsy is expensive, but it remains the most sensitive method for early diagnosis of ensuing cardiomyopathy. A change in the LVEF, as determined by echocardiography or radionuclide imaging, is a very good indicator of developing CMP, but is insufficient for detection of early signs of cardiotoxicity [13].

After radiation therapy of cancer, localized in the thorax, early and late cardiac injuries may be induced. Early manifestation of cardiac damage is pericarditis or myocarditis while the late injuries affect coronary arteries and myocardial capillaries and lead to ischemic heart disease. The late damage causes loss of capillaries, microvascular ischemia and progressive myocardial fibrosis which clinically manifests as valve dysfunction, coronary artery disease, myocardial infarction and sudden death years after radiotherapy. The incidence of late radiation-induced cardiac disease depends on the total irradiation dose, the combination of the two modalities – chemo and radiotherapy and the presence or absence of preexisting cardiac disease [14].

The main purpose of our research is to assess nuclear medicine diagnostic tools for early detection of treatment-induced cardiac damage in breast cancer patients.

MATERIAL AND METHODS

We included in our study 148 female breast cancer patients, stage I–II, mean age 53 ± 11 years. They passed the following procedures:

- anamnesis (n = 148)
- assessment of cardiac risk factors (n = 148)
- ECG (n = 148)
- echoCG (n = 120)
- myocardial GSPECT scintigraphy (n = 148)
- myocardial GSPECT-CT with CAC assessment (n = 28)
- proBNP measurement (n = 64).

The above described procedures are performed 6 months to one year after treatment. Exclusion criteria were: cardiac symptoms, pathologic ECG, deteriorated systolic function of LV.

Anamnesis

Detailed anamnesis and general and cardiologic status are obtained by the cardiologist. The risk factors are defined.

12-channel ECG

The ECG changes are non specific in cardiotoxicity but the ECG monitoring can be helpful. The decreasing of QRS voltage and St-T wave changes as a cardiotoxicity indicator is not specific and

is relatively late alteration, connected with severe and irresistible myocardial damage.

EchoCG [15–17]

Antracycline-induced heart failure (as a severe outcome of deteriorated cardiotoxicity) is a progressive clinical syndrome, characterized with altered left ventricular function and neurohormonal activation, often accompanied with fluid retention. The most commonly used method to recognize antracycline-induced heart failure is systolic dysfunction findings, caused by myocardial contractile deficiency, which leads to decrease of LV ejection fraction. If the LVEF decreases below 50%, the LV pressure is increased in the end diastole, which leads to an increase of pressure in the lung vessels and causes lung retention. The same increase of end diastolic pressure occurs during diastolic dysfunction, which precedes the systolic dysfunction in antracycline-induced cardiotoxicity. The diastolic dysfunction is characterized with normal systolic function, but decreased relaxation parameters of left ventricle, which leads to an increased end diastolic pressure and lung retention too, which means that the measurement of the end diastolic pressure is the most secure criterion for the early detection of antracycline-induced heart dysfunction but it is possible only after heart catheterization, which is invasive and not routinely used method. Currently, LVEF measurement is used to detect or exclude systolic dysfunction. However, LVEF is a relatively insensitive tool for detection anthracycline induced cardiotoxicity at an early stage. This is largely because no considerable change in systolic function occurs until a critical amount of morphological damage has been taken place. After this point deterioration proceeds rapidly and the prognosis is poor.

The heart systolic dysfunction can be recognized by LVEF monitoring. A normal value of $65\% \pm 5\%$ is accepted. Signs of heart failure are when LVEF falls below 45% or fall of 10% between two consequent measurements. The LVEF measurement are carried out when heart rate, body temperature are normal, haemoglobin is up of 9 g/dl – in circumstances diminishing false positive results. However LVEF is routinely used in practice to find cardiotoxicity, many clinical studies show that the results do not correlate to the endomyocardial biopsy – it has limited sensitivity for early detection of myocardial damage. Diastolic function parameters are more sensitive indicator. In EchoCG some diastole function parameters serve for cardiotoxicity assessment: left ventricular end diastolic diameter with normal mean value 47 mm, posterior wall diastolic thickness normal mean value 9 mm, early peak flow velocity/atrial peak flow velocity normal range 1.9, isovolumic relaxation time normal value 76 ms.

Gated SPECT myocardial scintigraphy (MS)

Images were obtained after intravenous injection of 600–740 MBq of ^{99m}Tc -Tetrofosmin 45–60 min after radionuclide administration on single detector gamma cameras Siemens or hybrid SPECT-CT Symbia T16 (Symbia T16, Siemens Medical Solutions USA, Inc.), using standard stress protocol. Gated images were acquired by using a 64×64 matrix, at 8 frames per R-R interval, using an R-wave window of $\pm 20\%$ of mean preacquisition heart rate. Heart rate data were recorded automatically in image files. Data were acquired for 30 sec. projection, for 45 projections per detector over a total arc of 180° , from the right anterior oblique- 45° projection to the left posterior oblique- 45° projection, with low-energy, high-resolution, parallel-hole collimators.

GSPECT-CT with CAC

Immediately after SPECT, CT acquisition was performed for attenuation correction and coronary calcium scores, and prospective ECG triggering was used and set at 42% of the R-R interval. Scans were made without the use of contrast agent, with 130 kV and 40 mA. A single collimation of 3,00 mm and an increment of 3,00 mm was applied. Total radiation exposure was 1 mSv for each patient. The coronary calcium score was obtained using the Agatston method [18] for assessment of coronary artery calcification (CAC).

Reconstruction

Gated ^{99m}Tc -Tetrofosmin SPECT was quantitatively analyzed with QGS/QPS software (QGS/QPS; Cedars-Sinai Medical Center, Los Angeles, CA, USA). QGS was used for calculating the end-diastolic volume (EDV), end-systolic volume (ESV), LVEF, functional maps, WT, WM, peak filling rate (PFR), one-third mean filling rate (MFR/3), time to PF (TTPF). Regional WM and WT were evaluated based on 17-segments of a polar map system, and summed function scores SMS, STS were calculated.

Visual analysis and QPS were used for evaluating the relative distribution of the myocardial perfusion. Processing and analysis were done to get the classic short axis, vertical long axis and horizontal long axis slices with application of the segment scoring system for semiquantitative analysis of the defect size to get summed stress score (SSS). The result was interpreted as: negative when SS: 0–3, mild (SSS > 3 and < 8), moderate (SSS \geq 8 and < 12), and severe (> 12).

CAC scores were calculated. CAC plaque documents the presence of atherosclerosis in an individual patient and high risk for

coronary events. In the literature the Agatston score is used to assess CAC, which measures the amount of calcium in each lesion. Total CAC is the sum of the scores of all the calcified lesions in all the vessels [18].

To avoid misinterpretation, all images were evaluated by 2 independent observers blinded to the patients clinical data.

ProBNP [14]

A new tool for the diagnosis and assessment of heart failure is the 32-amino acid polypeptide B-type natriuretic peptide (BNP). The synthesis of BNP occurs in the ventricles of the heart and the serum levels correlates with the severity of heart failure and with left (as well as right) ventricular pressures. Elevated BNP is found both in patients with diastolic dysfunction and those with systolic dysfunction, and the plasma level correlates with end ventricular diastolic pressure. Since the negative predictive value of BNP is as high as 98%, low BNP plasma levels make ventricular dysfunction unlikely and BNP might therefore a tool to screen for anthracycline-induced cardiotoxicity. Two small studies have evaluated the usefulness of BNP as a predictor of the risk of anthracycline-induced cardiotoxicity. Both have shown promising results and need to be confirmed.

RESULTS

All patients ($n = 148$) included in the study had no clinical cardiac signs, 82 patients had cardiac risk factors (hypertension, diabetes mellitus, age > 65 years, smoking), 64 patients had passed anthracycline-based therapy with cumulative dose > 550 mg/m² and radiotherapy, 28 patients passed only anthracycline-based chemotherapy, 56 patients passed only radiotherapy.

ECG: normal in all patients ($n = 148$).

EchoCG: Normal systolic function in all ($n = 120$) patients (mean LVEF 64%), in 79 (66%) patients normal diastolic function was found, in 41 (34%) patients diastolic dysfunction existed.

Myocardial scintigraphy: normal systolic function was found in all patients (mean LVEF 68%), no segmental dysfunction existed, diastolic dysfunction had 47 (32%) patients. Hypoperfused myocardial segments were found in 39 (26%) patients. Normal myocardial perfusion had 125 (84%) patients. CAC was measured in 28 patients who had more than 3 cardiac risk factors, 2 (14%) of them had increased value.

ProBNP: normal proBNP values were measured in 64 patients, increased values – in 7 (9%) patients (fig. 1).

FIGURE 1.

Breast cancer patient after anthracycline-based chemotherapy, with early signs of cardiotoxicity: normal myocardial perfusion, normal systolic function, diastolic dysfunction, CAC-0.

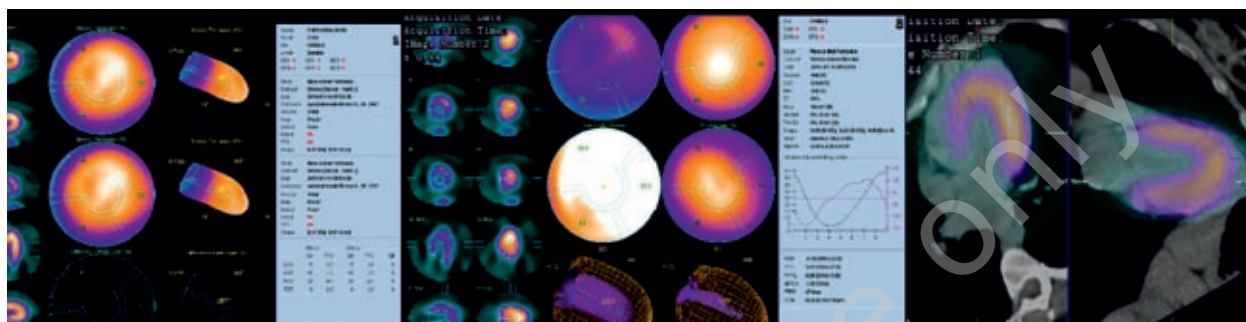
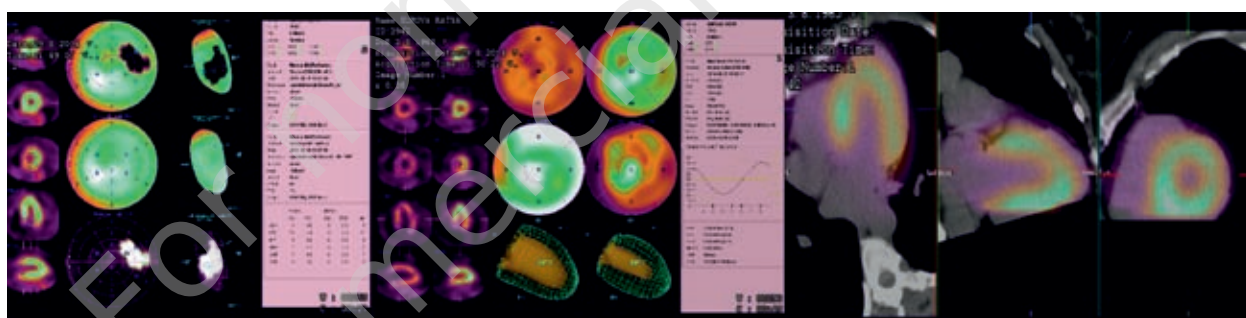


FIGURE 2.

Breast cancer patient past radiotherapy, with early signs of cardiotoxicity: hypoperfusion of anterior and anterolateral wall (SSS7, extent 9%), normal systolic and diastolic function, CAC-0.



DISCUSSION

Anthracyclines are well established as highly efficacious anti-neoplastic agents for various solid and hemopoietic tumors. The cardiotoxicity of these agents continues to limit their therapeutic potential and threaten the cardiac function of many patients with cancer. However, some of the newer agents that have recently enter the clinic also have been associated with cardiac conduction abnormalities that may require attention [19–21]. In a study included 1219 patients, treated with Herceptin ± chemotherapy, meta-analysis showed cardiac dysfunction as follows [19]:

- herceptin + AC: 27%
- herceptin + paclitaxel: 13%
- herceptin alone: 3–7%
- anthracycline: 8%
- paclitaxel: 1%

New diagnostic methods may provide more simple and effective means of detecting patients at risk at a time when changes in administration technique are still possible [22–24].

Although attempts have been made to monitor anthracycline cardiotoxicity with techniques such as ECG, LVEF (EchoCG), they have been virtually inapplicable because of their low sensitivity and specificity [14].

The disruption of mitochondrial energetics as a mechanism of cardiotoxicity has recently been explored using ⁹⁹Tc-SESTAMIBI, a lipophilic cation retained within mitochondria. Uptake and retention of the tracer were reduced in a dose- and time-dependent manner during exposure to different concentrations of doxorubicin, suggesting the induction of mitochondrial defects [14, 25].

When radiotherapy is performed in a study, in which patients had modern treatment planning based on computed tomography and pre-RT and serial post-RT GSPECT, myocardial perfusion is scanned to assess for changes in heart function. New perfusion defects occurred in 50% to 63% of women 6 to 24 months after RT [14].

The patients, included in our study suffered from breast cancer, treated with chemo- and/or radiotherapy. We followed up the pa-

tients for cardiotoxicity comparing the conventional tests (ECG, LVEF by EchoCG) with diagnostic methods, which are not used routinely in practice, but there are literature data that they can be used to detect early signs of myocardial damage: diastolic myocardial function, proBNP measurement, myocardial GSPECT scintigraphy, GSPECT-CT with CAC for simultaneous assessment of myocardial systolic and diastolic function, myocardial perfusion and CAC [14].

The analysis of our results present early signs of cardiotoxicity in 46% of investigated patients: diastolic dysfunction and/or myocardial hypoperfusion, and increased proBNP value. All of the patients have no cardiac symptoms. ECG is insensitive test for cardiotoxicity – all patients had normal ECG. LVEF, measured by EchoCG and MS is normal in all patients too. When compare results from EchoCG and MS in 120 patients we found diastolic dysfunction in 34% (EchoCG) and in 32% (MS) respectively. Diastolic dysfunction and myocardial hypoperfusion are considered as early signs of cardiotoxicity. Patients with increased CAC and myocardial hypoperfusion were defined as suffering from silent CAD and were classified as with high risk for cardiac damage if routine radiotherapy would be performed.

In a group of 64 breast cancer patients, performed chemo- and radiotherapy the results revealed that a highest percentage of patients had perfusion myocardial defects (42%) in comparison with myocardial diastolic dysfunction (33%) and also proBNP increasing values (9%). Alteration of myocardial cells and fibrosis

precede functional impairment and a certain critical mass of cell damage is needed before functional impairment can be detected [21]. The most likely explanation for our findings is microvascular damage to the myocardium caused by RT and anthracycline-induced myocardial cell damage.

In 28 patients, performed chemotherapy and having cardiac risk factors MS defined cardiotoxicity in 21%.

In a group of 56 patients, performed radiotherapy, the results defined cardiotoxicity in 19% patients, exclusively in left-sided breast cancer.

Only GSPECT-CT with CAC MS achieves complex assessment of myocardial systolic and diastolic function, myocardial perfusion and CAC, which gives possibility to check cardiotoxicity at an early stage and to define patients with high risk for cardiac damage.

The results from the study have to be confirmed in the studies with large number of investigated patients and larger period of follow up from 2 to 5 years after treatment.

CONCLUSION

Applying myocardial GSPECT-CT with CAC we can detect early signs of myocardial damage before positive results from routine tests for cardiotoxicity and before severe morphologic myocardial damage.

References

1. Chanan-Khan A, Srinivasan S, Czuczman M. Prevention and management of cardiotoxicity from antineoplastic therapy. *J Supp Onc* 2004; 2(3): 251-267.
2. Pai VB, Nahata MC. Cardiotoxicity of chemotherapeutic agents: incidence, treatment and prevention. *Drug saf* 2000; 22: 263-302.
3. Shan K, Lincoff M, Young JB. Anthracycline-Induced Cardiotoxicity. *Anal of internal medicine* 1996; 125: 147-158.
4. Butany J, Ahn E, Luk A. Drug-related cardiac pathology. *J Clin Pathol* 2009; 62: 1074-1084.
5. Pfeffer B, Tziros C, Katz RJ. Current Concepts of Anthracycline Cardiotoxicity: Pathogenesis, Diagnosis and Prevention. *Br J Cardiol* 2009; 16(2): 85-89.
6. Bonadonna G, Zambetti M, Valagussa P. Sequential or alternating doxorubicin and CMF regimens in breast cancer with more than three positive nodes. Ten-year results. *JAMA* 1996; 273: 542-547.
7. Berry G, Billingham M, Alderman E et al. The use of cardiac biopsy to demonstrate reduced cardiotoxicity in AIDS Kaposi's sarcoma patients treated with pegylated liposomal doxorubicin. *Annals of Oncology* 1998; 7(9): 711-716.
8. Fisher B, Redmond C, Wickerham DL et al. Doxorubicin-containing regimens for the treatment of stage II breast cancer: The National Surgical Adjuvant Breast and Bowel Project experience. *J Clin Oncol* 1989; 7: 572-82.
9. Haq MM, Legha SS, Choksi J et al. Doxorubicin-induced congestive heart failure in adults. *Cancer* 1985; 56: 1361-5.
10. Olson RD, Mushlin PS. Doxorubicin cardiotoxicity: analysis of prevailing hypotheses. *FASEB J* 1990; 4(13): 3076-86.
11. Lipshultz SE, Sanders SP, Colan SD et al. Monitoring for anthracycline cardiotoxicity. *Pediatrics* 1994; 93(3): 433-437.
12. Steinhert LJ, Steinhert PG, Tan CT et al. Cardiac toxicity 4 to 20 years after completing anthracycline therapy. *JAMA* 1991; 266: 1672-7.
13. Combs A, Acosta D. Toxic mechanisms of the heart: a review. *Toxicol Pathol* 1990; 18(4): 583-596.
14. Carrio IM, Ertorch A, Lopez-Pousa A. Assessing anthracycline cardiotoxicity in the 1990s. *Eur J Nucl Med* 1996; (23)4: 359-364.

15. Larsen RL, Jakacki RI, Vetter VL et al. Electrocardiographic changes and arrhythmias after cancer therapy in children and young adults. *Am J Cardiol* 1992; 70: 73-7.
16. Tjeerdema G, Meinardi M, Van der Graaf WTA et al. Early detection of anthracycline induced cardiotoxicity in asymptomatic patients with normal left ventricular systolic function: autonomic versus echocardiographic variables. *Heart* 1999; 81: 419-42.
17. Stoddard MF, Seeger J, Liddell NE et al. Prolongation of isovolumetric relaxation time as assessed by Doppler echocardiography predicts doxorubicin-induced systolic dysfunction in humans. *J Am Coll Cardiol* 1992; 20: 62-69.
18. Sharma R, Sharma K, Vibhuti D. et al. Cardiac risk stratification: role of the coronary calcium score. *Vasc Health Risk Manage* 2010; 6: 603-611.
19. Tham YL, Verani MS, Chang J. Reversible and irreversible cardiac dysfunction associated with trastuzumab in breast cancer. *Breast Cancer Res Treat* 2002; 74(2): 131-134.
20. Emily Ho E, Brown A, Barrett P et al. Subclinical anthracycline- and trastuzumab-induced cardiotoxicity in the long-term follow-up of asymptomatic breast cancer survivors: a speckle tracking echocardiographic study. *Heart* 2010; 96: 701-707.
21. Tomiak E, Piccart M, Mignolet F et al. Characterisation of complete responders to combination chemotherapy for advanced breast cancer: a retrospective EORTC breast group study. *Eur J Cancer* 1996; 32A: 1876-1887.
22. Olmas R, Hoefnagel C et al. Usefulness of ¹¹¹In-antimyosin in mapping anthracycline myocardial injury. *Update* 1995; 2(2): 44-45.
23. Valdés Olmos RA, ten Bokkel Huinink WW, ten Hoeve RF et al. Assessment of anthracycline related myocardial adrenergic derangement by ¹²³I- MIBG. *Eur J Cancer* 1995; 31A(1): 26-31.
24. Miyagawa M, Tanada S, Hamamoto K. Scintigraphic evaluation of myocardial uptake of ²⁰¹thallium and technetium ^{99m} pyrophosphate utilizing a rat model of chronic doxorubicin cardiotoxicity. *Eur J Nucl Med* 1991; 18: 332-338.
25. Piwnica-Warms D, Chiu M, Kronauge J. Detection of adriamycin cardiotoxicity in cultured chick heart cells with ^{99m}TcMIBI. *Cancer chemotherapy Pharmacol* 1993; 32(2): 386-391.

Correspondence:

Antonia Tzonevska, MD PhD
Department of Nuclear Medicine, SHATonc
1756 Sofia, Bulgaria
e-mail: dr.tzonevska@gmail.com