

Case report

Cytostatic treatment with irinotecan liposomal in a patient with advanced pancreatic adenocarcinoma

Przemysław Będkowski^{1,2}, Wojciech Rogowski^{1,3}

¹ Department of Clinical Oncology, Chemotherapy, Clinical Research, Provincial Specialist Hospital in Słupsk

² Department of Daily Chemotherapy, Provincial Hospital in Koszalin

³ Pomeranian Academy in Słupsk

For non-commercial use only

Correspondence:

Wojciech Rogowski
Department of Clinical Oncology,
Chemotherapy, Clinical Research,
Provincial Specialist Hospital in Słupsk
76-200 Słupsk, Hubalczyków 1
e-mail: wojciech.rogowski.apple@gmail.com

Received:

12.03.2021

Accepted:

28.05.2021

DOI: 10.24292/01.OR.122280621

Copyright © Medical Education.

All rights reserved.

ABSTRACT

Pancreatic cancer is one of the most common malignant neoplasms with a short survival time and a low cure rate. This neoplasm progresses quickly, it is often diagnosed in the advanced stage, which means that systemic treatment regimens are not sufficiently effective. A case of 65-year-old patient with metastatic pancreatic cancer who underwent sequential chemotherapy with the use of liposomal irinotecan was presented.

Key words: pancreatic adenocarcinoma, liposomal irinotecan, chemotherapy

INTRODUCTION

In Poland, malignant neoplasms of the pancreas constitute approx. 2% of cases in both sexes, and at the same time they are responsible for approx. 4.4% of cancer deaths in men and 5.4% in women. The number of deaths due to pancreatic cancer in our country amounts to approx. 5 thousand annually [1]. The five-year survival rate among pancreatic cancer patients during the first decade of the 21st century remained constant at no more than 10% for both sexes.

The effects of the current systemic treatment, especially at the stage of metastatic cancer, are insufficient. Therefore, attempts are made to introduce further therapy regimens aimed at extending overall survival and progression-free time, as well as alleviating its symptoms. New drugs include irinotecan liposomal, which is used as a further line treatment of advanced pancreatic cancer that has progressed after based on gemcitabine chemotherapy. The effectiveness of the drug in extending overall survival and progression-free time was confirmed in the NAPOLI-1 registration study [2].

CASE REPORT

A 65-year-old patient with hyperthyroidism due to Graves' disease, in the euthyrosis stage, treated because of depression with mianserin and valproic acid since 2010, was referred the Oncology Department in Slupsk in March 2020 for diagnosis of weight loss of more than 10%, lack of appetite and pain in the abdomen and epigastrium. The patient reported dyspnea that periodically worsened with little effort.

The physical examination revealed: general condition fairly good, WHO performance level 1/2, pain intensity 2/10 on the numerical rating scale (NRS), heart rate 90/min, clear tones, right-sided normal breath sound, and left-sided breath sound diminished. Dyspnea was also found to be 2/3 on the MRC (Medical Research Council) scale – after walking more than 100 meters or walking on flat ground for a few minutes, the patient had to stop in order to take breath. The abdomen was soft, slightly painful on palpation in the abdominal region, negative peritoneal symptoms. The parenchymal organs turned out to be undetectable. There were no swelling of the lower limbs.

The patient was urgently referred for a computed tomography (CT) examination of the chest, abdominal cavity and pelvis. It showed a hypodense lesion within the tail of the pancreas with an infiltration of the splenic artery and numerous nodules of both lungs, up to 20 mm in the right lung and up to 25 mm in

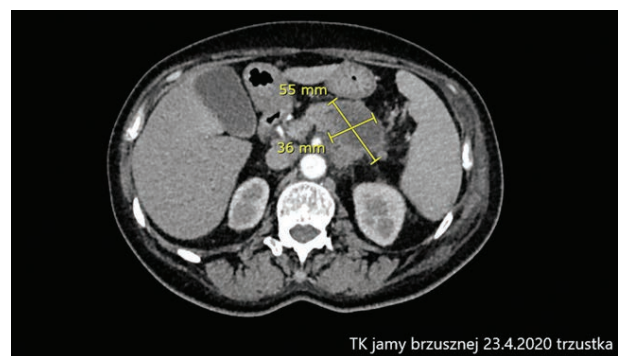
the left lung, corresponding to metastatic lesions. There was also a large amount of fluid with a layer thickness of up to 100 mm in the left pleural cavity.

Due to the lack of invasive diagnostics in the local hospital (change in the pancreas tail beyond the biopsy range), the patient was referred to the Thoracic Surgery Department of the University Clinical Center in Gdansk. The patient was there from March 31st to April 4th, 2020. During this time, videothoracoscopy, decompression of the left pleural cavity and pleurodesis were performed. On the basis of samples from the parietal pleura of the left pleural cavity, on April 10th, 2020, an infiltrating tubular malignant tumor and forming papillary structures was diagnosed, covered with cells with the phenotype CK7 +, CK20 +, CDX-2 +, p53 +/-, SMAD4-, WT1-, podoplanin-, calretinin-, CK5/6, TTF-1-, PAX-8-. The diagnosis of metastasis of pancreatic adenocarcinoma to the parietal pleura of the left pleural cavity was established.

On April 21st, 2020, the patient was admitted to the Oncology Department at the Provincial Specialist Hospital in Slupsk in order to start systemic treatment. On admission, the condition was comparable to the condition in the study from March 2020. The WHO performance status grade was rated at 1/2. Additionally, the patient reported increased pain in the abdominal cavity, rated 4/10 on the NRS scale. Therefore, oxycodone hydrochloride was added to the analgesic therapy at a dose of 2 × 10 mg/24 h, a significant reduction in pain intensity was achieved (NRS 1/10). On April 23rd, 2020, a control CT of the chest, abdomen and pelvis was performed. The following lesions were selected for monitoring: primary lesion in the tail of the pancreas size 55 × 36 mm, metastatic lesion in the right lung with a diameter of 20 mm, metastatic lesion in the left lung (25 mm), paratracheal lymph nodes 8–10 mm and pleural cavity fluid left with a layer width of up to 80 mm (fig. 1).

FIGURE 1.

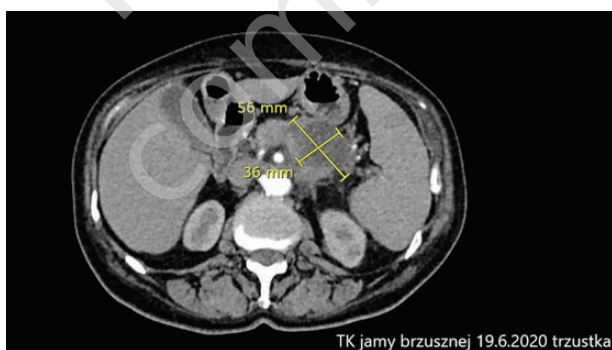
Abdominal computed tomography on April 23rd, 2020: primary lesion in the tail of the pancreas (size 55 × 36 mm).



Due to the general condition that made it impossible to administer the first-line chemotherapy with the FOLFIRINOX regimen [3], the patient was qualified for treatment according to the NFZ (Narodowy Fundusz Zdrowia, ang. National Health Fund) drug program: Treatment of patients with metastatic pancreatic adenocarcinoma with nab-paclitaxel. After confirming that it meets the inclusion criteria and does not meet the exclusion criteria, on April 30th, 2020, the first cycle of gemcitabine with nab-paclitaxel was administered at the full dose, consistent with the product characteristics [4].

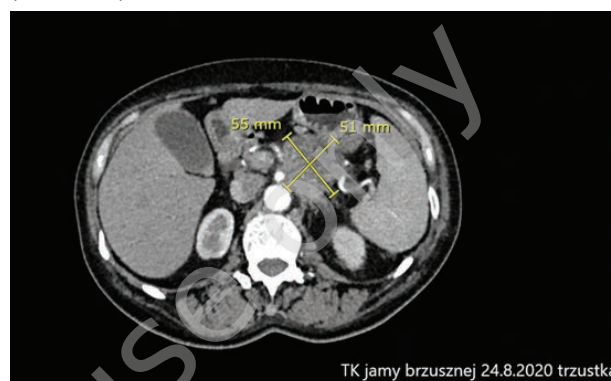
The treatment course of the patient was complicated by grade III neutropenia, which was first diagnosed on the 15th day of the first treatment cycle. Therefore, the dose of gemcitabine and nab-paclitaxel was reduced by one level. The second cycle was restarted at full dose. Due to grade III neutropenia, which was found again on the 15th day of the second cycle, a decision was made to continuously reduce the dose by one dose level (nab-paclitaxel to 100 mg/m², gemcitabine to 800 mg/m²) and to apply secondary prophylaxis of febrile neutropenia. On June 19th, 2020, after two cycles of chemotherapy, a control CT of the chest, abdominal cavity and pelvis was performed, in which the stabilization of the neoplastic process was described (fig. 2).

FIGURE 2.
Computed tomography of the abdominal cavity from June 19th, 2020.



After two consecutive cycles of 1st line chemotherapy at a reduced dose, a CT scan was performed on August 24th, 2020, which showed disease progression. The pancreatic lesion selected for monitoring was of a size similar to the initial one (55 × 51 mm), additionally, an encysted fluid appeared near the apex of the left lung (fig. 3). The lung metastases did not progress. A previously absent embolus appeared in the right upper lobe artery. The patient reported deterioration of exercise tolerance, increasing weakness and further weight loss. The necessity to visit the oncology department every week during the SARS-CoV-2 pandemic has also become a problem for the patient.

FIGURE 3.
Computed tomography of the abdominal cavity from August 24th, 2020. Monitored change in the pancreas it is similar to its original size (55 × 51 mm).



Due to the progression, chemotherapy was terminated in the NFZ/NHF drug program. A decision was made to use the next line of systemic therapy. The patient was qualified for treatment with irinotecan liposomal in combination with leucovorin and 5-fluorouracil. Before starting therapy, a vascular port was implanted. Low-molecular-weight heparin (enoxaparin) at a dose of 1.5 mg/kg was introduced prophylactically, initially for 4 weeks, then at a dose of 1 mg/kg permanently.

On September 23rd, 2020, the first cycle of chemotherapy was administered with irinotecan liposomal at a dose of 80 mg/m² and 5-fluorouracil at a dose of 1800 mg/m² and 300 mg/m² of folinic acid. The doses of 5-fluorouracil and leucovorin were reduced to 75% due to pre-existing neutropenia. Until now, the patient has received 11 two-week treatment cycles.

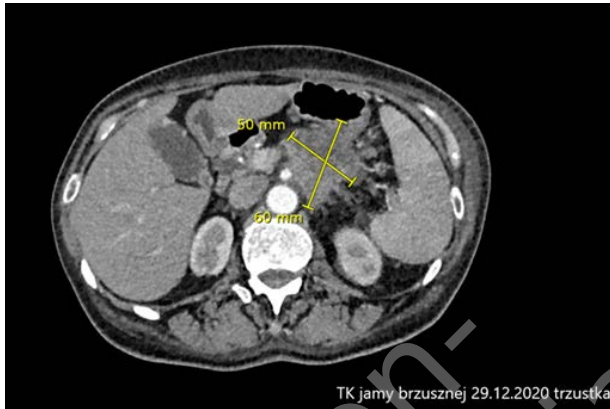
Since neutropenia was still present despite the use of growth factors, the duration of administration of short-acting growth factor was prolonged. The patient remained weakened to the G1 stage, which was attributed to both treatment toxicity and the underlying disease.

On December 29th, 2020, a control CT scan was performed, which showed stabilization of the disease, the lesion in the pancreatic tail remained non-enlarged (60 × 50 mm), as well as metastatic lesions in the lungs (fig. 4). There was no fluid near the top of the left lung. The liver still showed no metastatic features. There were also no signs of pulmonary embolism. The results met the conditions for stabilization according to RECIST criteria. There were also no significant deviations from the norm in laboratory tests. The patient continues therapy with liposomal irinotecan in combination with 5-fluorouracil and leucovorin. The treatment tolerance is still good, the performance status of the patient is

WHO 1/2, no hematological complications, pain in the abdominal cavity is currently minor and acceptable. The next radiological evaluation is scheduled for April 2021.

FIGURE 4.

Computed tomography of the abdominal cavity from December 29th, 2020.



CONCLUSIONS

A good therapeutic effect was achieved in a patient treated for over 10 months for disseminated adenocarcinoma of the pancreas thanks to sequential therapy. The cytostatic treatment halted the progression of the disease, and the supportive treatment enabled the continuation of chemotherapy, reduced the symptoms of the disease and significantly improved the patient's quality of life.

It is worth noting that currently the patient's survival time is similar to that of patients treated with the most effective and also the most toxic chemotherapy regimen of disseminated pancreatic cancer – FOLFIRINOX [5].

References

1. Wojciechowska U, Didkowska J. Zachorowania i zgony na nowotwory złośliwe w Polsce. Krajowy Rejestr Nowotworów, Narodowy Instytut Onkologii im. Marii Skłodowskiej-Curie – Państwowy Instytut Badawczy. <http://onkologia.org.pl/raporty> (access: 1.02.2021).
2. Wang-Gillam A, Hubner RA, Siveke JT et al. NAPOLI-1 phase 3 study of liposomal irinotecan in metastatic pancreatic cancer: Final overall survival analysis and characteristics of long-term survivors. *Eur J Cancer*. 2019; 108: 78-87.
3. Taieb J, Abdallah R. How I treat pancreatic cancer. *ESMO Open*. 2020; 4(suppl 2): e000818. <http://doi.org/10.1136/esmoopen-2020-000818>.
4. Charakterystyka produktu leczniczego INN-Paklitaxel.
5. Conroy T, Desseigne F, Ychou M et al. FOLFIRINOX versus Gemcitabine for Metastatic Pancreatic Cancer. *N Engl J Med*. 2011; 364: 1817-25. <http://doi.org/10.1056/NEJMoa1011923>.

Authors' contributions:

All authors contributed equally to the article.

Conflict of interests:

The authors declare no conflict of interest regarding the publication of this article.

Financial support:

The funders had no role in study design, data collection and analysis, decision to publish, or preparation of the manuscript.

Ethics:

The authors had full access to the data and take full responsibility for its integrity.

All authors have read and agreed with the content of the manuscript as written.

The paper complies with the Helsinki Declaration, EU Directives and harmonized requirements for biomedical journals.