

Case report

Dealing with hypodysfibrinogenemia during pregnancy with a successful outcome

Zuzanna Faflik¹, Michał Witkowski², Magdalena Witkowska³, Piotr Smolewski³,
Tadeusz Robak⁴

¹ Students' Scientific Circle at the Department of Hematology of the Medical University of Lodz, Poland

² Department of Hematology, Copernicus Memorial Hospital, Lodz, Poland

³ Department of Experimental Hematology, Medical University of Lodz, Poland

⁴ Hematology Clinic, Medical University in Lodz, Poland

ABSTRACT

Background: Fibrinogen is a protein playing pleiotropic role in human body. It is engaged in maintaining hemostasis. Congenital fibrinogen disorders comprise quantitative and qualitative fibrinogen anomalies. The symptoms range from bleeding, thrombosis to asymptomatic at all what is the most common case. Hypodysfibrinogenemia with lower level of fibrinogen of reduced activity, is the least common of all congenital fibrinogen disorders.

Case report: A 31-year-old woman was reported at the 21 weeks of gestation, suffered from genital tract bleeding and there was a history of stillbirth. Clinical examination with no pathology, however laboratory tests revealed coagulation abnormalities due to prolonged thrombin test, decreased protein S and lower fibrinogen level (70 mg/dl). Autoimmune diseases were excluded and the diagnosis was widened with rotational thromboelastometry and genetic test for hypodysfibrinogenemia. The patient was treated with fibrinogen substitution and prophylactic dose of heparin throughout pregnancy and 2 weeks following labour. At 39 week of gestation Caesarean section was done, with no complications.

Results: Genetic test revealed heterozygous mutation in fibrinogen gamma gene confirming hypodysfibrinogenemia. Due to bleeding manifestation in this patient of congenital fibrinogen disorders, fibrinogen substitution was implemented with heparin as a paranticoagulant prophylaxis, what turned out to be successful and enabled the patient to maintain the pregnancy.

Conclusions: As hypodysfibrinogenemia symptoms are diverse the management is difficult and each patient's therapy should be planned separately. Pregnancy may be the first time when congenital fibrinogen disorders reveal and it is especially challenging to prevent from obstetrical complications.

Key words: hypodysfibrinogenemia, pregnancy, fibrynogen, substitution

Correspondence:

Michał Witkowski
Department of Hematology, Copernicus
Memorial Hospital, Lodz, Poland
93-513 Łódź, ul. Ciołkowskiego 2
phone: +48 42 689 51 91
e-mail: michalwitkowski13@gmail.com

Received:

15.08.2021

Accepted:

8.11.2021

DOI: 10.24292/01.OR.124081121

Copyright © Medical Education.

All rights reserved.

INTRODUCTION

Fibrinogen is a protein that is engaged in several physiological and pathophysiological processes in human body such as inflammation, tissue injury and primarily it is necessary to form a blood clot. Inherited disorders of fibrinogen are classified into qualitative and quantitative disorders [1]. Congenital fibrinogen disorders (CFD) consist of two types of fibrinogen dysfunctions: type I quantitative abnormalities include complete absence of fibrinogen in plasma – afibrinogenemia or partial lack of this protein – hypofibrinogenemia. Type II comprises qualitative disorders which are associated with dysfibrinogenemia which means there is lower concentration of functional fibrinogen or hypodysfibrinogenemia – decreased level of low functional activity fibrinogen in circulating blood CFD are mostly an autosomal dominant disorder due to the heterozygous missense mutation, rather than homozygous, they may appear in all of the genes encoding fibrinogen chains – FGA, FGB and FGG [2, 3]. The most common type are substitutions in the N-terminal region of α chain or in the γ chain the C-terminal part [2]. Novel fibrinogen mutations that are detected are named as the cities where the disorder was discovered, presented in the table 1 [2, 4, 5]. The manifestation of qualitative fibrinogen disorders in majority of cases is limited and they are diagnosed accidentally, however other patients suffer from bleeding complications or even paradoxically thrombotic events [1, 4, 6]. As stated above diagnosis of dysfibrinogenemia is often made incidentally due to clinical manifestation of the disease such as bleeding, embolism or pregnancy complications, but at the laboratory tests they present prolonged prothrombin time (PT) and activated partial thromboplastin time (aPTT). When congenital dysfibrinogenemia is being suspected other test that could be done to confirm the diagnosis are: level of functional fibrinogen with Clauss method, PT-derived, level of antigenic fibrinogen as well as thrombin time (TT) and reptilase time (RT). The following steps with confirmed dysfibrinogenemia consist of genotyping [2]. What should be mentioned is that fibrinogen

is essential for maternal-fetal vascular development, protecting from bleeding during developing of vessels and implantation [7]. During pregnancy fibrinogen defects, both qualitative and quantitative, may result in miscarriage, placenta abruption, postpartum haemorrhage or thromboses [6].

CASE REPORT

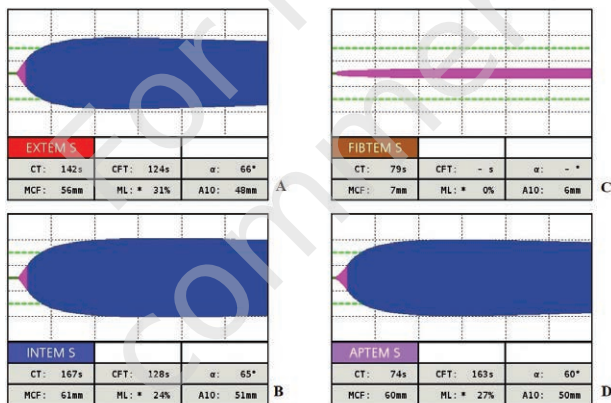
A 31-year-old nulliparous woman was referred at 21 weeks of gestation for diagnosis of coagulation disorder. According to the anamnesis there was a stillbirth at 29 weeks of gestation 2 years before, biopsy of the placenta revealed microthrombosis of placenta villi. As for the symptoms the patient only reported genital tract bleeding with no other blood loss or episodes of thrombosis. The patient also mentioned undergoing *Hepatitis* type C with a suitable treatment afterwards. For the day of the referral the patient was only treated with dydrogesterone and oral iron supplements. As for the physical examination no abnormalities were detected. However, laboratory tests showed lower fibrinogen level (70 mg/dl), whereas TT was prolonged (37 seconds), protein S was decreased (51%). Nevertheless, APTT and PT were in normal range. Other laboratory tests associated with inherited thrombophilia including antithrombin, protein C, prothrombin gene mutation, factor V Leiden were negative. Moreover, VWF ristocetin cofactor assay, thromboelastometric ROTEM testing evidenced abnormal coagulation time (142 seconds) in ex-TEM and decreased MCF (7 mm) in fib-TEM. Antibodies levels was also tested to exclude autoimmune diseases, but all of them were within normal range. A Doppler ultrasound of pelvic vessels was carried out but no significant abnormality was detected. At the time due to the examinations the suspicion of hypodysfibrinogenemia was made, as the genetic test was in progress. The patient was treated with fibrinogen substitution at the dose of 2 g per week also a prophylactic dose 40 mg per day of low-molecular-weight heparin.

Table 1. Chosen fibrinogen mutations named with the city of the discovery.

Name/origin	Gene	Mutation	Status
Canterbury	<i>FGA</i>	c.116T>A	heterozygous
Marseille	<i>FGA</i>	c.221T>C	heterozygous
Epsom	<i>FGB</i>	c.498_512del	heterozygous
Shanghai	<i>FGB</i>	c.969G>A	homozygous
Cracow	<i>FGG</i>	c.1052A>T	heterozygous
Detroit II	<i>FGG</i>	c.1015A>C	heterozygous

The therapy was to be indicated once a week for the lasting time of pregnancy, additional dose just before labour and continued for 2 weeks postpartum. At the 39 week of gestation Caesarean section was performed with no complications. A week after the labour patient reported for the follow up. As for the laboratory tests activated partial thrombin test (36,8 seconds) and fibrinogen (43 g/dl) were beneath the normal range. However, the patient presented no signs of bleeding or thrombosis since the last examination. In addition PCR and Sanger proved that the patient is a heterozygous for hotspot mutation p.Arg301Cys in exon 8 of fibrinogen gamma gene which is the cause of dysfibrinogenemia.

Figure 1. Graphic representation of different parameters of rotational thromboelastography of the patient with hypodysfibrinogenemia. A. In EXTEM test the tissue factor is used to assess the extrinsic pathway. B. INTEM test with addition of ellagic acid measures intrinsic pathway. C. In FIBTEM cytochoalasin D blocks platelets function revealing fibrinogen activity. D. In APTEM test the use of aprotinin to stabilize the clot by inhibiting fibrinolysis.



DISCUSSION

Dysfibrinogenemia is an inherited qualitative fibrinogen disorder. During pregnancy there is a physiological increase in fibrinogen level and change in the clot structure [1]. The treatment is not clearly defined and it varies due to the range of symptoms of the disease. The management is even more complicated in pregnant women as the use of some oral anticoagulant drugs is limited [7]. Royal College of Obstetricians and Gynaecologists (RCOG) guidelines indicate treating asymptomatic pregnant women with prophylactic dose of low-molecule-weight heparin for 6 weeks. However, American College of Chest Physicians (ACCP) suggests that only women with personal history or family history of venous thromboembolic should be treated this way or alternatively sometimes with vitamin K antagonists with maintaining international normalized ratio within therapeutic range,

but remembering that VKAs used during pregnancy may be associated with the fetal warfarin syndrome. ACCP also classify two other groups – asymptomatic but no family history of venous thromboembolism and women with previous pregnancy complications, due to ACCP thromboprophylaxis is not recommended in those cases [8].

Yan et al. reported a patient at 35 weeks of gestation, first misdiagnosed with hypofibrinogenemia and treated with fibrinogen concentrate then diagnosed with dysfibrinogenemia. So far there are only few case reports on this presentation. Due to having successful previous pregnancy with no history of bleeding or thrombosis the experts decided not to treat her, the labour was induced at 39 weeks with no complications [9]. Patil et al. presents a case of a 37-year-old woman with a history of six miscarriages before 12 weeks of gestation, with no other symptoms of bleeding or thrombosis [10]. Due to elevated procoagulant microparticles levels, the patient was primarily treated with low-molecular-heparin aspirin 75 mg once a day in her following pregnancy, which revealed to be unsuccessful again as she there was a miscarriage and excessive bleeding at 11 week. Then the diagnosis of dysfibrinogenemia in this patient was made and it was confirmed by DNA sequencing. In this case anticoagulant therapy proved not to be successful [10]. However, hypodysfibrinogenemia is more complex condition as there is not only decreased level of fibrinogen, but also a change in structure, what makes it even harder to cope with [5]. Santoro et al. presented 31-year-old patient after uneventful pregnancy, who experienced a cerebral venous thrombosis manifested with a sudden diplopia, 30 days after the delivery [11]. The woman was diagnosed with hypodysfibrinogenemia and treated with warfarin. Due to the patient becoming pregnant, the therapy was switched to enoxaparin at a dose of 100 IU per kg once a day, the activity of antifactor Xa was in therapeutic range. Unfortunately at 18th of gestation the patient presented with vaginal bleeding causing anaemia due to the placenta abruption. Anticoagulant prophylaxis was stopped and the woman was treated with fibrinogen concentrate and red cells concentrate. At the 19th the pregnancy was terminated with a stillbirth [11].

In our patients there were no bleeding manifestation and, as the clinical manifestation of amongst the patients with hypodysfibrinogenemia may vary from bleeding to thrombosis there are no strict guidelines for treating those patients [4, 11]. Treatment for each patient should be planned personally taking into consideration one's personal and family history. It is also advised for the patients, even those diagnosed incidentally, to undergo regular clinical check-ups [2].

CONCLUSIONS

Hypodysfibrinogenemia is the least common among fibrinogen abnormalities [5]. Pregnancy is a demanding time for a woman leading to imbalance in hemostasis and sometimes is the first time when coagulation disorder reveals [6, 10]. Proper treatment of fibrinogen disorders may prevent serious complications

for gravida such as miscarriage, thrombosis or haemorrhage [6, 7]. The time of pregnancy is specially challenging with limited choice of drugs that can be administered. To conclude, each patient should be taken into account individually regarding the symptoms, patient's past and her family history.

References

1. Castaman G, Giacomelli SH, Biasoli C et al. Risk of bleeding and thrombosis in inherited qualitative fibrinogen disorders. *Eur J Haematol.* 2019; 103: 379-84. <https://doi.org/10.1111/ejh.13296>.
2. Casini A, Neerman-Arbez M, Ariens RA et al. Dysfibrinogenemia: From molecular anomalies to clinical manifestations and management. *J Thromb Haemost.* 2015; 13: 909-19. <http://doi.org/10.1111/jth.12916>.
3. John MJ, Byreddy P, Modak K et al. Congenital Fibrinogen Deficiency in India and Role of Human Fibrinogen Concentrate. *Acta Haematol.* 2021; 1-8. <http://doi.org/10.1159/000516339>.
4. Undas A, Casini A. Congenital structural and functional fibrinogen disorders: a primer for internists. 913-20. <http://doi.org/10.20452/pamw.15082>.
5. Casini A, Brungs T, Lavenu-Bombled C et al. Genetics, diagnosis and clinical features of congenital hypodysfibrinogenemia: a systematic literature review and report of a novel mutation. *J. Thromb. Haemost.* 2017; 15: 876-88. <http://doi.org/10.1111/jth.13655>.
6. Valiton V, Hugon-Rodin J, Fontana P et al. Obstetrical and postpartum complications in women with hereditary fibrinogen disorders: A systematic literature review. *Haemophilia.* 2019; 25: 747-54. <http://doi.org/10.1111/hae.13825>.
7. Zhou J, Xin L, Ding Q et al. Thromboelastography predicts risks of obstetric complication occurrence in (hypo)dysfibrinogenemia patients under non-pregnant state. *Clin Exp Pharmacol.* 2016; 43: 149-56. <http://doi.org/10.1111/1440-1681.12509>.
8. Ormesher L, Simcox L, Tower C et al. Management of inherited thrombophilia in pregnancy. *Women's Heal.* 2016; 12: 433-41. <http://doi.org/10.1177/1745505716653702>.
9. Yan J, Deng D, Cheng P et al. Management of dysfibrinogenemia in pregnancy: A case report. *J Clin Lab Anal.* 2018; 32. <http://doi.org/10.1002/jcla.22319>.
10. Patil R, Mukaddam A, Ghosh K et al. Management of pregnancy in dysfibrinogenemia cases: A dilemma. *Blood Coagul Fibrinolysis.* 2017; 28: 91-3. <http://doi.org/10.1097/MBC.0000000000000514>.
11. Santoro R, Iannaccaro P, Sottilotta G. Congenital hypodysfibrinogenemia and abruptio placentae in a woman with history of cerebral thrombosis. *Acta Obstet Gynecol Scand.* 2007; 86: 247-8. <http://doi.org/10.1080/00016340600608477>.

Conflict of interests:

The authors have disclosed no conflicts of interest.

Financial support:

This research has not received any specific grant from public funding agencies, commercial or non-profit.

Ethics:

The authors had full access to the data and take full responsibility for its integrity.

All authors have read and agreed with the content of the manuscript as written.

The paper complies with the Helsinki Declaration, EU Directives and harmonized requirements for biomedical journals.